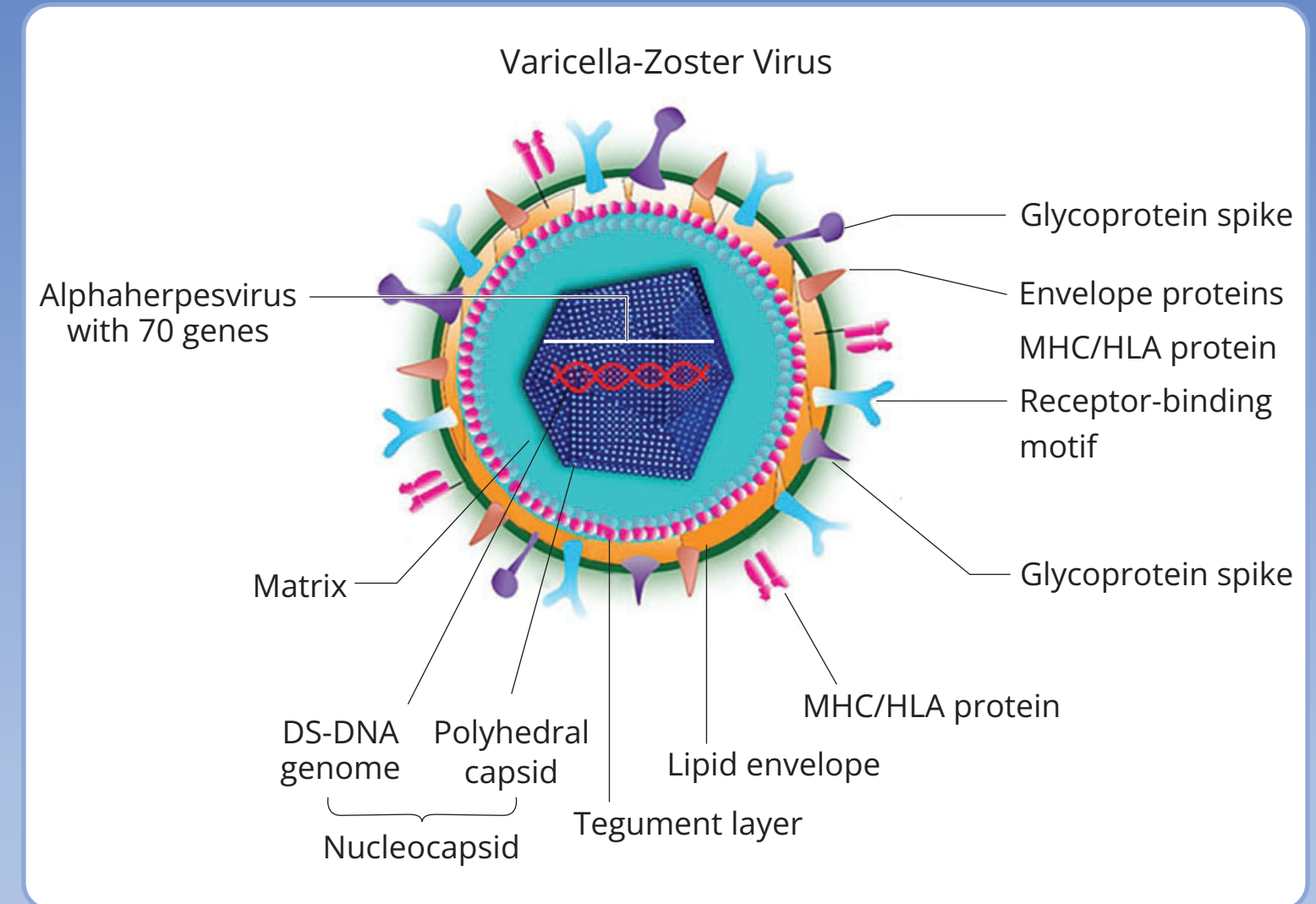


# newborn


Official Journal of the Global Newborn Society



### Other highlights:


Gastroschisis: Anatomic Defects, Etiopathogenesis, Treatment, and Prognosis

Use of Fresh Frozen Plasma in Newborn Infants



Also available online at

<https://www.globalnewbornsociety.org/our-scientific-journal-newborn>



## Global Newborn Society

**Each time we lose an infant, we lose an entire life and its potential!**

*Newborn* is the official journal of the [Global Newborn Society \(GNS\)](#), a globally-active, non-profit organization that is registered as a 501(c)(3) non-profit formation in the United States and is currently being listed as an analogous charity in many other nations. The aim is to enhance research in newborn medicine, understand epidemiology (risk-factors) of disease, train healthcare workers, and promote social engagement. The GNS was needed because despite all improvements in medical care, infants remain a high-risk patient population with mortality rates similar to 60-year-olds. We need to remind ourselves that *Every Baby Counts*, and that *Each Time We Lose an Infant, We Lose an Entire Life and its Potential*.

Our logo above, a hand-drawn painting, graphically summarizes our thought-process. There is a lovable little young infant exuding innocent, genuine happiness. The curly hair, shape of the eyes, long eye-lashes, and the absence of skin color emphasize that infants need care all over the world, irrespective of ethnicity, race, and gender. On the bib, the yellow background reflects happiness, hope, and spontaneity; the globe symbolizes well-coordinated, world-wide efforts. The age-related vulnerability of an infant, with all the limitations in verbal expression, is seen in being alone in the boat.

The unexpressed loneliness that many infants endure is seen in the rough waters and the surrounding large, featureless sky. However, the shades of blue indicate that the hope of peace and tranquility is not completely lost. The acronym letters, GNS, on the starboard are made of casted metal and are pillars of strength. However, the angular rough edges need continued polishing to ascertain adequacy and progress. The red color of the boat symbolizes our affection. The expression "*Every Baby Counts*" seen on the boat's draft below the waterline indicates our commitment to philanthropy, and if needed, to altruism that does not always need to be visible. The shadow behind the picture shows that it has been glued on a solid wall, one built out of our adoption and commitment.

## ***Design of the Journal Cover***

The blue color on the journal cover was a careful choice. Blue is the color of flowing water, and symbolizes the abnormalities of blood vascular flow that are seen in many neonatal illnesses. There is a gradual transition in the shades of blue from the top of the cover downwards. The deeper shades of blue on the top emphasize the depth, expertise, and stability, which the renowned authors bring. Light blue is associated with health, healing, tranquility, understanding, and softness, which their studies bring. The small letter “n” in the title of the journal, *newborn*, was chosen to emphasize the small size of a lovable little newborn baby. The issue editors chose three articles to be specifically highlighted; the picture on top and the two titles below reflects an order suggested by them.

## ***Instructions to Authors***

The journal welcomes original articles and review articles. We also welcome consensus statements, guidelines, trials methodology, and core outcomes relevant to fetuses/young infants in the first 1000 days. A detailed set of instructions to authors can be seen online at <https://www.globalnewbornsociety.org/intructions-for-authors>. The manuscripts can be submitted via the [online manuscript submission system](#).

## ***Issue Information***

Volume 1, Issue 3; July-September 2022

ISSN: 2769-514X

Copyrights: GNS, LLC.

Published: GNS, LLC; 6114 Lily Garden, Clarksville, MD, USA; Ph +1 708 910 8729

Printed: Jaypee Brothers Medical Publishers

4838/24, Ansari Road, Darya Ganj, Delhi - 110 002

Phone: +91 11 4357 4357, Fax: +91 11 4357 4314



# Contents



## EDITORIAL

- Coordinated Multispecialty Care: A Need for Critically Ill Newborn Infants** ..... iv-v  
*Akhil Maheshwari, Rachana Singh, Mario Motta*

## REVIEW ARTICLES

- Neonatal Anemia**..... 263  
*Neha Chaudhary, Romal Jassar, Rachana Singh*
- Use of Fresh-frozen Plasma in Newborn Infants** .....271  
*Manvi Tyagi, Akhil Maheshwari, Brunetta Guaragni, Mario Motta*
- Congenital and Perinatal Varicella Infections**.....278  
*Srijan Singh, Akash Sharma, Mohd Mozibur Rahman, Gangajal Kasniya, Akhil Maheshwari, Suresh Boppana*
- Gastroschisis: Anatomic defects, Etiopathogenesis, Treatment, and Prognosis** .....287  
*Roya Huseynova Arif, Latifa Bin Mahmoud, Abdel Basit El Syed Ali, Adli Abdelrahim, Oktay Huseynov Ilham, Fazal Nouman Wahid, Mohd Mozibur Rahman, Nalinikanta Panigrahy, Devendra Panwar, Gangajal Kasniya, Kamlesh Jha, Akhil Maheshwari*
- Enteroviral Infections in Infants** .....297  
*Srijan Singh, Sushant Satish Mane, Gangajal Kasniya, Sofia Cartaya, Mohd Mujibur Rahman, Akhil Maheshwari, Mario Motta, Pradeep Dudeja*
- Advancement of Enteral Feeding in Very-low-birth-weight Infants: Global Issues and Challenges**.....306  
*Krystle Perez, Gregory Charles Valentine, Sushma Nangia, Douglas G Burrin, Akhil Maheshwari, Mahlet Abayneh, Redeat Workneh, Maggie Jerome, N Alejandro Dinerstein, Ariel Salas*
- Neonatal Intensive Care Unit Care of Newborn Infants born to Mothers with Suspected or Confirmed COVID-19 Infection** .....314  
*Yahya Ethawi, Mona Khalaf, Haider Nadhim, Fares Chedid, Yaser Al Sayed, Rola AlAzi, Ahmad Mohd Haider Al Amad, Suad Hannawi, Mahmoud Hamouri, Majeed Jawad, Abdulrahman Al Nemri, Alok Sharma, Yusra Swaidat, Rola Al Thawbti*

## CLINICOPATHOLOGICAL CONFERENCE REPORT

- Hypoxic-Ischemic Encephalopathy: To Cool, or Not to Cool, That is the Question**.....320  
*Shabih Manzar, Ramachandra Bhat, Sheila Asghar, Rosario Riel-Romero, Nitin Walyat, Octavio Arevalo-Espejo, Maroun Mhanna*

**Coordinated Multispecialty Care: A Need for Critically Ill Newborn Infants**

Neonatal intensive care requires coordinated multispecialty management.<sup>1,2</sup> Many conditions have a prenatal onset and the initiation of treatment in the early neonatal period can make a difference.<sup>3,4</sup> Neonatologists can use important help and guidance from other specialists; this issue highlights the role of pediatric surgeons, infectious disease specialists, hematologists, and experts in the blood banks.<sup>5-8</sup> However, the list of specialists does not stop here. Experts from other subdivisions are frequently needed. The role of technologists for continuous monitoring is also important. Early initiation of care before many infections get established or the congenital anomalies get complicated can make a difference.<sup>9</sup>

Early diagnosis is a key determinant of outcomes in many pre- and early neonatal infections.<sup>10</sup> However, we routinely screen for only a small list of maternal infections.<sup>11</sup> Many of these infections may not so uncommon in the community, but certain genetic and epigenetic predisposing factors can increase the risk of transmission to the fetus.<sup>11,12</sup> Many viral genotypes are also more likely to cause severe disease in young infants.<sup>13</sup> The overall aim of the journal *Newborn* is to highlight problems that a baby might develop *in utero*, the perinatal period, following birth, and the implications of these abnormalities during the first 1000 days after birth. In this 3<sup>rd</sup> issue of our journal, we seek to draw the readers’ attention to the importance of coordinated multispecialty care in NICUs to improve outcomes and establishing a close relationship with the families to improve outcomes.<sup>14</sup>

This issue presents a set of articles that represent each of these subsets. Despite all efforts to standardize the training of personnel who provide care to at-risk newborn infants, birth asphyxia and hypoxic-ischemic encephalopathy (HIE) remain issues of concern.<sup>15</sup> Multiple studies have shown the importance of therapeutic hypothermia (TH) as a treatment modality, but some uncertainty remains.<sup>16,17</sup> Manzar *et al.*<sup>18</sup> describe a full-term infant with low Apgar scores who had a slightly delayed onset of HIE. The paper presents the clinical and diagnostic dilemmas that are typically associated with decisions needed for treatment with TH.

Ethawi and coworkers<sup>19</sup> have reviewed the care of infants born to mothers who are suspected/known to have coronavirus disease-19 (COVID-19). Even though the incidence of COVID-19 and associated mortality seems to be finally decreasing all over the world, concerns remain. Singh *et al.* have contributed two separate articles<sup>20,21</sup> focused on neonatal infections with entero- and varicella-zoster viruses in which they describe known properties of these viruses, the clinical manifestations, and currently available methods of detection, treatment, and assessment of prognosis.

In another study, Arif and her colleagues<sup>22</sup> assembled a global team to review gastroschisis, a congenital defect in the abdominal wall that is typically located to the right of the umbilicus. The intestines, and sometimes parts of the liver and the stomach, may protrude into the amniotic space. Unlike in omphaloceles, these visceral organs do not have a covering sac and are directly exposed to the amniotic fluid. The organs show variable degrees of inflammatory changes and scarring. They have summarized currently available information on the anatomical changes in the intestine that was directly exposed to the amniotic fluid *in utero*, the etiopathogenesis, treatment, and prognosis.

Chaudhary *et al.*<sup>23</sup> have summarized the pathophysiology, etiologies, clinical management, and the opportunities in research in the field of neonatal anemia. Tyagi *et al.*<sup>24</sup> have reviewed the use of fresh-frozen plasma (FFP) in neonates. Nearly 10% of premature and critically ill infants receive FFP transfusions to reduce their high risk of bleeding. However, we have only limited data to identify relevant clinical predictors of bleeding and to evaluate the efficacy of FFP administration. Consequently, there remains a lack of consensus on the optimal use of FFP with most transfusions given to non-bleeding infants. This review presents current evidence focused on the use of FFP in neonatology, and then proposes best practice recommendations for the safety of neonates receiving FFP.

Finally, an international team led by Perez *et al.*<sup>25</sup> has discussed the global issues and challenges advancement of enteral feeding in premature/very-low-birth weight (VLBW) infants. In these infants, the initiation of enteral feedings is frequently delayed and the feeding volumes are advanced very slowly. Clinicians are often concerned that aggressive initiation and advancement of feedings in an immature gastrointestinal tract can result in feeding intolerance and increase the risk of spontaneous intestinal perforation and necrotizing enterocolitis. On the other hand, late initiation and ultra-cautious advancement of enteral feedings is associated with prolonged need for central venous access and increased risk of sepsis, which may increase neonatal mortality. The authors have described that many of the adverse events noted with early feedings are actually with infant formula and not mother’s own milk. Promoting early establishment of full enteral feeding, particularly when maternal or donor milk is available, can improve neonatal outcomes, particularly the incidence of central-line associated bacterial infections, lengths of hospital stay, and survival. This review highlights current evidence for maximizing enteral feeding strategies for VLBW infants in various settings.

**References**

1. Frize M, Yang L, Walker RC, et al. Conceptual framework of knowledge management for ethical decision-making support in neonatal intensive care. *IEEE Trans Inf Technol Biomed* 2005;9(2):205–215. doi:10.1109/titb.2005.847187
2. Barbosa VM. Teamwork in the neonatal intensive care unit. *Phys Occup Ther Pediatr* 2013;33(1):5–26. doi:10.3109/01942638.2012.729556
3. Boyd PA, Tonks AM, Rankin J, et al. Monitoring the prenatal detection of structural fetal congenital anomalies in England and Wales: register-based study. *J Med Screen* 2011;18(1):2–7. doi:10.1258/jms.2011.010139
4. Farrell PM, Engle MJ, Frantz ID, et al. Complications of pregnancy and fetal development. *Diabetes* 1982;31(Suppl 1 Pt 2):89–94. doi:10.2337/diab.31.1.s89
5. American Academy of Pediatrics Committee on Fetus and Newborn. Levels of neonatal care. *Pediatrics* 2012;130(3):587–597. doi:10.1542/peds.2012-1999



6. Reeves HM, Goodhue Meyer E, Harm SK, et al. Neonatal and pediatric blood bank practice in the United States: Results from the AABB pediatric transfusion medicine subsection survey. *Transfusion* 2021;61(8):2265-2276. doi:10.1111/trf.16520
7. Madaline T, Wadskier Montagne F, Eisenberg R, et al. Early Infectious Disease Consultation Is Associated With Lower Mortality in Patients With Severe Sepsis or Septic Shock Who Complete the 3-Hour Sepsis Treatment Bundle. *Open Forum Infect Dis* 2019;6(10):ofz408. doi:10.1093/ofid/ofz408
8. Ree IMC, Lopriore E. Updates in Neonatal Hematology: Causes, Risk Factors, and Management of Anemia and Thrombocytopenia. *Hematol Oncol Clin North Am* 2019;33(3):521-532. doi:10.1016/j.hoc.2019.01.013
9. Kumar S, O'Brien A. Recent developments in fetal medicine. *BMJ* 24 2004;328(7446):1002-1006. doi:10.1136/bmj.328.7446.1002
10. Sahu P, Raj Stanly EA, Simon Lewis LE, et al. Prediction modelling in the early detection of neonatal sepsis. *World J Pediatr* 2022;18(3):160-175. doi:10.1007/s12519-021-00505-1
11. Megli CJ, Coyne CB. Infections at the maternal-fetal interface: an overview of pathogenesis and defence. *Nat Rev Microbiol* 2022;20(2):67-82. doi:10.1038/s41579-021-00610-y
12. Jamieson SE, Cordell H, Petersen E, et al. Host genetic and epigenetic factors in toxoplasmosis. *Mem Inst Oswaldo Cruz* 2009;104(2):162-9. doi:10.1590/s0074-02762009000200006
13. Mavilia MG, Wu GY. Mechanisms and Prevention of Vertical Transmission in Chronic Viral Hepatitis. *J Clin Transl Hepatol* 28 2017;5(2):119-129. doi:10.14218/JCTH.2016.00067
14. Moon-Grady AJ, Baschat A, Cass D, et al. Fetal Treatment 2017: The Evolution of Fetal Therapy Centers - A Joint Opinion from the International Fetal Medicine and Surgical Society (IFMSS) and the North American Fetal Therapy Network (NAFTNet). *Fetal Diagn Ther* 2017;42(4):241-248. doi:10.1159/000475929
15. Zhang S, Li B, Zhang X, et al. Birth Asphyxia Is Associated With Increased Risk of Cerebral Palsy: A Meta-Analysis. *Front Neurol* 2020;11:704. doi:10.3389/fneur.2020.00704
16. Edwards AD, Azzopardi DV. Therapeutic hypothermia following perinatal asphyxia. *Arch Dis Child Fetal Neonatal Ed* 2006;91(2):F127-31. doi:10.1136/adc.2005.071787
17. Krishnan V, Kumar V, Shankaran S, et al. Rise and Fall of Therapeutic Hypothermia in Low-Resource Settings: Lessons from the HELIX Trial. *Indian J Pediatr* 23 2021;doi:10.1007/s12098-021-03861-y
18. Manzar S, Bhat R, Asghar S, et al. Hypoxic-Ischemic Encephalopathy: To Cool or Not to Cool That Is the Question. *Newborn* 2022;1(3):320-326. doi: 10.5005/jp-journals-11002-0037.
19. Ethawi Y, Khalaf M, Chedid F, et al. NICU care of newborn infants born to mothers with suspected or confirmed COVID19 infection. *Newborn* 2022;1(3):314-319. doi: 10.5005/jp-journals-11002-0042.
20. Singh S, Mane S, Kasniya G, et al. Enteroviral Infections in Infants. *Newborn* 2022;1(3):297-305. doi: 10.5005/jp-journals-11002-0036.
21. Singh S, Sharma A, Rahman MM, et al. Congenital and Perinatal Varicella Infections. *Newborn* 2022;1(3):278-286. doi: 10.5005/jp-journals-11002-0040.
22. Arif RH, Ilham OH, Mahmoud LB, et al. Gastroschisis: Anatomic Defects, Etiopathogenesis, Treatment, and Prognosis. *Newborn* 2022;1(3):287-296. doi: 10.5005/jp-journals-11002-0041.
23. Chaudhary N, Jassar R, Singh R. Neonatal Anemia. *Newborn* 2022;1(3):263-270. doi: 10.5005/jp-journals-11002-0027.
24. Morotti F, Candela GF, Martellosio G, et al. Automated Cell Counter-derived Neutrophil Cell Population Data by VCS Technology as a Marker of Early-onset Neonatal Sepsis. *Newborn* 2022;1(2):209-214. doi: 10.5005/jp-journals-11002-0030.
25. Perez K, Valentine G, Nangia S, et al. Advancement of enteral feeding in very low birth weight infants: global issues and challenges. *Newborn* 2022;1(3):306-313. doi:10.5005/jp-journals-11002-0038.

**Akhil Maheshwari MD, FAAP, FRCP Edin**  
**Rachana Singh MD, MS, FAAP**  
**Mario Motta MD**

# Neonatal Anemia

Neha Chaudhary<sup>1</sup>, Romal Jassar<sup>2</sup>, Rachana Singh<sup>3</sup> 

Received on: 04 May 2022; Accepted on: 27 May 2022; Published on: 07 October 2022

## ABSTRACT

Neonatal anemia is a public health problem of global concern and has significant associations with many short- and long-term morbidities. Many etiological factors ranging from perinatal physiologic transition, hematological maturation, illnesses, and iatrogenic reasons such as the phlebotomies necessary for laboratory evaluation may be involved, and there is a need for careful clinical decisions. In premature infants, the management of anemia also has to factor in the unique hematological transition seen during development, co-morbidities associated with preterm birth, the severity of illness severity, and all the iatrogenic factors. Untreated severe anemia is known to negatively impact long-term growth and neurodevelopment outcomes, making early diagnosis and treatment imperative. Additionally, there is a lack of consensus about the threshold and timing of packed red blood cell transfusions, and we need further consideration in view of various associated complications. Therefore, clinicians need to focus on preventable causes of anemia such as nutritional deficiencies, chronic illness, and excessive phlebotomy losses. In this article, we attempt to summarize the pathophysiology, etiologies, clinical management, and the opportunities in research in the field of neonatal anemia.

**Keywords:** Erythropoiesis, Hemoglobin, Hematocrit, Packed red blood cell transfusion.

*Newborn* (2022): 10.5005/jp-journals-11002-0027

## INTRODUCTION

Neonatal anemia is a major, globally recognized public health problem that is associated with short- and long-term morbidities.<sup>1-4</sup> It is defined as hemoglobin or hematocrit that is at least two standard deviations below the mean at a particular gestational and/or chronological age, secondary to a reduction in red blood cell (RBC) mass from multiple etiologies.<sup>4,5</sup> Preventable causes of neonatal anemia, especially in term newborns, continue to persist with even greater prevalence in developing and low socioeconomic countries.<sup>4,6,7</sup> The hematocrit can be low because of factors such as iron deficiency, malnutrition, and infections that might be affecting either the mother or the infant in the pre- and postnatal periods.<sup>8</sup> In preterm infants, anemia can become even more severe and complex depending on gestational age and the severity of concomitant illnesses. Up to 80% of extremely preterm and 50% of preterm infants born at <32 weeks' gestational age may need one or more packed red blood cell (pRBC) transfusions.<sup>9-11</sup> And the decision for pRBC transfusions in these infants becomes highly complicated not only because of the associated risks, but also because the thresholds may need to be adjusted vis-à-vis specific diagnoses, the overall severity of illness, and the expected physiological nadirs at those corrected gestational ages.<sup>12-16</sup> In this review, we have summarized the pathophysiology, etiologies, clinical management, and future opportunities in research in the field of neonatal anemia.

## Epidemiology and Etiology

The World Health Organization (WHO) has estimated that greater than one-third of the world's population is anemic. Approximately one-third of all women of reproductive age have low hemoglobin levels, and the rates of anemia are much higher rates in low socioeconomic populations with limited resources and healthcare infrastructure.<sup>4</sup> Current data suggest that severe maternal anemia during the first trimester of pregnancy is associated with a slight increase in preterm birth, and with a non-statistically significant trend towards increased low birth weights.<sup>17,18</sup> Although the exact

<sup>1-3</sup>Division of Newborn Medicine, Tufts Children's Hospital, Boston, Massachusetts, United States of America

**Corresponding Author:** Rachana Singh, Division of Newborn Medicine, Tufts Children's Hospital, Boston, Massachusetts, United States of America, Phone: +16176365322, e-mail: rsingh2@tuftsmedicalcenter.org

**How to cite this article:** Chaudhary N, Jassar R, Singh R. Neonatal Anemia. *Newborn* 2022;1(3):263-270.

**Source of support:** Nil

**Conflict of interest:** None

incidence of neonatal anemia is not well-determined, Lee et al. reported that of term infants born to adolescent people, 21% were anemic (Hb <13.0 gm/dL) and 25% had low iron stores (ferritin <76 µg/L).<sup>19</sup>

The etiology of anemia in a newborn is multifactorial, with prenatal factors like maternal malnutrition, iron-deficiency anemia, and infections being the most common.<sup>20</sup> Iron-deficiency anemia affects nearly half of all pregnant women in developing countries and can be easily corrected by supplementation leading to improved neonatal outcomes.<sup>21-23</sup> Each 10 mg increase in iron dose/day is associated with ~15 gm increase in birth weight and a 3% reduction in the risk of low birth weight, with a linear correlation between an increase in mean prenatal hemoglobin and birth weight (each 1 gm/L increase in Hb increased birth weight by 14 gm).<sup>24</sup> Iron supplementation is also important in lactating mothers who are exclusively breastfeeding, for these women and their infants. Chronic fetal hypoxia and placental insufficiency can reduce the transfer of iron stores to the fetus, especially in small-for-gestational age (SGA) infants and infants born to diabetic mothers.<sup>25</sup>

The severity of iron-deficiency anemia can worsen with many concomitant illnesses. Maternal parvo B19 infection, especially when it occurs in the first trimester, can increase the severity of fetal anemia leading to high-output cardiac failure.<sup>26</sup> Excessive

**Table 1:** Neonatal anemia classification based on red cell morphology

| <i>Microcytic anemia</i><br>MCV <90   | <i>Normocytic normochromic anemia</i><br>MCV 100–130   | <i>Macrocytic anemia</i><br>MCV >130  |
|---|--|---|
| Iron deficiency<br>Thalassemia<br>Sideroblastic anemia<br>Inborn errors of metabolism of iron metabolism<br>Chronic disease | Acute blood loss<br>Infections<br>Renal failure<br>Liver failure<br>Early phase of iron deficiency anemia<br>Hemolytic disorders | Vitamin B12 deficiency<br>Folic acid deficiency<br>Obstructive jaundice<br>Hypothyroidism<br>PNH<br>Down syndrome<br>Diamond blackfan anemia<br>Myelodysplastic syndromes |

**Table 2:** Neonatal anemia classification based on pathophysiology

| <i>Decreased production</i>  |  | <i>Increased destruction/loss</i>  |  |
|--|--|--|--|
| <i>Intrinsic</i>   | <i>Extrinsic</i>   | <i>Hemolytic</i>   | <i>Non-hemolytic</i>   |
| Anemia of prematurity<br>Chronic disease<br>Liver failure<br>Renal failure<br>Small for gestational age<br>Sideroblastic anemia<br>Drugs induced | Iron deficiency anemia<br>Vitamin B12 deficiency<br>Folic acid deficiency<br>Maternal malnutrition<br>Congenital/acquired infections<br>• Parvo B19<br>• CMV<br>• Herpes<br>• Others | Hemoglobinopathies<br>• Thalassemia's<br>• Sickle cell disease<br><br>Enzymopathies<br>• G-6-PD<br>• Pyruvate kinase deficiency<br><br>RBC membrane defects<br>• Hereditary spherocytosis<br>• Elliptocytosis<br>• Ovalocytosis<br><br>Disseminated intravascular coagulopathy<br>Infections (neonatal malaria)<br>Autoimmune hemolytic anemia<br>ABO/Rh incompatibility<br>Minor antigens incompatibility<br>Maternal ITP | Phlebotomy<br>NEC<br>Twin–twin transfusion<br>Peri-partum blood loss<br>• Placental abruption<br>• Placenta previa<br>• Precipitous delivery<br>• Obstetrical accidents involving the placenta<br>• Forceps delivery<br>• Cord avulsion<br>Birth trauma<br>• Subgaleal hemorrhage<br>cephalohematoma<br><br>Hemorrhagic disease of newborn |

peripartum maternal bleeding, possibly due to acute or chronic abruption, uterine rupture, feto-maternal hemorrhage, and/or cord accidents can lead to significant anemia at birth for both term and preterm infants. In developing nations, neonatal malaria is often seen in overcrowded areas.

**Subtypes of Neonatal Anemia**

Anemia can be classified based on red cell morphology as microcytic hypochromic, normocytic normochromic, and macrocytic (Table 1). Some of these morphological changes can be as seen in Figure 1. Red blood cell indices and hemoglobin values vary by gestation and chronological age such that Hb and RBC count increase throughout gestation, whereas, RBC size and Hb content decrease. Anemia can also be classified based on pathophysiology as secondary to increased blood loss, decreased production, or increased destruction of red cells (Table 2). Management of anemia in term infants appears more straightforward compared to the preterm population. Anemia and blood transfusion practices in the preterm infants have a variable impact on neurodevelopmental outcomes with short-term gains from a liberal transfusion approach but detrimental long-term effects on brain development.<sup>20</sup>

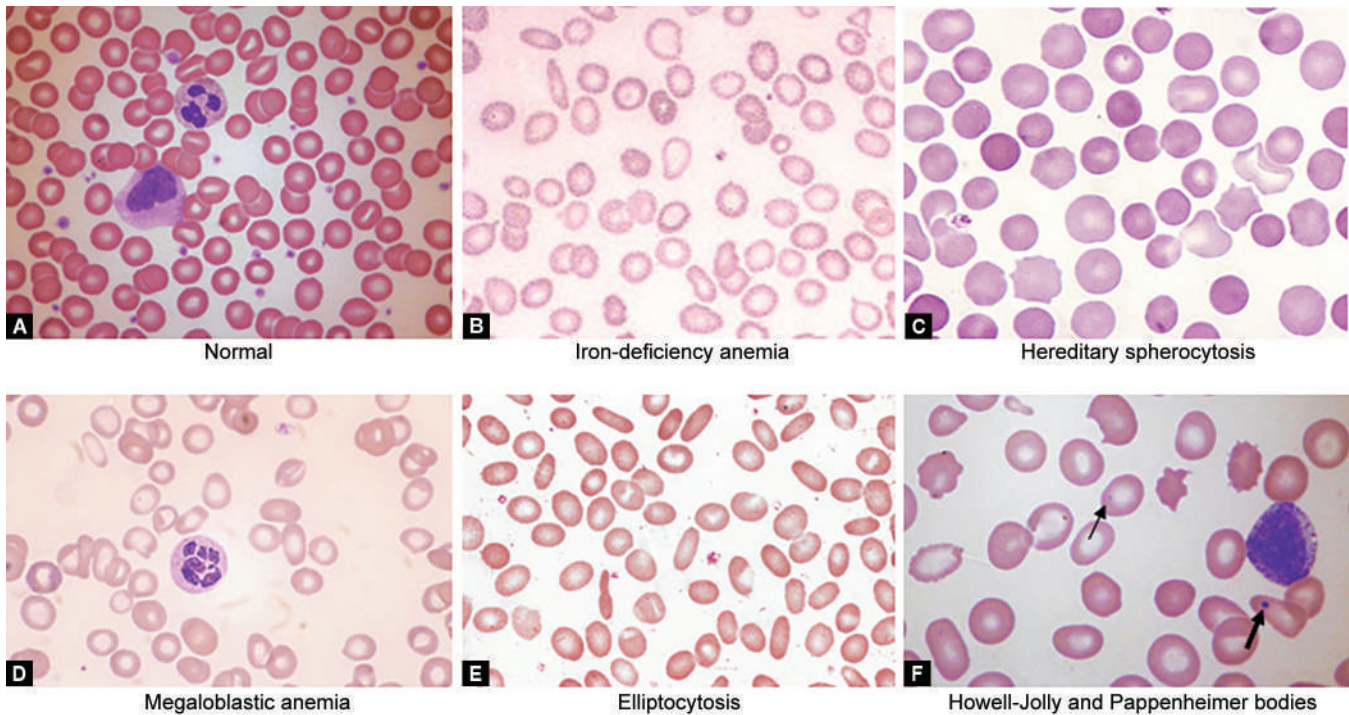
**Embryology and Pathophysiologic Changes of Anemia**

During the third trimester of pregnancy, there is a transition of hematopoiesis from fetal liver to bone marrow. Neonatal

hematopoiesis is directly proportional to fetal erythropoietin (EPO) levels, the production of which also transitions from the fetal liver prenatally to the neonatal renal system after birth.<sup>27,28</sup> This physiological transition leads to a temporary decline in EPO levels after birth, especially in preterm infants, leading to a hypo-regenerative state.<sup>29</sup> Additionally, there is a transition from a relatively hypoxic state *in utero* to a relatively hyperoxic state *ex-utero* that further suppresses hematopoiesis.<sup>30</sup> As the infant establishes a normal respiratory pattern, there is a rapid increase in oxygen in the blood that inhibits EPO production. However, this does not translate to increased oxygen delivery at the tissue level due to greater affinity of fetal hemoglobin (HbF) for oxygen.<sup>27</sup> Oxygen delivery via HbF is highly dependent on the blood pH, where in an acidic environment, HbF has 20% higher potential of releasing oxygen to peripheral tissues as seen *in-utero*. The fetus, therefore, thrives well in a relatively hypoxic state and lower pH, where HbF becomes an excellent vector for picking up oxygen at the placental level where the pH is high and delivering it to the fetal tissues. Lastly, the rapid expansion of blood volume after birth contributes to hemodilution and rapid degradation of red blood cells occurs due to the shorter life span of neonatal RBCs, both contributing to physiologic anemia of infancy.<sup>27</sup> The nadir of this physiologic anemia occurs at 10–12 weeks of life with hemoglobin rarely falling below 10 gm/dL in a healthy term infant<sup>29,31</sup> and well-tolerated with no need for a therapeutic intervention.<sup>32</sup> Physiologic







**Figs 1A to F:** Hematoxylin-eosin stained peripheral blood smears. Images obtained at 400x magnification. (A) Normal erythrocytes show a biconcave shape with central hypochromia. The level of staining in various cells is fairly uniform across the smear; (B) Hypochromic anemia. The most common cause iron deficiency. The RBCs show hypochromia, microcytosis, marked anisocytosis and mild poikilocytosis. Poikilocytosis is defined as altered shape in >10% of all RBCs (flat, elongated, teardrop-shaped, crescent-shaped, sickle-shaped, or having pointy or thorn-like projections); (C) Hereditary spherocytosis. Marked spherocytosis, some anisocytosis. Spherocytes show round contour. Larger cells have a faint blue tinge, indicating that the reticulocyte count is increased; (D) Megaloblastic anemia: shows macrocytes, oval macrocytes and a hypersegmented neutrophil. There are also hypochromic cells. Could be due to folic acid and/or vitamin B12 deficiency. Many patients also have concurrent iron deficiency; (E) Hereditary elliptocytosis. Many RBCs are elliptical, and others are oval; (F) Abnormal RBC staining. A Pappenheimer body (thin arrow; abnormal basophilic granules of iron) and a Howell-Jolly body (thick arrow; nuclear remnants) n arrow) are seen. These abnormalities can be seen occasionally in infants. This smear was obtained from a older child with autoimmune thrombocytopenic purpura who had undergone splenectomy; we included it in this review to highlight these abnormalities

anemia of infancy can be exaggerated by maternal factors like malnutrition, iron deficiency, infection, and hereditary hemolytic anemia.<sup>21,30</sup> For preterm infants, due to an immature hematopoietic system, the nadir may occur earlier at 6–8 weeks of life and can be more pronounced with hemoglobin reaching 8 gm/dL or even lower.<sup>29</sup> This is referred to as anemia of prematurity (AOP), often exaggerated due to secondary phlebotomy losses, and infants are commonly symptomatic.<sup>27,33</sup> With pRBC transfusion, there can be a reduction in the HbF from almost 92–43% in infants born EP.<sup>34</sup> HbA has reduced affinity to oxygen compared to HbF, which makes it challenging to use a strict Hb threshold for determining the need for pRBC transfusion in infants with variable Hb subtype concentrations and properties.

### Anemia in Preterm Infants

In the last two decades, there has been a practice shift from a liberal RBC transfusion strategy to a more restrictive strategy and tolerating lower levels of hemoglobin. The premature infants in need of transfusion (PINT) Trial recruited ELBW infants who were then assigned to either a high or low threshold hemoglobin transfusion threshold and studied for death or survival with comorbidity (retinopathy, bronchopulmonary dysplasia, or brain injury on cranial ultrasound).<sup>35</sup> The ETTNO trial conducted by Franz et al. that recruited preterm infants from 2011 to 2014 in

Europe analyzed death and disability after randomizing 1013 subjects in liberal vs restrictive red blood cell transfusion strategy. Infants were followed up till 24 months corrected age. Recently the TOP trial recruited 1824 preterm infants from 2012 to 2017, randomized to two transfusion strategy groups, and reported death or neurodevelopment impairment in each group till 26 months corrected age. All three trials favored a restrictive approach to transfusions. The consensus seems to suggest a transfusion approach based on hematocrit triggers and the clinical status of the infant.<sup>36,37</sup> Even though these studies have promising results, the restrictive approach allows infants to be exposed to lower levels of hemoglobin with no well-defined guidelines with a safe threshold without increasing the comorbidities and mortality.<sup>37</sup>

The clinical decision-making for RBC transfusions should be weighed against the potential for known associations with neonatal diseases. Severe anemia has been shown to be an independent risk factor for NEC,<sup>14,38</sup> possibly through activation of the pro-inflammatory cytokines, such as IFN gamma and TNF alpha, by intestinal macrophages leading to damage to the gut epithelium.<sup>39,40</sup> This superimposed with hypoxia, and the presence of a relatively fragile vascular bed further disrupts the mucosal barrier.<sup>41,42</sup> Likewise, severe anemia results in tissue hypoxia, oxidative injury, and disturbance in cerebral perfusion leading to cerebral injury with potentially impact short and long-term

**Table 3:** Tiered approach for investigation of neonatal anemia

| Investigations   |
|--|
| Tier 1 ( <i>guided by clinical setting</i> ): CBC with RBC indices and peripheral smear, reticulocyte count, LFTs (if infant has hyperbilirubinemia or concerns for congenital infections), and Coombs' test                               |
| Tier 2 ( <i>focused on etiology</i> ): TORCH antibodies, urine/buccal CMV, hemoglobin electrophoresis, blood culture for sepsis, haptoglobin, lactate dehydrogenase (LDH) level, Kleihauer Betke test, follow-up newborn screening results |
| Tier 3 ( <i>more invasive and focused on etiology</i> ): Bone marrow biopsy/aspirate (for neonatal leukemias, bone marrow infiltrative disorders, neonatal hemochromatosis)  |

neurodevelopmental outcomes.<sup>43–45</sup> Multiple studies have reported a decrease in regional oxygen saturation in the brain and an increase in fractional tissue oxygen extraction with increasing anemia severity.<sup>46–48</sup> Despite this, the exact clinical significance in terms of brain development and cognitive outcomes is not well defined. Whyte et al. analyzed a subgroup of infants in the PINT trial and reported lower cognition at 18–21 months' age in infants that were managed under a restrictive transfusion group.<sup>20,49</sup> While the TOP and ETTNO studies noted that there was no difference in neurodevelopmental outcome at two years corrected age when infants were randomized to liberal vs restrictive transfusion groups.

Neonatal anemia has also been linked with acute kidney injury (AKI), especially in the surgical population.<sup>50</sup> Nada et al. evaluated newborns from the Assessment of Worldwide AKI Epidemiology in Neonates (AWAKEN) database and were the first to show an association between anemia in the first week of life with late AKI in 2020.<sup>51</sup> But the findings were not significant after controlling for fluid balance. On the other hand, Nashimoto et al. recently highlighted AKI as an independent predictor for anemia due to less EPO production after interstitial damage.<sup>51,52</sup> Further studies are needed to describe anemia and its relationship with AKI.

### Laboratory Diagnosis

Hemoglobin measurements are now the primary index for the diagnosis of anemia. These results show the amount of the Hb protein found in RBCs and are expressed as grams per deciliter (gm/dL) or grams per liter (gm/L) of blood. Several high-quality laboratory techniques are available for these measurements. Several other indices are also frequently assessed and can be useful:

- *Hematocrit* is a calculated value on most instruments and reflects the number and size of the RBCs. The hematocrit can drop with the loss of RBCs during hemorrhage or when there is a loss of MCV, as in microcytic anemia. Thus, the influence of MCV makes it less useful as a measure of anemia than Hb.
- *Red blood cell count (RCC)* is not a good indicator of the severity of anemia as it can remain unchanged even when changes in other indices such as the MCV or MCHC can lower the total amount of Hb.
- *Mean corpuscular volume (MCV)* can be a useful measurement. Low MCVs are referred to as microcytosis (microcytic RBCs) and high figures as macrocytosis. Red blood cell count volume is an important parameter in distinguishing the cause of anemia since some anemias cause red blood cell volume to drop while others cause it to rise. For example, microcytic anemias are usually due to defective HB synthesis while macrocytic anemias are often the consequences of problematic cell development.
- *Mean corpuscular hemoglobin concentration (MCHC)* is also reported. Low MCHCs indicate hypochromia. It is a frequently seen feature in anemia due to low Hb synthesis. A low hematocrit but a high MCHC may be seen in a hemolyzed sample in which the Hb from the RBCs is present in the plasma, but the RBCs

contributing to the hematocrit will be reduced, however. A similar situation occurs on some instruments with cold agglutinins that show the RBC counts and calculated hematocrit as falsely low while the Hb is accurate for the infant. The instruments can usually flag elevated MCHCs, even suggesting a cause such as a possibility of lipemia.

- *Mean cell hemoglobin (MCH)* is the actual weight (amount; picograms) of hemoglobin in the average RBC. It is dependent on the RBC size; small cells cannot contain as much Hb. The MCH usually correlates with the RBC volume, the MCV. It is expected that if the MCH is low then the MCV is also low, but hypochromia cannot be determined using the MCH. Thus, the MCH is usually not as useful as the MCHC, which correlates better with hypochromia.
- *RBC distribution width (RDW)* can be important. High RDWs indicate anisocytosis. The RDW is a statistical estimation of the variability in RBC size and is indicated as a standard deviation (RDW-SD) or the coefficient of variation (RDW-CV; SD divided by the MCV). Both indices show increased ranges of RBC size. Most anemic infants with increased hematopoiesis or following transfusions show increased RDWs.
- *RBC morphology* is still a useful evaluation (Fig. 1). The confirmation of microcytosis or macrocytosis suspected from MCV figures can help. High MCHCs can be evaluated for the presence of spherocytes, and if not found, then a cause of spurious elevation should be investigated. Hypochromia on the blood film should be correlated to a reduced MCHC. Infants with elevated RDWs but the normal volume and hemoglobin content may show anisocytosis with spherocytes and other sickle cells, hereditary ovalocytes/elliptocytes, stomatocytes, echinocytes, acanthocytes, and most teardrops/dacryocytes. High RDW but slightly lower MCV can be seen in schistocytes and keratocytes (helmet cells). Megaloblastic anemia with macro-ovalocytes may correlate with elevated MCV, but the shape change is not evident in most other numerical parameters. Target cells (codocytes) in thalassemia are hypochromic and can reduce the MCHC and perhaps the MCH.

### Clinical Management

It is very important to differentiate an infant that is asymptomatic at low hematocrit vs a clinically sick infant who will benefit from treatment. Severe anemia in a symptomatic infant may present with pallor, tachypnea, tachycardia, hepatomegaly, high cardiac output shock/hypovolemic shock, systolic ejection murmur, need for respiratory support and oxygenation, and signs of sepsis.<sup>29</sup> Table 3 presents the Tiered approach or investigation of neonatal anemia and guide management strategies.

There are no numerical cut-offs/thresholds for initiation of iron supplements, erythropoietin administration, or red blood transfusion as management is individualized to each infant with careful consideration to clinical status and etiology of anemia.<sup>10</sup> Social factors



**Table 4:** Indications for red blood cell transfusions*Indications for blood transfusion in acute blood loss*

Acute blood loss >20 percent of blood volume.

Acute blood loss >10 percent of blood volume with symptoms of decreased oxygen delivery (such as persistent acidosis) after volume resuscitation.

*Indications for blood transfusion in chronic blood loss*

Transfusions should be considered based upon the respiratory support needed by the infant.

They are dependent upon an HCT or hemoglobin value that is preferably measured from either a central venous or arterial sample.

- For infants requiring moderate or significant mechanical ventilation, defined as a fraction of inspired oxygen (FiO<sub>2</sub>) ≥0.4, and mean airway pressure (MAP) >8 cm H<sub>2</sub>O on a conventional ventilator or MAP >14 on a high-frequency ventilator, the HCT trigger is <30 percent (hemoglobin ≤10 gm/dL).
- For infants requiring minimal mechanical ventilation, defined as a fraction of inspired oxygen (FiO<sub>2</sub>) <0.4, and MAP ≤8 cm H<sub>2</sub>O on a conventional ventilator or MAP ≤14 on a high-frequency ventilator, the HCT trigger is <25 percent (hemoglobin ≤8 gm/dL).
- The HCT trigger is <25 percent (hemoglobin ≤8 gm/dL) for infants requiring supplemental low- or high-flow oxygen but not mechanical ventilation, and one or more of the following: tachycardia (heart rate ≥180 beats per minute) for ≥24 hours, tachypnea (respiratory rate ≥60 breaths per minute) for ≥24 hours, doubling of oxygen requirement from the previous 48 hours, metabolic acidosis as indicated by a pH 7.2 or serum lactate ≥2.5 mEq/L, weight gain <10 gm/kg per day over the previous four days while receiving ≥120 kcal/kg per day, or if the infant undergoes major surgery within 72 hours. For infants requiring oxygen without any signs, a transfusion is not considered until signs occur.
- In asymptomatic infants, the HCT trigger is 21 percent (hemoglobin ≤7 gm/dL) with an absolute reticulocyte <100,000/μL (<2 percent). Infants without signs or oxygen requirements who are actively producing new red cells and have an elevated reticulocyte count likely do not require a red cell transfusion. Other centers and societies have transfusion guidelines with higher HCT (hemoglobin) triggers, which are based upon similar requirements for respiratory support.

<sup>†</sup>Adapted from Ohls R, Garcia-Prats JA, Kim MS. Red blood cell transfusions in the newborn. UpToDate 2021. <http://www.uptodate.com/contents/red-blood-cell-transfusions-in-the-newborn> [Accessed April 12, 2022]

(e.g., access to the medical system, treatment of co-morbidities in pregnant females, and improvement in nutritional status) also need to be identified and exclusive breastfeeding mothers need to be supported in nutrition and correction of iron deficiency.<sup>53,54</sup>

### Iron Supplementation

A term healthy asymptomatic infant with physiologic anemia of infancy usually does not need treatment.<sup>31</sup> Iron is an essential micronutrient required for hemoglobin synthesis and oxygen transfer. A late preterm infant that is clinically asymptomatic and exclusively breastfed benefits with iron supplementation ranging from 2 to 6 mg/kg/day (higher doses for infants with more robust reticulocyte response or lower gestational age to support the hematopoiesis). Preterm infants fed with iron-fortified formula need less supplementation. Side effects of iron medication range from feeding intolerance, diarrhea, constipation, and black tarry stools.

### Packed Red Cell Transfusions

Preterm infants, especially EP infants get at least one transfusion during NICU stay.<sup>55</sup> The decision needs to be individualized with keeping in mind the complications of transfusions.<sup>55</sup> Acute blood loss requires immediate replacement with whole blood in case of emergency or packed red blood cells (RBC). The amount of external blood lost could potentially be determined by weighing the bandages, gauzes, and blankets. Internal blood loss is difficult to assess, and sometimes clinical setting can hint toward the volume (in subgaleal bleeding, 1 cm increase in head circumference equals to 38 cc blood loss).<sup>56</sup>

In contrast to acute blood loss, chronic *in utero* loss may be managed by partial exchange transfusion when newborns already

have increased circulatory volumes, and the main problem is peripheral oxygen delivery at the tissue level. Simple transfusion can add to further volume overload leading to cardiac failure. Examples of such scenarios are twin–twin transfusion or chronic fetomaternal hemorrhage and severe hemolytic anemias.<sup>57</sup> The volume of transfusion in mL is equal to the following calculation:

Wt. (kg) × blood volume per kg × (Desired HCT-Observed HCT)/HCT of PRBCs. Table 4 presents guidance for red cell transfusions in varied scenarios.<sup>54</sup>

Recently, there has been the focus on tolerating lower hematocrits in extremely premature infants who are off respiratory support.<sup>10,35</sup> Many clinical trials have suggested similar or worse clinical outcomes with liberal transfusion, especially in neurodevelopment outcomes such as cognitive ability, cerebral palsy, severe visual/hearing loss at 24 months' age, and even mortality.<sup>36,37,49</sup>

*Complications associated with red cell transfusions:* Transfusions have been associated with potential damage by ischemia-reperfusion damage or oxidative injury. They also inhibit hematopoiesis, have a risk of infection, graft vs host disease, transfusion-related acute lung injury (TRALI), transfusion-associated circulatory overload (TACO), transfusion-associated gut injury (TRAGI), an extension of IVH, ROP, and hyperkalemia.<sup>15,40,42,58,59</sup>

Transfusion-related acute lung injury (TRALI) is a complication coined by National Heart, Lung and Brain Institute (NHLBI) two decades ago and defined as a new acute lung injury/acute respiratory distress syndrome occurring during or within 6 hours after blood transfusion. A two-hit mechanism theory is described for pathogenesis: Firstly, neutrophils sequestration and priming in pulmonary vessels due to primary damage/insult to endothelium

by disease, followed by secondly, blood products in transfusion causing neutrophil activation and release of cytokines, reactive oxygen species, and proteases that cause further damage.<sup>59</sup> TRAGI is amongst the most controversial transfusion-associated complications and approximately one-fourth of the NEC cases reported are temporally associated within 48 hours of transfusions. One of the pathogenesis suggested includes chronically hypoxic mucosal layer due to anemia undergoes a reperfusion injury after transfusion aggravating the oxidative damage and eventually leading to NEC.<sup>14,38</sup>

Feeding during a blood transfusion is also an area of ambiguity with great variation in clinical practices. Krimmel et al. suggested that feeding stimulates superior mesenteric artery circulation which has been suggested to be protective against NEC and absent in preterm infants that were made NPO during transfusion.<sup>60</sup> Red blood cell transfusion has also been associated with an increase in mesenteric and pulmonary vasoreactivity in lamb models and concern for NEC with worse pulmonary outcomes.<sup>61,62</sup> Others have reported the opposite and reduction in NEC when practicing strict feeds withholding during transfusion.<sup>63</sup> Results are still pending for the pilot WHEAT (WithHolding Enteral feeds Around packed red cell Transfusion) trial that recruited preterm infants around London and Birmingham area from 2018 to 2019 and randomized to two groups, one withholding milk feeds and the second continuing feeding during transfusion.<sup>64</sup>

Lust et al. suggested that early transfusion (<10 days of life) is associated with ROP.<sup>65</sup> This is due to the shift of the Hb dissociation curve of HbF to HbA (contained in the transfusion unit) which leads to greater oxygen delivery at the cellular level.<sup>65</sup> Fresh RBCs transfusions that are leuko-reduced and irradiated are recommended in preterm infants to maximize benefits and reduce organ dysfunction.

### Erythropoiesis-stimulating Agents

Another modality in the management of neonatal anemia, particularly in infants born EP, is the administration of the erythropoiesis-stimulating agents like erythropoietin (EPO) and Darbopoetin. Studies in 2017 and 2019 noted an association between early EPO and lower total transfusion volume, rates of IVH, PVL, NEC, and donor exposure.<sup>66</sup> But due to a lack of consistency in literature, EPO is not commonly used in many centers. In 2020 Cochrane reported a decreased number of red blood cell transfusions following late EPO administration after 1 week of life.<sup>67</sup> It showed no benefit on avoiding donor exposure as most ELBW/critically sick infants were transfused prior to EPO administration.<sup>67</sup> Hence it might be more suitable for larger or stable/late preterm infants. Another Cochrane Review in 2020 concluded no added benefit of early vs late EPO administration on the frequency of transfusions but raised concern for an increased incidence of ROP. At this time, there is a need for further data for creating standardized guidelines for the use of EPO and Darbopoetin in neonates.

### FUTURE DIRECTIONS

With significant advances in neonatal care there has been a notable improvement in outcomes for newborns, and opportunities are being identified for prevention, identification, and management of neonatal anemia and related morbidities.

Delayed clamping at birth has been adopted by American Academy of Pediatrics and is defined as allowing blood flow from

the placenta to the newborn for at least 60 seconds or till the cord stops pulsating.<sup>32</sup> This has led to a significant reduction in anemia in term and preterm infants as well as improved neonatal hemodynamics with the increase in blood volume, improvement of cerebral perfusion, provision of a greater number of stem cells from the placenta, increase in iron stores, and reduction in the need for transfusions in early neonatal phase.<sup>32,68,69</sup>

Decreasing phlebotomy losses is probably the first major step in the reduction of anemia in preterm infants. In 2012, Hospital Italiano De Buenos Aires practiced a micro-collection technique for blood samples that significantly reduced blood transfusion requirements.<sup>70</sup> Collection of cord blood samples, clustering blood tests together, and performing tests closer to discharge for greater accuracy can potentially help with these efforts.

There have been considerable advances in the evaluation of iron deficiency in adults, and similar evaluations are needed in infants vis-à-vis the gestational and postnatal maturation, ethnicity, and geographic regions. The levels of total body iron are computable from plasma levels of serum ferritin and transferrin saturation. There might also be organ-specific differences in the levels of iron, ferritin, and transferrin saturation in the context of inflammatory disorders. Markers such as the soluble transferrin receptor/ferritin index and hepcidin levels may also be useful in the translational context. New iron preparations and new treatment modalities are available; high-dose intravenous iron compounds may show high degrees of efficacy, although long-term side effects remain to be evaluated.

Utilizing physiological markers to assess needs for red blood cell transfusion is vital. Near-infrared spectroscopy (NIRS) is a novel tool used to monitor cerebral and splanchnic saturations and is being explored to identify hotspots of low regional oxygenation saturation where red cell transfusions might be helpful.<sup>71-74</sup> Research is being done with a focus on having a sensitive marker for oxygen delivery (cerebral oxygen saturation, peripheral fractional oxygen extraction, and consumption),<sup>71-74</sup> cardiac changes identification on echocardiogram,<sup>75,76</sup> and biochemical markers like lactate and VEGF.<sup>77,78</sup>

### ORCID

Rachana Singh  <https://orcid.org/0000-0001-7783-1214>

### REFERENCES

1. Osungbade KO, Oladunjoye AO. Anaemia in Developing Countries: Burden and Prospects of Prevention and Control Anemia. London, UK: IntechOpen 2012:116-129. <http://www.intechopen.com/books/anemia/anaemia-in-developing-countries-burden-and-%20prospects-of-prevention-and-control>.
2. Ewusie JE, Ahiadeke C, Beyene J, et al. Prevalence of anemia among under-5 children in the Ghanaian population: estimates from the Ghana demographic and health survey. BMC Public Health 2014;14(1):626. DOI: 10.1186/1471-2458-14-626.
3. Kassebaum NJ, Jasrasaria R, Naghavi M, et al. A systematic analysis of global anemia burden from 1990 to 2010. Blood 2014;123(5):615-624. DOI: 10.1182/blood-2013-06-508325.
4. World Health Organization. Global Nutrition Targets 2025: Anaemia Policy Brief. World Health Organization 2014. <https://apps.who.int/iris/handle/10665/148556>.
5. Colombatti R, Sainati L, Trevisanuti D. Anemia and transfusion in the neonate. Semin Fetal Neonatal Med 2016;21(1):2-9. DOI: 10.1016/j.siny.2015.12.001.



6. Widness JA. Pathophysiology of anemia during the neonatal period, including anemia of prematurity. *Neoreviews* 2008;9(11):e520. DOI: 10.1542/neo.9-11-e520.
7. Brabin BJ, Kalanda BF, Verhoeff FH, et al. Risk factors for fetal anaemia in a malarious area of Malawi. *Ann Trop Paediatr* 2004;24(4):311–321. DOI: 10.1179/027249304225019136.
8. Hirata M, Kusakawa I, Ohde S, et al. Risk factors of infant anemia in the perinatal period. *Pediatr Int* 2017;59(4):447–451. DOI: 10.1111/ped.13174.
9. Ghirardello S, Dusi E, Cortinovis I, et al. Effects of red blood cell transfusions on the risk of developing complications or death: an observational study of a cohort of very low birth weight infants. *Am J Perinatol* 2017;34(1):88–95. DOI: 10.1055/s-0036-1584300.
10. Howarth C, Banerjee J, Aladangady N. Red blood cell transfusion in preterm infants: current evidence and controversies. *Neonatology* 2018;114(1):7–16. DOI: 10.1159/000486584.
11. Keir AK, Yang J, Harrison A, et al. Temporal changes in blood product usage in preterm neonates born at less than 30 weeks' gestation in Canada. *Transfusion* 2015;55(6):1340–1346. DOI: 10.1111/trf.12998.
12. Franz AR, Engel C, Bassler D, et al. Effects of liberal vs restrictive transfusion thresholds on survival and neurocognitive outcomes in extremely low-birth-weight infants: the ETTNO randomized clinical trial. *JAMA* 2020;324:560–570. DOI: 10.1001/jama.2020.10690.
13. Kirpalani H, Bell EF, Hintz SR, et al. Higher or lower hemoglobin transfusion thresholds for preterm infants. *N Engl J Med* 2020; 383(27):2639–2651. DOI: 10.1056/NEJMoa2020248.
14. Singh R, Shah BL, Frantz ID 3rd. Necrotizing enterocolitis and the role of anemia of prematurity. *Semin Perinatol* 2012;36(4):277–282. DOI: 10.1053/j.semperi.2012.04.008.
15. Patel RM, Knezevic A, Shenvi N, et al. Association of red blood cell transfusion, anemia, and necrotizing enterocolitis in very low-birth-weight infants. *JAMA* 2016;315(9):889–897. DOI: 10.1001/jama.2016.1204.
16. Le VT, Klebanoff MA, Talavera MM, et al. Transient effects of transfusion and feeding advances (volumetric and caloric) on necrotizing enterocolitis development: a case-crossover study. *PLoS One* 2017;12(6):e0179724. DOI: 10.1371/journal.pone.0179724.
17. Xiong X, Buekens P, Alexander S, et al. Anemia during pregnancy and birth outcome: a meta-analysis. *Am J Perinatol* 2000;17:137–146. DOI: 10.1055/s-2000-9508.
18. Rahman MM, Abe SK, Rahman MS, et al. Maternal anemia and risk of adverse birth and health outcomes in low- and middle-income countries: systematic review and meta-analysis. *Am J Clin Nutr* 2016;103(2):495–504. DOI: 10.3945/ajcn.115.107896.
19. Lee S, Guillet R, Cooper EM, et al. Prevalence of anemia and associations between neonatal iron status, hepcidin, and maternal iron status among neonates born to pregnant adolescents. *Pediatr Res* 2016;79(1–1):42–48. DOI: 10.1038/pr.2015.183.
20. Kalteren WS, Verhagen EA, Mintzer JP, et al. Anemia and red blood cell transfusions, cerebral oxygenation, brain injury and development, and neurodevelopmental outcome in preterm infants: a systematic review. *Front Pediatr* 2021;9:644462. DOI: 10.3389/fped.2021.644462.
21. Raffaelli G, Manzoni F, Cortesi V, et al. Iron homeostasis disruption and oxidative stress in preterm newborns. *Nutrients* 2020;12(6):1554. DOI: 10.3390/nu12061554.
22. Lozoff B, Georgieff MK. Iron deficiency and brain development. *Semin Perinatol* 2006;30(3):158–165. DOI: 10.1016/j.spen.2006.08.004.
23. Chaparro CM. Timing of umbilical cord clamping: effect on iron endowment of the newborn and later iron status. *Nutr Rev* 2011;69(1):S30–S36. DOI: 10.1111/j.1753-4887.2011.00430.x.
24. Haider BA, Olofin I, Wang M, et al. Anaemia, prenatal iron use, and risk of adverse pregnancy outcomes: systematic review and meta-analysis. *BMJ* 2013;346:f3443. DOI: 10.1136/bmj.f3443.
25. Parks S, Hoffman MK, Goudar SS, et al. Maternal anemia and maternal, fetal, and neonatal outcomes in a prospective cohort study in India and Pakistan. *BJOG* 2019;126(6):737–743. DOI: 10.1111/1471-0528.15585.
26. Porter HJ, Khong TY, Evans MF, et al. Parvovirus as a cause of hydrops fetalis: detection by in-situ hybridization. *J Clin Pathol* 1988;41(4): 381–383. DOI: 10.1136/jcp.41.4.381.
27. Garcia-Prats JA. Anemia of prematurity. In: Abrams SA, Mahoney DH, Kim MS (eds.). *UpToDate*; 2021. Available from: <http://www.uptodate.com/contents/anemia-of-prematurity> [Accessed May 5, 2022].
28. Gallagher PG. The neonatal erythrocyte and its disorders. In: Orkin SH, Fisher DE, Look T, et al. (eds.) *Nathan and Oski's Hematology and Oncology of Infancy and Childhood*, 8th ed. WB Saunders: Philadelphia; 2015. p. 52.
29. Aher SM, Ohlsson A. Early versus late erythropoietin for preventing red blood cell transfusion in preterm and/or low birth weight infants. *Cochrane Database Syst Rev* 2020;2(2):CD004865.
30. Powers JM, Sandoval C. Approach to the child with anemia. In: Mahoney DH, Lorin MI, Armsby C (eds.). *UpToDate*. Available from: <http://www.uptodate.com/contents/approach-to-the-child-with-anemia> [Accessed May 4, 2022].
31. Stockman JA 3rd, Oski FA. Physiological anaemia of infancy and the anaemia of prematurity. *Clin Hematol* 1978;7(1):3–18. PMID: 657601.
32. Alzaree F, Elbohoty A, Abdellatif M. Early versus delayed umbilical cord clamping on physiologic anemia of the newborn Infant. *Open Access Maced J Med Sci* 2018;6(8):1399–1404. DOI: 10.3889/oamjms.2018.286.
33. Hasanbegovic E, Cengic N, Hasanbegovic S, et al. Evaluation and treatment of anemia in premature infants. *Med Arch* 2016;70(6): 408–412. DOI: 10.5455/medarh.2016.70.408-412.
34. Vali P, Underwood M, Lakshminrusimha S. Hemoglobin oxygen saturation targets in the neonatal intensive care unit: is there a light at the end of the tunnel? *Can J Physiol Pharmacol* 2019;97(3):174–182. DOI: 10.1139/cjpp-2018-0376.
35. Kirpalani H, Whyte RK, Andersen C, et al. The Premature Infants in Need of Transfusion (PINT) study: a randomized, controlled trial of a restrictive (low) versus liberal (high) transfusion threshold for extremely low birth weight infants. *J Pediatr* 2006;149(3):301–307. DOI: 10.1016/j.jpeds.2006.05.011.
36. Kleinman S, Caulfield T, Chan P, et al. Toward an understanding of transfusion related acute lung injury: statement of a consensus panel. *Transfusion* 2004;44(12):1774–1789. DOI: 10.1111/j.0041-1132.2004.04347.x.
37. Whyte R, Kirpalani H. Low versus high haemoglobin concentration threshold for blood transfusion for preventing morbidity and mortality in very low birth weight infants. *Cochrane Database Syst Rev* 2011;(11):CD000512. DOI: 10.1002/14651858.CD000512.pub2.
38. Singh R, Visintainer PF, Frantz ID 3rd, et al. Association of necrotizing enterocolitis with anemia and packed red blood cell transfusions in preterm infants. *J Perinatol* 2011;31(3):176–182. DOI: 10.1038/jp.2010.145.
39. Hunter CJ, De Plaen IG. Inflammatory signaling in NEC: role of NF- $\kappa$ B, cytokines and other inflammatory mediators. *Pathophysiology* 2014;21(1):55–65. DOI: 10.1016/j.pathophys.2013.11.010.
40. Maheshwari A, Schelonka RL, Dimmitt RA, et al. Cytokines associated with necrotizing enterocolitis in extremely-low-birth-weight infants. *Pediatr Res* 2014;76(1):100–108. DOI: 10.1038/pr.2014.48.
41. Saroha V, Josephson CD, Patel RM. Epidemiology of NEC regarding the influence of red blood cell transfusions and anemia. *Clin Perinatol* 2019;46(1):101–117. DOI: 10.1016/j.clp.2018.09.006.
42. La Gamma EF, Blau J. Transfusion-related acute gut injury: feeding, flora, flow, and barrier defense. *Semin Perinatol* 2012;36(4):294–305. DOI: 10.1053/j.semperi.2012.04.011.
43. Serenius F, Ewald U, Farrow A, et al. Neurodevelopmental outcomes among extremely preterm infants 6.5 years after active perinatal care in Sweden. *JAMA Pediatr* 2016;170(10):954–963. DOI: 10.1001/jamapediatrics.2016.1210.
44. van Hoften JCR, Verhagen EA, Keating P, et al. Cerebral tissue oxygen saturation and extraction in preterm infants before and after blood

- transfusion. *Arch Dis Child Fetal Neonatal Ed* 2010;95(5):F352–F358. DOI: 10.1136/adc.2009.163592.
45. Balegar KK, Stark MJ, Briggs N, et al. Early cerebral oxygen extraction and the risk of death or sonographic brain injury in very preterm infants. *J Pediatr* 2014;164(3):475–480.e1. DOI: 10.1016/j.jpeds.2013.10.041.
  46. Whitehead HV, Vesoulis ZA, Maheshwari A, et al. Progressive anemia of prematurity is associated with a critical increase in cerebral oxygen extraction. *Early Hum Dev* 2019;140:104891. DOI: 10.1016/j.earlhumdev.2019.104891.
  47. Banerjee J, Leung TS, Aladangady N. Cerebral blood flow and oximetry response to blood transfusion in relation to chronological age in preterm infants. *Early Hum Dev* 2016;97:1–8. DOI: 10.1016/j.earlhumdev.2015.10.017.
  48. El-Dib M, Aly S, Govindan R, et al. Brain maturity and variation of oxygen extraction in premature infants. *Am J Perinatol* 2016;33(8):814–820. DOI: 10.1055/s-0036-1572542.
  49. Whyte RK, Kirpalani H, Asztalos EV, et al. Neurodevelopmental outcome of extremely low birth weight infants randomly assigned to restrictive or liberal hemoglobin thresholds for blood transfusion. *Pediatrics* 2009;123(1):207–213. DOI: 10.1542/peds.2008-0338.
  50. Lombardi YL, Ridel C, Touzot M. Anemia and acute kidney injury: the tip of the iceberg? *Clin Kidney J* 2021;14(2):471–473. DOI: 10.1093/cjkj/sfaa202.
  51. Nada A, Askenazi D, Boohaker LJ, et al. Low hemoglobin levels are independently associated with neonatal acute kidney injury: a report from the AWAKEN Study Group. *Pediatr Res* 2021;89(4):922–931. DOI: 10.1038/s41390-020-0963-x.
  52. Nashimoto M, Murashima M, Kokubu M, et al. Anemia following acute kidney injury after non-cardiac surgery and long-term outcomes: the NARA-AKI cohort study. *Clin Kid J* 2021;14(2):673–680. DOI: 10.1093/cjkj/sfaa184.
  53. Ree IM, Lopriore E. Updates in neonatal hematology: causes, risk factors, and management of anemia and thrombocytopenia. *Hematol Oncol Clin North Am* 2019;33(3):521–532. DOI: 10.1016/j.hoc.2019.01.013.
  54. Ohls R, Garcia-Prats JA, Kim MS. Red blood cell transfusions in the newborn. *UpToDate* 2021. <http://www.uptodate.com/contents/red-blood-cell-transfusions-in-the-newborn> [Accessed April 12, 2022].
  55. Maier RF, Sonntag J, Walka MM, et al. Changing practices of red blood cell transfusions in infants with birth weights less than 1000 g. *J Pediatr* 2000;136(2):220–224. DOI: 10.1016/s0022-3476(00)70105-3.
  56. Robinson RJ, Rossiter MA. Massive subaponeurotic haemorrhage in babies of African origin. *Arch Dis Child* 1968;43(232):684–687. DOI: 10.1136/adc.43.232.684.
  57. Teruya J, Tobian A, Armsby C. Red blood cell transfusion in infants and children: Selection of blood products. *UpToDate* 2022. <https://www.uptodate.com/contents/red-blood-cell-transfusion-in-infants-and-children-selection-of-blood-products> [Accessed April 12, 2022].
  58. Kim DH. Transfusion practice in neonates. *Korean J Pediatr* 2018;61(9):265–270. DOI: 10.3345/kjp.2018.06849.
  59. Silliman CC. The two-event model of transfusion-related acute lung injury. *Crit Care Med* 2006;34(5 Suppl):S124–S131. DOI: 10.1097/01.CCM.0000214292.62276.8E.
  60. Krimmel GA, Baker R, Yanowitz TD. Blood transfusion alters the superior mesenteric artery blood flow velocity response to feeding in premature infants. *Am J Perinatol* 2009;26(2):99–105. DOI: 10.1055/s-0028-1090595.
  61. Nair J, Gugino SF, Nielsen LC, et al. Packed red cell transfusions alter mesenteric arterial reactivity and nitric oxide pathway in preterm lambs. *Pediatr Res* 2013;74(6):652–657. DOI: 10.1038/pr.2013.153.
  62. Baron DM, Yu B, Lei C, et al. Pulmonary hypertension in lambs transfused with stored blood is prevented by breathing nitric oxide. *Anesthesiology* 2012;116(3):637–647. DOI: 10.1097/ALN.0b013e318246ef77.
  63. El-Dib M, Narang S, Lee E, et al. Red blood cell transfusion, feeding and necrotizing enterocolitis in preterm infants. *J Perinatol* 2011;31(3):183–187. DOI: 10.1038/jp.2010.157.
  64. Gale C, Modi N, Jawad S, et al. The WHEAT Pilot trial—with holding enteral feeds around packed red cell transfusion to prevent necrotizing enterocolitis in preterm neonates: a multicenter, electronic patient record (EPR), randomized controlled point-of-care pilot trial. *BMJ Open* 2019;9(9):e033543. DOI: 10.1136/bmjopen-2019-033543.
  65. Lust C, Vesoulis Z, Jackups R Jr, et al. Early red cell transfusion is associated with development of severe retinopathy of prematurity. *J Perinatol* 2019;39(3):393–400. DOI: 10.1038/s41372-018-0274-9.
  66. Ohlsson A, Aher SM. Early erythropoiesis-stimulating agents in preterm or low birth weight infants. *Cochrane Database Syst Rev* 2017(11):CD004863. DOI: 10.1002/14651858.CD004863.pub5.
  67. Aher SM, Ohlsson A. Late erythropoiesis-stimulating agents to prevent red blood cell transfusion in preterm or low birth weight infants. *Cochrane Database Syst Rev* 2019;2(2):CD004868. DOI: 10.1002/14651858.CD004868.pub5.
  68. Mercer JS, Erickson-Owens DA, Deoni SC, et al. The effects of delayed cord clamping on 12-month brain myelin content and neurodevelopment: a randomized controlled trial. *Am J Perinatol* 2022;39(1):37–44. DOI: 10.1055/s-0040-1714258.
  69. Brown BE, Shah PS, Afifi JK, et al. Delayed cord clamping in small for gestational age preterm infants. *Am J Obstet Gynecol* 2022;226(2):247.e1–247.e10. DOI: 10.1016/j.ajog.2021.08.003.
  70. Pablo HBD, Galletti MF, Carrascal MP, et al. Impact of the volume of blood collected by phlebotomy on transfusion requirements in preterm infants with birth weight of less than 1500 g. A quasi-experimental study. *Arch Argent Pediatr* 2020;118(2):109–116. DOI: 10.5546/aap.2020.eng.109.
  71. Mintzer JP, Moore JE. Regional tissue oxygenation monitoring in the neonatal intensive care unit: evidence for clinical strategies and future directions. *Pediatr Res* 2019;86(3):296–304. DOI: 10.1038/s41390-019-0466-9.
  72. Garvey AA, Kooi EMW, Smith A, et al. Interpretation of cerebral oxygenation changes in the preterm infant. *Children (Basel)* 2018;5(7):94. DOI: 10.3390/children5070094.
  73. Van Bel F, Mintzer JP. Monitoring cerebral oxygenation of the immature brain: a neuroprotective strategy? *Pediatr Res* 2018;84(2):159–164. DOI: 10.1038/s41390-018-0026-8.
  74. Banerjee J, Aladangady N. Biomarkers to decide red blood cell transfusion in newborn infants. *Transfusion* 2014;54(10):2574–2582. DOI: 10.1111/trf.12670.
  75. Alkalay AL, Galvis S, Ferry DA, et al. Hemodynamic changes in anemic premature infants: are we allowing the hematocrits to fall too low? *Pediatrics* 2003;112(4):838–845. DOI: 10.1542/peds.112.4.838.
  76. Bard H, Fouron JC, Chessex P, et al. Myocardial, erythropoietic and metabolic adaptations to anemia of prematurity in infants with bronchopulmonary dysplasia. *J Pediatr* 1998;132(4):630–634. DOI: 10.1016/s0022-3476(98)70351-8.
  77. Izraeli S, Ben-Sira L, Harell D, et al. Lactic acid as a predictor for erythrocyte transfusion in healthy preterm infants with anemia of prematurity. *J Pediatr* 1993;122(4):629–631. DOI: 10.1016/s0022-3476(05)83551-6.
  78. Tschirch E, Weber B, Koehne P, et al. Vascular endothelial growth factor as marker for tissue hypoxia and transfusion need in anemic infants: a prospective clinical study. *Pediatrics* 2009;123(3):784–790. DOI: 10.1542/peds.2007-2304.



# Use of Fresh-frozen Plasma in Newborn Infants

Manvi Tyagi<sup>1</sup>, Akhil Maheshwari<sup>2</sup>, Brunetta Guaragni<sup>3</sup>, Mario Motta<sup>4</sup>

Received on: 10 September 2022; Accepted on: 14 September 2022; Published on: 07 October 2022

## ABSTRACT

Nearly 10% of premature and critically ill infants receive fresh-frozen plasma (FFP) transfusions to reduce their high risk of bleeding. The authors have only limited data to identify relevant clinical predictors of bleeding and to evaluate the efficacy of FFP administration. There is still no consensus on the optimal use of FFP in infants who have abnormal coagulation parameters but are not having active bleeding. The aims of this review are to present current evidence derived from clinical studies focused on the use of FFP in neonatology and then use these data to propose best practice recommendations for the safety of neonates receiving FFP.

**Keywords:** Coagulation tests, Disseminated intravascular coagulation, Fresh-frozen plasma, Hemorrhages, Plasmapheresis, Relative risk, Whole-blood donor units.

*Newborn* (2022): 10.5005/jp-journals-11002-0039

## KEY POINTS

- Fresh-frozen plasma is prepared by freezing plasma obtained either from single whole-blood donor units or through plasmapheresis; it contains high levels of soluble pro-coagulation factors, natural anticoagulants, and the tissue plasminogen activator inhibitor.
- Premature and critically ill infants frequently receive FFP transfusions due to high risk of bleeding; clinical studies show records of such treatment in up to 10% of these infants.
- Infants longer clotting times than adults which may be developmentally appropriate, and the risk of bleeding may not be proportionate to these deviations.
- Current evidence suggest that the use of FFP should be directed primarily to neonates with active bleeding and associated coagulopathy.
- Further information from controlled studies is needed to accurately identify neonates who are truly at risk for bleeding complications requiring FFP administration.

## INTRODUCTION

Up to 10% of all premature and critically ill infants receive FFP transfusions.<sup>1</sup> These patients comprise a fragile population at risk of hemorrhagic complications, but the data to identify clinical predictors of bleeding and to evaluate the efficacy of FFP administration are limited.<sup>2</sup> Consequently, despite continued efforts to develop clinical guidelines on FFP administration in neonates, the recommendations remain under-supported with low-quality evidence, and there is a lack of consensus on its optimal use.<sup>3,4</sup> Not surprisingly, FFP continues to be administered to asymptomatic neonates who do not have any clinical evidence of bleeding. In many instances, FFP might be administered just to correct “prolonged” values in coagulation tests that might actually be developmentally appropriate. A large proportion of FFP transfusions in these infants cannot be easily justified based on risk or prior confirmed hemorrhage<sup>5,6</sup>

All the authors are members of the Global Newborn Society (<https://www.globalnewbornsociety.org/>)

<sup>1</sup>Department of Pediatrics, Augusta University, Georgia, United States of America

<sup>2</sup>Weatherby Healthcare, Fort Lauderdale, Florida, United States of America

<sup>3,4</sup>Neonatologia e Terapia Intensiva Neonatale, ASST Spedali Civili di Brescia, Italy

**Corresponding Author:** Mario Motta, Neonatologia e Terapia Intensiva Neonatale, ASST Spedali Civili di Brescia, Italy, Phone: +030 3995219, e-mail: [mario.motta@asst-spedalivicili.it](mailto:mario.motta@asst-spedalivicili.it)

**How to cite this article:** Tyagi M, Maheshwari A, Guaragni B, *et al.* Use of Fresh-frozen Plasma in Newborn Infants. *Newborn* 2022;1(3):271–277.

**Source of support:** This study was supported by the NIH (grant number R01HL133022).

**Conflicts of interest:** None

To optimize FFP transfusions in neonates, we need better understanding of the developmental changes in various physiological markers of hemostasis and the interpretation of coagulation tests to detect coagulopathy. The levels of most coagulation proteins in premature infants change with gestational development, resulting in wide ranges of standard coagulation screening tests such as the prothrombin time (PT) and activated plasma thromboplastin time (APTT, Fig. 1).<sup>7</sup> Furthermore, the risk of bleeding may not be proportionate to these deviations. There is a need for reference ranges appropriate for accurate/corrected gestational age to evaluate/interpret these maturational changes and coagulation tests in newborns.<sup>2,8–11</sup> Figure 2 shows the changes in fibrinogen levels and the change in PT/aPTT seen with development.

This review presents current evidence on the use of FFP in neonatology and a set of best practice recommendations for the safety of neonates receiving FFP. We have included evidence from an extensive literature search in databases PubMed, EMBASE, and Scopus. To avoid bias in identification of studies, keywords were short-listed prior to the actual search from anecdotal personal experience and from PubMed’s Medical Subject Heading (MeSH) thesaurus. For primary evaluation, we modified the Grading of Recommendations Assessment, Development, and Evaluation

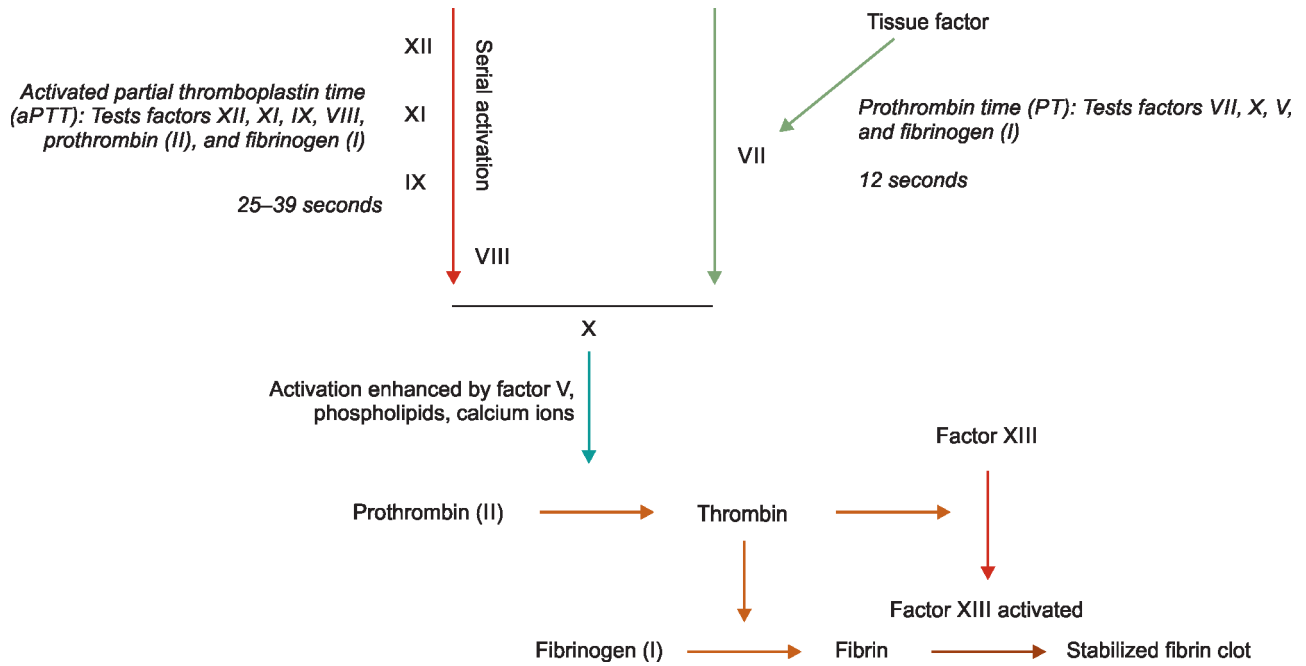
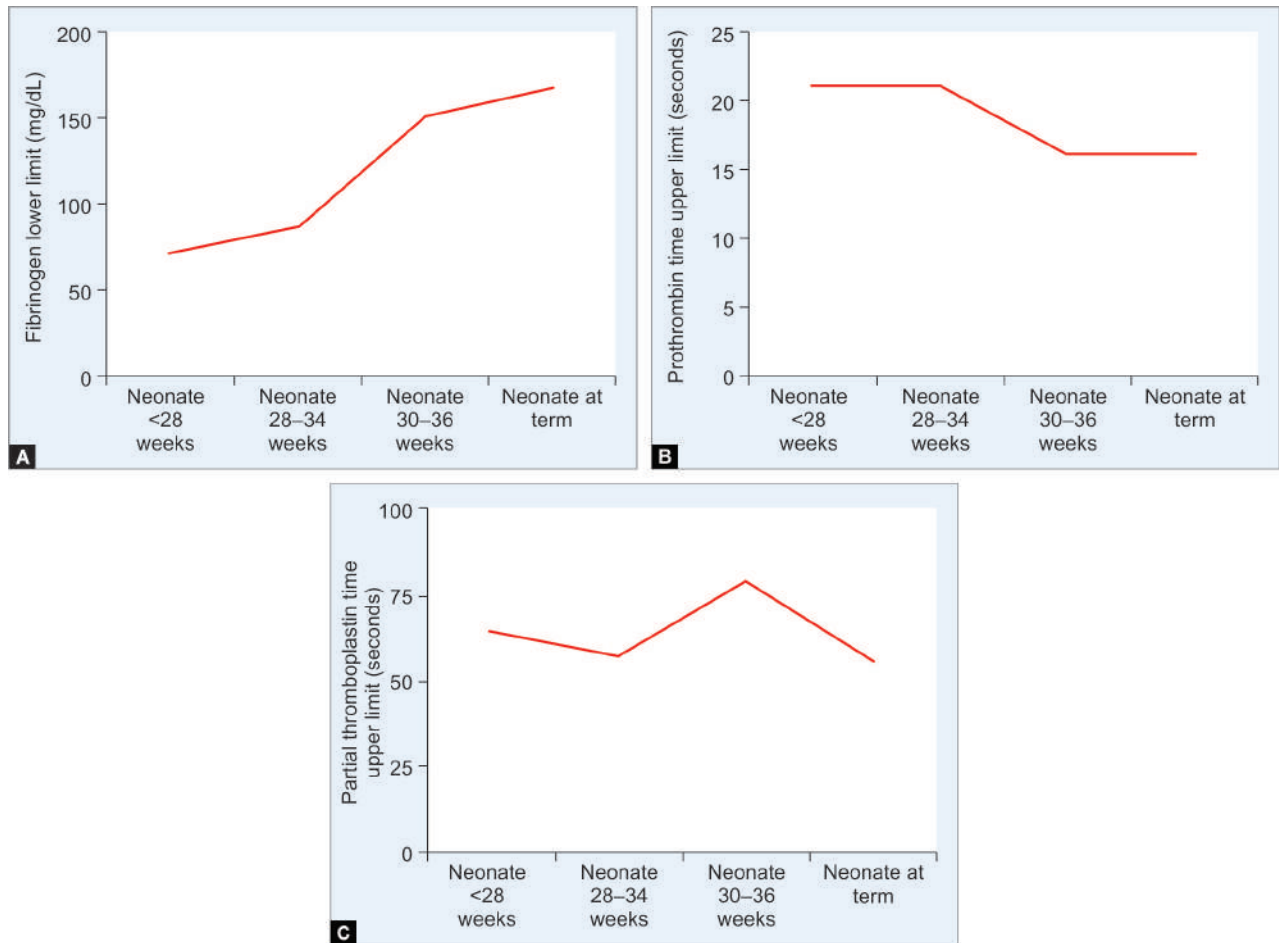


Fig. 1: Coagulation cascades and the traditionally used tests for evaluation in critically ill infants



Figs 2A to C: Line diagram in panel (A) show low plasma fibrinogen levels in extremely premature infants that rise toward term gestation. Panels (B and C) show the high degree of variability in prothrombin and PTTs across gestational maturation (adapted from Girelli et al. Blood Transfus 2015;13:484-497)





**Table 1:** Criteria for assigning grade of evidence and strength of recommendations

| Quality of evidence         | Type of clinical study  | Consistency of results  |
|-----------------------------|---|---|
| A = High                    | Randomized trial without important limitations  | Considerable confidence in the estimate of effect   |
| B = Moderate                | Randomized trial with important limitations or exceptionally observational studies with strong evidence | Further research likely to have impact on the confidence in estimate, may change estimate   |
| C = Low                     | Observational studies or case series  | Further research is very likely to have impact on confidence, likely to change the estimate |
| Strength of recommendations | Balance between benefits and harms  |   |
| 1 = Strong                  | Certainty of imbalance  |   |
| 2 = Weak                    | Uncertainty of imbalance  |   |

The grading scheme classifies the quality of evidence as high (grade A), moderate (grade B), or low (grade C) according to the study design and to the consistency of results. The strength of recommendations was further classified as either strong (1) or weak (2) according to the balance between desirable and undesirable outcomes. Strong recommendations (1) are made when there is confidence that the benefits either do or do not outweigh the harm and costs of treatment. Where the magnitude of benefit or not is less certain, a weaker (2) recommendation is made. Grade I recommendations can be applied uniformly to most patients, whereas grade II recommendations require a more individualized application

**Table 2:** Choice of donors by blood groups for FFP transfusion therapy

| ABO phenotype of the recipient | ABO phenotype of units to transfuse (in order of preference) |
|--------------------------------|--|
| O                              | O, A, B, AB  |
| A                              | A, AB  |
| B                              | B, AB  |
| AB                             | AB   |

(GRADE) system to assess the quality of evidence and strength of recommendations (Table 1). In addition, we also used the conventional grading systems of recommendations and the levels of evidence defined by the Oxford Centre for Evidence-based Medicine (Supplemental tables 1–2).<sup>12,13</sup>

**Preparation, Characteristic, and Storage of FFP**

Fresh-frozen plasma is prepared by freezing plasma separated from single whole-blood donor units or during plasmapheresis.<sup>1</sup> It is usually separated by centrifugation at 1000–2000gm at 4°C or is isolated during plasmapheresis.<sup>14</sup> There are newer techniques where whole blood is passed through semipermeable membranes and do not require centrifugation. These bags are usually stored frozen at 30°C. When needed for clinical use, FFP is thawed by placing the bags in a water bath at a temperature of 30–37°C for 20–30 minutes or in an FDA-approved device for 1–6 minutes.<sup>15</sup> After thawing, plasma should be used within 1–6 hours, and if not, then it was stored at 1–6°C. If not frozen, the product should be discarded after 24 hours of preparation. Ideally, FFP should not be frozen once it has been thawed.

The plasma used must be compatible with the recipient in terms of the ABO blood groups (Table 2).<sup>8</sup> A standard dose of 10–20 mL/kg administered intravenously over 60 minutes (grade of evidence C, strength of recommendation typically raises circulating levels of the coagulation factors by approximately 20%, which is more than the 10% rise that is usually needed to correct hemostasis.<sup>16</sup> Prior to FFP administration, standard precautions that include matching of blood types to confirm ABO compatibility need to be undertaken. The bags should be carefully inspected to ensure that the product is not expired and also for any leaks. The product should not contain any blood clots.

**Table 3:** Coagulation factors in FFP

| Coagulation factor          | Plasma concentration required for hemostasis (units/mL). Transfusion of 10 mL/kg typically contains amounts of coagulation factors to achieve hemostasis. Factor levels in donor plasma can be assumed to be approximately 1 U/mL |
|-----------------------------|---|
| I (fibrinogen)              | 100–160 mg/dL   |
| II (prothrombin)            | 0.5   |
| V                           | 0.1–0.3   |
| VII                         | 0.05–0.25   |
| VIII                        | 0.1–0.45  |
| IX                          | 0.1–0.4   |
| X                           | 0.1–0.25  |
| XI                          | 0.15–0.35   |
| XIII                        | 0.1–0.6   |
| vWF (von Willebrand Factor) | 0.25–0.6  |

Fresh-frozen plasma preparations should be leukodepleted (white blood cells <1 × 10<sup>6</sup>/unit), preferably at the time of collection (prestorage, grade of evidence C, strength of recommendation 1). These measures may prevent nonhemolytic febrile reaction, reduce the risk of alloimmunization, and lower the risk of transmission of viral infection such as cytomegalovirus (grade of evidence B, strength of recommendation 1).<sup>17</sup>

Fresh-frozen plasma contains higher levels of soluble coagulation factors than whole blood.<sup>18</sup> It contains 400–900 mg/unit of fibrinogen, which is much higher than normal whole blood levels of 200–400 mg/dL; there are also high levels of factors VIII, II, VII, V, IX, X, XI, XII, and XIII (Table 3, data from our hospital laboratory).<sup>19,20</sup> There are also high levels of albumin, immunoglobulins, and of naturally occurring anticoagulants such as proteins C and S, antithrombin, and the tissue plasminogen activator inhibitor.<sup>21,22</sup> Maintenance of the frozen state is the most important for factor VII.<sup>13</sup> The activity of factors V and VIII also declines, although at a slightly slower rate.<sup>23</sup> These details are important for the choice of therapeutic measures to prevent/treat hemorrhages in a critically ill infant; other preparations such as cryoprecipitate are richer in

fibrinogen, factor VIII and von Willebrand factor but may not be as effective volume expanders.<sup>13,14,18</sup>

Some centers have applied viral inactivation methods to FFP.<sup>24</sup> Solvent/detergent treatment of plasma pooled from about 1000 units allows a high degree of standardization, shows known concentration and activity of key bioactive proteins, has reduced immunological risks related to antibodies and leukocytes, and eliminates pathogens such as hepatitis A and parvovirus.<sup>24–26</sup> Treatment of FFP with methylene blue, a phenothiazine dye, can also be virucidal.<sup>27</sup> There is more biological variability as it is derived by addition of an inactivation method to single units of plasma. Viral inactivation methods may reduce the concentrations of some clotting factors and inhibitors of coagulation.<sup>27</sup>

### Indications for FFP Administration in Infants

The use of FFP in newborn infants have been reported across different clinical setting. Fresh-frozen plasma corrects coagulopathy by replacing deficient/defective clotting factors,<sup>28</sup> and it is usually used in active bleeding as replacement therapy in conditions associated with coagulopathy. We have summarized the current information in favor of FFP administration in various clinical situations:

- Volume expansion in very preterm infant

Premature ill infants are at high risk of bleeding, particularly intraventricular, and are frequently treated prophylactically with FFP administrations.<sup>19,29</sup> Four studies have investigated prophylactic administration of FFP transfusions in pre-term neonates to decrease the incidence of IVH: One showed FFP to reduce IVH, but the other three reported no change in similar IVH rates,<sup>13,30–32</sup> and a meta-analysis found no differences in grade of IVH or mortality.<sup>33</sup> We suggest that the routine use of FFP should be avoided in preterm infants in the absence of active bleeding (grade of evidence A, strength of recommendation 1).

- Cardiac surgery/cardiopulmonary bypass

About a fifth of all infants with congenital heart defects (CHD, 2–3/1000 births) may require surgery.<sup>34</sup> Up to 40% of infants with surgical CHD may show severe complications in the postoperative period,<sup>35</sup> with mediastinal blood losses as high as 100 mL/kg. Hypofibrinogenemia and inadequate reversal of heparin effects may contribute to perioperative bleeding. Fresh-frozen plasma, platelets, cryoprecipitate, RBCs, and antifibrinolytic drugs are often administered to prevent/stop bleeding; the concerns are higher because surgical re-exploration of the chest in infants with severe bleeding was successful in controlling the hemorrhage in less than half of all the cases.<sup>35</sup> Infants with excessive bleeding may exhibit hypofibrinogenemia at the end of CPB and are frequently treated with FFP/cryoprecipitate;<sup>36</sup> hypofibrinogenemia is known to alter clot formation.<sup>8</sup> Bleeding risk is increased with concurrent thrombocytopenia, and hence platelet transfusion is appropriate in these settings.<sup>37</sup> The contribution of fibrinolysis to bleeding during CPB is still unclear.<sup>38</sup> Ongoing fibrinolysis seems to exacerbate bleeding; antifibrinolytics may help reduce perioperative bleeding after cardiac surgery in some, but not in all cases.

During CPB complex coagulopathy occurs and the predictive value of routine tests such as PT, partial thromboplastin time (PTT), and platelet counts may not always be useful.<sup>39</sup> The importance of FFP administration has been investigated in several trials that have compared the effectiveness of giving FFP before and after undergoing CPB.<sup>40</sup> Studies that evaluated FFP usage in infants, as part of the priming prior to the initiation of CPB, did not reduce blood loss or the need for transfusions in all cases.<sup>41</sup>

Current guidelines from the Network for the Advancement of Patient Blood Management, Haemostasis and Thrombosis<sup>42</sup> suggest the addition of fresh frozen plasma to the CPB prime in neonates undergoing cardiac surgery (grade of evidence B, strength of recommendation 1).

- Surgery and trauma

Surgical intervention and/or trauma frequently leads to hemorrhages.<sup>43</sup> Blood loss and metabolic changes such as acidosis and hypothermia can also accentuate bleeding.<sup>44</sup> Inadequate volume resuscitation and low tissue perfusion can increase the tissue expression of procoagulant mediators and lead to disseminated intravascular coagulation (DIC), lactic acidosis, and further disrupt vascular integrity and perfusion to set up a feed-forward loop.<sup>45</sup> Newborns and small infants do not compensate for hypovolemia in all conditions as well as adults; 10% loss of intravascular volume can disrupt vasomotor balance, peripheral tissue perfusion, and homeostasis in cardiac output. Hypothermia enhances many of these effects. Respiratory compromise can further accentuate these changes.

We need to carefully evaluate our strategies to minimize transfusions in elective surgical procedures. The benefits of FFP transfusions are not clear.<sup>46</sup> The use of prophylactic FFP prior to surgical procedures in infants who have abnormal clotting tests, but no active bleeding, is not supported in clinical studies. A detailed family history of bleeding, therapeutic history, and data on risk of bleeding in various surgical or other invasive procedures are more important than the results of *in vitro* clotting tests when assessing the risk of clinically significant bleeding. For infants who have abnormal clotting tests and other factors that indicate a significant bleeding risk during a procedure, FFP administration can be considered, although this is not evidence-based (grade of evidence C, strength of recommendation 2).<sup>33</sup>

- Congenital factor deficiencies

Congenital coagulation disorders are inherited conditions characterized by abnormally low levels of coagulation factors.<sup>47</sup> Hemophilia A and B, and von Willebrand disease, comprise nearly 80–85% of all cases with inherited bleeding disorders.<sup>48</sup> Hemophilia A and B can rarely present with bleeding symptoms in newborn period, as can homozygous deficiency of coagulation factors II, V, VII, X, and XIII.<sup>47</sup> Some of these inherited coagulation factor deficiencies may present in the neonatal period with intracranial and/or scalp hemorrhages, although most infants with these conditions do not have bleeding except with invasive procedures.<sup>49</sup> The other 15% result from deficiencies of fibrinogen, prothrombin, factors V, and combined factors V/VIII, VII, X, XI, and XIII.<sup>50</sup> These conditions can vary in severity from just a few cutaneous bleeds to potentially life-threatening hemorrhages.

The first line of treatment of inherited bleeding disorders is replacement of the deficient factor, using specific plasma-derived or recombinant products.<sup>51</sup> Single coagulation factors are available for the majority of deficient factors except for factors II, V, and XI.<sup>52</sup> For factor II deficiency, prothrombin complex concentrates (PCCs) can be used; these contain specific coagulation factors obtained from pooled normal plasma, namely factors II, IX, X, and VII in varying amounts depending on the product.

Fresh-frozen plasma can be administered in newborns and young infants with active bleeding during the initial hospital stay until the specific disorder has been identified, when specific products are not available or in resource limited countries (grade of evidence C, strength of recommendation 1). Large doses of FFP are



required in severe hemophilia and 15–25 mL/kg may be required to raise the FVIII/FIX concentration to hemostatic levels (grade of evidence C, strength of recommendation 1).

- Disseminated intravascular coagulation

Disseminated intravascular coagulation can occur in neonates with severe perinatal asphyxia, sepsis, shock, severe hypothermia, or necrotizing enterocolitis. These infants are usually critically ill and may bleed from multiple sites. Laboratory tests may show low platelet counts; prolonged PT and PTT; and decreased fibrinogen. Fibrin degradation products, such as d-dimers, can be elevated. The primary condition needs to be treated aggressively; the bleeding disorder can be controlled using FFP (grade of evidence C, strength of recommendation 1; other products such as cryoprecipitate and platelet concentrates may also be necessary. FFP/other blood products can bring temporizing relief while the primary condition is treated.<sup>53</sup> There may not be any strong, clinically relevant differences in the coagulation tests, outcomes of DIC, or in mortality.

- Vitamin K deficiency

Neonates express coagulation factors II, VII, IX, and X, which are vitamin K-dependent, at only about half the levels seen in adults.<sup>54</sup> Premature infants have even lower levels. Deficiency of vitamin K presents as hemorrhagic disease of the newborn (HDN) and can be associated with life-threatening intracranial hemorrhages.<sup>55</sup> There are two presentations:

1. Classical HDN occurs in the first week after birth due to a transient deficiency of vitamin K-dependent factors, and it is characterized by cutaneous bruising and/or intestinal hemorrhages in neonates. In infants born to mothers treated with drugs that suppress vitamin K metabolism, HDN can appear within the first 24 hours after birth. Routine administration of vitamin K soon after birth is effective in preventing classical HDN.<sup>56</sup>
2. Late HDN appears between 2 and 8 weeks after birth and is usually associated with vitamin K malabsorption. Vitamin K supplementation is effective within a few hours.<sup>57</sup> In addition to vitamin K, FFP can also help control severe bleeding or intracranial hemorrhage.<sup>57</sup>

Neonates who present with acute bleeding due to vitamin K deficiency should be treated upon suspicion with intravenous vitamin K, which will reverse the coagulopathy.<sup>58</sup> However, because vitamin K typically takes longer to show therapeutic effect, FFP should also be administered immediately to reduce the risk of devastating intracranial hemorrhages (grade of evidence C, strength of recommendation 1).

- Liver disease

Infants with acute or chronic liver disease may manifest with coagulopathy. Acute liver failure in neonates can occur due to birth asphyxia, sepsis, viral infections, and metabolic diseases. There may be decreased synthesis of pro- and anticoagulant factors, hypo- and dysfibrinogenemia, thrombocytopenia and platelet dysfunction, reduction of gamma-carboxylation of vitamin K-dependent proteins, and hyperfibrinolysis. To correct the coagulopathy, these infants require FFP and cryoprecipitate transfusions in addition to the treatment of the primary liver disease (grade of evidence C, strength of recommendation 2).<sup>59</sup>

- Extracorporeal membrane oxygenation (ECMO)

Extracorporeal membrane oxygenation is used to provide life support in infants with severe cardiorespiratory failure. These

infants may already have coagulopathy due to sepsis, shock, or profound hypoxia, which may increase the risk of intracranial hemorrhage. The foreign surface of the ECMO circuit can activate the coagulation cascade; heparinization can prevent clot formation, but this also increases the risk of bleeding.<sup>60</sup> FFP support may be needed in infants after surgery and in those with sepsis. Some infants who have been on prolonged ECMO and need frequent transfusions, FFP has been used to treat possible microhemorrhages.<sup>61</sup> However, in a clinical study, scheduled FFP administrations did not increase circuit life or reduce the need for blood product transfusions.<sup>62</sup> Patients in the intervention group had similar hemorrhagic and thrombotic complications as the control group.

As limited data are available on the transfusion practice of neonatal ECMO patients, the recommendations are based on expert opinion provided by different ECMO centers.<sup>63</sup>

- Exchange transfusion

Infants with severe unconjugated hyperbilirubinemia may need exchange transfusion to prevent bilirubin encephalopathy/kernicterus. Many centers use blood reconstituted from FFP and packed erythrocytes for exchange transfusions, although the evidence of benefit from the use of reconstituted blood is limited.<sup>64</sup>

Partial exchange transfusion (PET) is traditionally used as the method to lower the hematocrit and treat hyperviscosity in neonatal polycythemia. Three randomized clinical trials conducted to compare the efficacy of crystalloid solutions versus plasma used for PET to treat neonatal polycythemia showed variable results.<sup>65–67</sup> Two meta-analyses, which included all these three studies, showed no significant difference in the reduction of post-exchange hematocrit.<sup>68–70</sup> Fresh-frozen plasma should not be used to treat polycythemia unless there is a coexistent coagulopathy (grade of evidence A, strength of recommendation 1).

## Adverse Effects

Fresh-frozen plasma can have several adverse effects:<sup>71</sup>

- Immunological reactions, including early events due to innate immune reactions or delayed events such as alloimmunization to various circulatory antigens.
- Nonimmunologic complications seen with blood transfusions such as infections, circulatory overload, and metabolic derangements can also be seen with FFP administration. FFP lacks leukocytes, and therefore the transmission of cytomegalovirus is less frequent. However, human immunodeficiency virus (HIV) and hepatitis can be transmitted.<sup>72</sup> Circulatory overload can be seen in infants with pre-existing pulmonary edema or congestive heart failure. Metabolic complications like citrate toxicity and consequent hypocalcemia are rare but have been noted.

## CONCLUSIONS

Administration of FFP is a frequent intervention in premature and critically-ill infants. Current evidence suggests that FFP should be used primarily in neonates with active bleeding and associated coagulopathy, or for deficiency of congenital factors for which no specific concentrated coagulation factors are available. In the setting of neonatal acquired coagulopathy, evaluation and interpretation of the standard coagulation test (PT, APTT) should be based on reference ranges appropriate for gestational and post-natal age. More information from controlled studies is needed

to accurately identify infants who are truly at risk for bleeding complications and who actually need FFP transfusions.

## SUPPLEMENTARY MATERIAL

The supplementary tables are available online on the website of [www.newbornjournal.org](http://www.newbornjournal.org).

## REFERENCES

- Dzik W, Rao A. Why do physicians request fresh frozen plasma? *Transfusion* 2004;44(9):1393–1394. DOI: 10.1111/j.0041-1132.2004.00422.x.
- Neary E, McCallion N, Kevane B, et al. Coagulation indices in very preterm infants from cord blood and postnatal samples. *J Thromb Haemost* 2015;13(11):2021–2030. DOI: 10.1111/jth.13130.
- Howick J, Chalmers I, Glasziou P, et al. The 2011 Oxford CEBM Evidence Levels of Evidence (Introductory Document). Oxford Centre for Evidence-Based Medicine. 2022. <https://www.cebm.ox.ac.uk/resources/levels-of-evidence/levels-of-evidence-introductory-document>.
- Girelli G, Antonucci S, Casadei AM, et al. Recommendations for transfusion therapy in neonatology. *Blood Transfus* 2015;13(3):484–497. DOI: 10.2450/2015.0113-15.
- Gross SJ, Filston HC, Anderson JC. Controlled study of treatment for disseminated intravascular coagulation in the neonate. *J Pediatr* 1982;100(3):445–448. DOI: 10.1016/s0022-3476(82)80457-5.
- Neary E, Ni Ainle F, El-Khuffash A, et al. Plasma transfusion to prevent intraventricular haemorrhage in very preterm infants. *Cochrane Database Syst Rev* 2016;9:CD012341. DOI: 10.1002/14651858.CD012341.
- Pal S, Curley A, Stanworth SJ. Interpretation of clotting tests in the neonate. *Arch Dis Child Fetal Neonatal Ed* 2015;100(3):F270–274. DOI: 10.1136/archdischild-2014-306196.
- Wallis JP, Dzik S. Is fresh frozen plasma overtransfused in the United States? *Transfusion* 2004;44(11):1674–165. DOI: 10.1111/j.0041-1132.2004.00427.x.
- Andrew M, Paes B, Milner R, et al. Development of the human coagulation system in the full-term infant. *Blood* 1987;70(1):165–172. PMID: 3593964.
- Andrew M, Paes B, Milner R, et al. Development of the human coagulation system in the healthy premature infant. *Blood* 1988;72(5):1651–1657. PMID: 3179444.
- Christensen RD, Baer VL, Lambert DK, Henry E, Ilstrup SJ, Bennett ST. Reference intervals for common coagulation tests of preterm infants (CME). *Transfusion* 2014;54(3):627–632:quiz 626. DOI: 10.1111/trf.12322.
- Atkins D, Best D, Briss PA, et al. Grading quality of evidence and strength of recommendations. *BMJ* 2004;328(7454):1490. DOI: 10.1136/bmj.328.7454.1490.
- A randomized trial comparing the effect of prophylactic intravenous fresh frozen plasma, gelatin or glucose on early mortality and morbidity in preterm babies. The Northern Neonatal Nursing Initiative [NINI] Trial Group. *Eur J Pediatr* 1996;155(7):580–588. DOI: 10.1007/BF01957909.
- O'Shaughnessy DF, Atterbury C, Bolton Maggs P, et al. Guidelines for the use of fresh-frozen plasma, cryoprecipitate and cryopernatant. *Br J Haematol* 2004;126(1):11–28. DOI: 10.1111/j.1365-2141.2004.04972.x.
- Westphal RG, Tindle B, Howard PL, Golden EA, Page GA. Rapid thawing of fresh frozen plasma. *Am J Clin Pathol* 1982;78(2):220–222. DOI: 10.1093/ajcp/78.2.220.
- Gibson BE, Todd A, Roberts I, et al. Transfusion guidelines for neonates and older children. *Br J Haematol* 2004;124(4):433–453. DOI: 10.1111/j.1365-2141.2004.04815.x.
- Liumbruno G, Bennardello F, Lattanzio A, et al. Recommendations for the transfusion of plasma and platelets. *Blood Transfus* 2009;7(2):132–150. DOI: 10.2450/2009.0005-09.
- Nair PM, Rendo MJ, Reddoch-Cardenas KM, Burriss JK, Meledeo MA, Cap AP. Recent advances in use of fresh frozen plasma, cryoprecipitate, immunoglobulins, and clotting factors for transfusion support in patients with hematologic disease. *Semin Hematol* 2020;57(2):73–82. DOI: 10.1053/j.seminhematol.2020.07.006.
- Neary E, Okafor I, Al-Awaysheh F, et al. Laboratory coagulation parameters in extremely premature infants born earlier than 27 gestational weeks upon admission to a neonatal intensive care unit. *Neonatology* 2013;104(3):222–227. DOI: 10.1159/000353366.
- Matsunaga S, Takai Y, Nakamura E, et al. The clinical efficacy of fibrinogen concentrate in massive obstetric haemorrhage with hypofibrinogenemia. *Sci Rep* 2017;7:46749. DOI: 10.1038/srep46749.
- Pescatore SL. Clinical management of protein C deficiency. *Expert Opin Pharmacother* 2001;2(3):431–439. DOI: 10.1517/14656566.2.3.431.
- Nascimento B, Callum J, Rubenfeld G, et al. Clinical review: fresh frozen plasma in massive bleedings - more questions than answers. *Crit Care* 2010;14(1):202. DOI: 10.1186/cc8205.
- Dogra M, Sidhu M, Vasudev R, Dogra A. Comparative analysis of activity of coagulation factors V and VIII and level of fibrinogen in fresh frozen plasma and frozen plasma. *Asian J Transfus Sci* 2015;9(1):6–8. DOI: 10.4103/0973-6247.150936.
- Horowitz B, Wiebe ME, Lippin A, et al. Inactivation of viruses in labile blood derivatives. I. Disruption of lipid-enveloped viruses by tri(n-butyl)phosphate detergent combinations. *Transfusion* 1985;25(6):516–522. DOI: 10.1046/j.1537-2995.1985.25686071422.x.
- Liumbruno GM, Franchini M. Solvent/detergent plasma: pharmaceutical characteristics and clinical experience. *J Thromb Thrombolysis* 2015;39(1):118–128. DOI: 10.1007/s11239-014-1086-1.
- Dichtelmuller HO, Biesert L, Fabbri F, et al. Robustness of solvent/detergent treatment of plasma derivatives: A data collection from plasma protein therapeutics association member companies. *Transfusion* 2009;49(9):1931–1943. DOI: 10.1111/j.1537-2995.2009.02222.x.
- de la Rubia J, Arriaga F, Linares D, et al. Role of methylene blue-treated or fresh-frozen plasma in the response to plasma exchange in patients with thrombotic thrombocytopenic purpura. *Br J Haematol* 2001;114(3):721–723. DOI: 10.1046/j.1365-2141.2001.02991.x.
- Shabanian R, Dehestani A, Dadkhah M, et al. Fresh frozen plasma prime and the level of gammaglobulin after pediatric cardiopulmonary bypass. *Am J Clin Exp Immunol* 2020;9(5):91–100. PMID: 33489477.
- Houben NAM, Heeger LE, Stanworth SJ, et al. Changes in the use of fresh-frozen plasma transfusions in preterm neonates: A single center experience. *J Clin Med* 2020;9(11):3789. DOI: 10.3390/jcm9113789.
- Hambleton G, Appleyard WJ. Controlled trial of fresh frozen plasma in asphyxiated low birthweight infants. *Arch Dis Child* 1973;48(1):31–35. DOI: 10.1136/adc.48.1.31.
- Beverly DW, Pitts-Tucker TJ, Congdon PJ, Arthur RJ, Tate G. Prevention of intraventricular haemorrhage by fresh frozen plasma. *Arch Dis Child* 1985;60(8):710–713. DOI: 10.1136/adc.60.8.710.
- Ekblad H, Kero P, Shaffer S, et al. Extracellular volume in preterm infants: influence of gestational age and colloids. *Early Hum Dev* 1991;27(1–2):1–7. DOI: 10.1016/0378-3782(91)90022-u.
- Osborn DA, Evans N. Early volume expansion for prevention of morbidity and mortality in very preterm infants. *Cochrane Database Syst Rev* 2004;(2):CD002055. DOI: 10.1002/14651858.CD002055.pub2.
- Kempny A, Dimopoulos K, Uebing A, et al. Outcome of cardiac surgery in patients with congenital heart disease in England between 1997 and 2015. *PLoS One* 2017;12(6):e0178963. DOI: 10.1371/journal.pone.0178963.
- Mirzaei M, Mirzaei S, Sepahvand E, et al. Evaluation of complications of heart surgery in children with congenital heart disease at Dena Hospital of Shiraz. *Glob J Health Sci* 2015;8(5):33–38. DOI: 10.5539/gjhs.v8n5p33.
- Erdoes G, Gerster G, Colucci G, et al. Prediction of post-weaning fibrinogen status during cardiopulmonary bypass: An observational study in 110 patients. *PLoS ONE* 2015;10(5):e0126692. DOI: 10.1371/journal.pone.0126692.



37. Hanson SJ, Karam O, Birch R, et al. Transfusion practices in pediatric cardiac surgery requiring cardiopulmonary bypass: A secondary analysis of a clinical database. *Pediatr Crit Care Med* 2021;22(11):978–987. DOI: 10.1097/PCC.0000000000002805.
38. Ray MJ, Marsh NA, Hawson GA. Relationship of fibrinolysis and platelet function to bleeding after cardiopulmonary bypass. *Blood Coagul Fibrinolysis* 1994;5(5):679–685. DOI: 10.1097/00001721-199410000-00002.
39. Hofer J, Fries D, Solomon C, et al. A snapshot of coagulopathy after cardiopulmonary bypass. *Clin Appl Thromb Hemost* 2016;22(6):505–511. DOI: 10.1177/1076029616651146.
40. Desborough M, Sandu R, Brunskill SJ, et al. Fresh frozen plasma for cardiovascular surgery. *Cochrane Database Syst Rev* 2015;(7):CD007614. DOI: 10.1002/14651858.CD007614.pub2.
41. Lee JW, Yoo YC, Park HK, et al. Fresh frozen plasma in pump priming for congenital heart surgery: Evaluation of effects on postoperative coagulation profiles using a fibrinogen assay and rotational thromboelastometry. *Yonsei Med J* 2013;54(3):752–762. DOI: 10.3349/ymj.2013.54.3.752.
42. Faraoni D, Meier J, New HV, et al. Patient blood management for neonates and children undergoing cardiac surgery: 2019 NATA Guidelines. *J Cardiothorac Vasc Anesth* 2019;33(12):3249–3263. DOI: 10.1053/j.jvca.2019.03.036.
43. Holcomb JB, Pati S. Optimal trauma resuscitation with plasma as the primary resuscitative fluid: the surgeon's perspective. *Hematol Am Soc Hematol Educ Program* 2013;2013:656–659. DOI: 10.1182/asheducation-2013.1.656
44. Patil V, Shetmahajan M. Massive transfusion and massive transfusion protocol. *Indian J Anaesth* 2014;58(5):590–595. DOI: 10.4103/0019-5049.144662.
45. Levi M, van der Poll T, Buller HR. Bidirectional relation between inflammation and coagulation. *Circulation* 2004;109(22):2698–2704. DOI: 10.1161/01.CIR.0000131660.51520.9A.
46. Kaur P, Basu S, Kaur G, et al. Transfusion protocol in trauma. *J Emerg Trauma Shock* 2011;4(1):103–108. DOI: 10.4103/0974-2700.76844.
47. Mumford AD, Ackroyd S, Alikhan R, et al. Guideline for the diagnosis and management of the rare coagulation disorders: A United Kingdom Haemophilia Centre Doctors' Organization guideline on behalf of the British Committee for Standards in Haematology. *Br J Haematol* 2014;167(3):304–326. DOI: 10.1111/bjh.13058.
48. Castaman G, Linari S. Diagnosis and treatment of von Willebrand disease and rare bleeding disorders. *J Clin Med* 2017;6(4): 45. DOI: 10.3390/jcm6040045.
49. Bray GL, Luban NL. Hemophilia presenting with intracranial hemorrhage. An approach to the infant with intracranial bleeding and coagulopathy. *Am J Dis Child* 1987;141(11):1215–1217. DOI: 10.1001/archpedi.1987.04460110085030.
50. Peyvandi F, Menegatti M. Treatment of rare factor deficiencies in 2016. *Hematology Am Soc Hematol Educ Program* 2016;2016(1):663–669. DOI: 10.1182/asheducation-2016.1.663.
51. Chalmers E, Williams M, Brennand J, et al. Guideline on the management of haemophilia in the fetus and neonate. *Br J Haematol* 2011; 154(2):208–215. DOI: 10.1111/j.1365-2141.2010.08545.x.
52. Jain S, Acharya SS. Management of rare coagulation disorders in 2018. *Transfus Apher Sci* 2018;57(6):705–712. DOI: 10.1016/j.transci.2018.10.009.
53. Go H, Ohto H, Nollet KE, et al. Risk factors and treatments for disseminated intravascular coagulation in neonates. *Ital J Pediatr* 2020;46(1):54. DOI: 10.1186/s13052-020-0815-7.
54. Pichler E, Pichler L. The neonatal coagulation system and the vitamin K deficiency bleeding – a mini review. *Wien Med Wochenschr* 2008; 158(13–14):385–395. DOI: 10.1007/s10354-008-0538-7
55. Rai RK, Luo J, Tulchinsky TH. Vitamin K supplementation to prevent hemorrhagic morbidity and mortality of newborns in India and China. *World J Pediatr* 2017;13(1):15–19. DOI: 10.1007/s12519-016-0062-6.
56. Sankar MJ, Chandrasekaran A, Kumar P, et al. Vitamin K prophylaxis for prevention of vitamin K deficiency bleeding: a systematic review. *J Perinatol* 2016;36(1):S29–35. DOI: 10.1038/jp.2016.30.
57. Bor O, Akgun N, Yakut A, et al. Late hemorrhagic disease of the newborn. *Pediatr Int* 2000;42(1):64–66. DOI: 10.1046/j.1442-200x.2000.01173.x.
58. Shearer MJ. Vitamin K deficiency bleeding (VKDB) in early infancy. *Blood Rev* 2009;23(2):49–59. DOI: 10.1016/j.blre.2008.06.001.
59. Shanmugam NP, Bansal S, Greenough A, et al. Neonatal liver failure: aetiologies and management—state of the art. *Eur J Pediatr*. May 2011;170(5):573–581. DOI: 10.1007/s00431-010-1309-1.
60. Cashen K, Meert K, Dalton H. Anticoagulation in neonatal ECMO: An enigma despite a lot of effort! *Front Pediatr* 2019;7:366. DOI: 10.3389/fped.2019.00366.
61. Chlebowski MM, Baltagi S, Carlson M, et al. Clinical controversies in anticoagulation monitoring and antithrombin supplementation for ECMO. *Crit Care* 2020;24(1):19. DOI: 10.1186/s13054-020-2726-9.
62. McMichael ABV, Zimmerman KO, Kumar KR, et al. Evaluation of effect of scheduled fresh frozen plasma on ECMO circuit life: A randomized pilot trial. *Transfusion* 2021;61(1):42–51. DOI: 10.1111/trf.16164.
63. Yuan S, Tsukahara E, De La Cruz K, et al. How we provide transfusion support for neonatal and pediatric patients on extracorporeal membrane oxygenation. *Transfusion* 2013;53(6):1157–1665. DOI: 10.1111/j.1537-2995.2012.03688.x.
64. Thayyil S, Milligan DW. Single versus double volume exchange transfusion in jaundiced newborn infants. *Cochrane Database Syst Rev* 2006;(4):CD004592. DOI: 10.1002/14651858.CD004592.pub2.
65. Deorari AK, Paul VK, Shreshta L, et al. Symptomatic neonatal polycythemia: comparison of partial exchange transfusion with saline versus plasma. *Indian Pediatr* 1995;32(11):1167–1171.
66. Roithmaier A, Arlettaz R, Bauer K, et al. Randomized controlled trial of Ringer solution versus serum for partial exchange transfusion in neonatal polycythaemia. *Eur J Pediatr*. Jan 1995;154(1):53–56. DOI: 10.1007/BF01972973.
67. Krishnan L, Rahim A. Neonatal polycythemia. *Indian J Pediatr* 1997; 64(4):541–546. DOI: 10.1007/BF02737765.
68. Dempsey EM, Barrington K. Short and long term outcomes following partial exchange transfusion in the polycythaemic newborn: a systematic review. *Arch Dis Child Fetal Neonatal Ed* 2006;91(1):F2–6. DOI: 10.1136/adc.2004.071431.
69. de Waal KA, Baerts W, Offringa M. Systematic review of the optimal fluid for dilutional exchange transfusion in neonatal polycythaemia. *Arch Dis Child Fetal Neonatal Ed* 2006;91(1):F7–F10. DOI: 10.1136/adc.2004.063925.
70. Dempsey EM, Barrington K. Crystalloid or colloid for partial exchange transfusion in neonatal polycythemia: a systematic review and meta-analysis. *Acta Paediatr* 2005;94(11):1650–1655. DOI: 10.1080/08035250500192748.
71. Pandey S, Vyas GN. Adverse effects of plasma transfusion. *Transfusion* 2012;52 Suppl 1:655–795. DOI: 10.1111/j.1537-2995.2012.03663.x.
72. Busch MP, Bloch EM, Kleinman S. Prevention of transfusion-transmitted infections. *Blood* 2019;133(17):1854–1864. DOI: 10.1182/blood-2018-11-833996.

# Congenital and Perinatal Varicella Infections

Srijan Singh<sup>1</sup>, Akash Sharma<sup>2</sup>, Mohammad Mozibur Rahman<sup>3</sup>, Gangajal Kasniya<sup>4</sup>, Akhil Maheshwari<sup>5</sup>, Suresh B Boppana<sup>6</sup>

Received on: 10 September 2022; Accepted on: 14 September 2022; Published on: 07 October 2022

## ABSTRACT

Varicella–zoster virus (VZV) is a human pathogen of the  $\alpha$ -herpesvirus family. Some fetuses infected in utero around 8–20 weeks of pregnancy show signs of congenital varicella syndrome (CVS). Infants born to mothers who develop varicella within 5 days before and 2 days after delivery can experience severe disease with increased mortality. The best diagnostic modality is polymerase chain reaction (PCR), which can be done using vesicular swabs or scrapings, scabs from crusted lesions, tissue from biopsy samples, and cerebrospinal fluid. The prevention and management of varicella infections include vaccination, anti-VZV immunoglobulin, and specific antiviral drugs. In this article, we have reviewed the characteristics of VZV, clinical manifestations, management of perinatal infections, and short- and long-term prognosis.

**Keywords:** Congenital varicella syndrome, Herpes zoster, Neonatal varicella, Postexposure prophylaxis, Varicella–zoster virus, Vesicular rash, Varicella zoster immunoglobulin.

*Newborn* (2022): 10.5005/jp-journals-11002-0040

## INTRODUCTION

The VZV, an  $\alpha$ -herpes virus, is an exclusively human pathogen.<sup>1</sup> There is no animal reservoir, and so all transmission occurs from infected patients to other susceptible subjects. The primary cellular targets are epithelial cells, T-lymphocytes, and ganglion cells. In neonates, the initial infection in the upper respiratory epithelial cells is followed by viremia. These circulating viruses will disseminate to diverse locations in the skin and after an incubation period of 10–21 days, a vesicular rash develops **Figure 1A** shows the surface and side dissection of VZV, and its cross-section is shown in **Figure 1B**.<sup>2</sup> Some of these circulating virions enter axon terminals in sensory neurons and reach the nerve cell bodies in ganglia through retrograde transport, where these establish a latent infection.<sup>3</sup> The skin lesions contain high viral concentrations that can be transmitted to susceptible individuals.<sup>4</sup>

## EPIDEMIOLOGY

Neonatal varicella is most often acquired from maternal infections occurring during the last 3 weeks of pregnancy.<sup>5</sup> Nosocomial acquisition of VZV can also occur in newborn infants.

<sup>1</sup>Department of Paediatrics, Grant Government Medical College and Sir JJ Hospitals, Mumbai, Maharashtra, India

<sup>2</sup>Department of Pediatrics, Sir Padampat Institute of Neonatal and Pediatric Health (SPINPH), SMS Medical College, Jaipur, Rajasthan, India

<sup>3</sup>Institute of Child and Mother Health (ICMH), Dhaka, Bangladesh

<sup>4</sup>Mount Sinai Hospital, Chicago, Illinois, United States of America

<sup>5</sup>Global Newborn Society, Clarksville, Maryland, United States of America

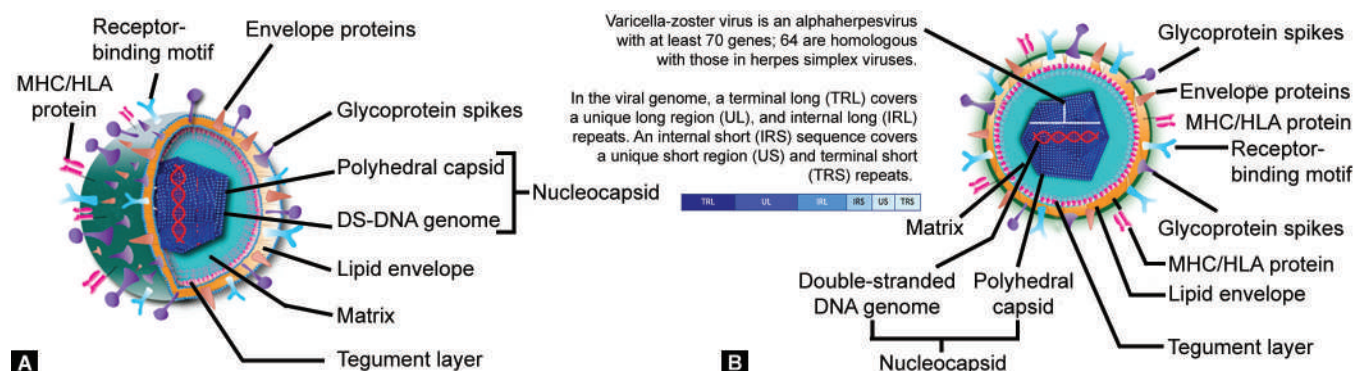
<sup>6</sup>Department of Pediatrics, University of Alabama at Birmingham, Birmingham, Alabama, United States of America

**Corresponding Author:** Srijan Singh, Department of Paediatrics, Grant Government Medical College and Sir JJ Hospitals, Mumbai, Maharashtra, India, Phone: +91 9953537342, e-mail: srijanstar89@gmail.com

**How to cite this article:** Singh S, Sharma A, Rahman MM, *et al.* Congenital and Perinatal Varicella Infections. *Newborn* 2022;1(3): 278–286.

**Source of support:** U01CA260462 to SB

**Conflict of interest:** None



**Figs 1A and B:** Schematic diagrams showing (A) Surface and side dissection and (B) Cross-section of the varicella–zoster virus

The incidence of varicella has been estimated to be 0.1–0.7/1,000 pregnancies.<sup>6</sup> VZV infections show age-related, seasonal, and geographic variations. The seasonality is most noticeable in temperate climates, peaking in late winter or spring. Infections are seen most frequently in pre-school (1–4 years) or early elementary school-aged (5–9 years) children; the annual incidence reached 100 per 1,000 children prior to the implementation of the varicella vaccination program. In tropical climates, the virus is usually acquired at later ages.<sup>7</sup> Skin cells shed during acute infections are probably the major source of the infectious airborne virus. Infected children without skin lesions are not contagious to others.

## VIRAL STRUCTURE

The VZV is an  $\alpha$ -herpesvirus with a double-stranded DNA (dsDNA) genome encased in an icosahedral capsid measuring approximately 125 nm in diameter.<sup>1</sup> The capsid is comprised of particles in A-, B-, and C- maturational states. The A-particles are empty protein shells formed during abortive DNA packaging, B- contain a proteinaceous core of scaffold proteins, and C- are matured particles containing a DNA genome.<sup>8</sup> The nucleocapsid is surrounded by a trilaminar lipoprotein envelope derived from the nuclear membrane of the infected host cell. The enveloped particle is spherical to pleomorphic in shape, about 180–200-nm diameter. Projecting from the lipid envelope are about 8-nm long viral glycoprotein spikes that bind specific host receptors to facilitate virus entry.<sup>9</sup> In mature virus particles, an amorphous proteinaceous layer, the tegument, is seen covering the capsid and underneath the lipid envelope.<sup>10</sup> The tegument consists of enzymes such as VP16 (described below) which recruits cellular proteins and enzymes into viral nucleic acid replication and the synthesis of the VHS (virion host shutoff) protein which shuts off the synthesis of host cell proteins in the cytoplasm. Detailed information is available for some of the viral components (Table 1).<sup>8–15</sup>

We do not have a consensus nomenclature for viral strains. Most studies use one of the four classification systems, but these seemingly similar nomenclature schemes do not correlate between methods.

- Whole genome sequence/phylogenetic analyses have identified 22 strains of VZV.<sup>16</sup> Some strains are seen more frequently, such as the European strains E1 and E2; the Japanese strain J; the Eastern Australian strains E1 and E2; and the mosaics M1 and M2.<sup>17</sup> Single nucleotide polymorphism (SNP) analysis of whole-genome alignments shows two patterns of variation, one in the open reading frame 22 (ORF22), and the other involving ORF21 and ORF50.

Variations in the ORF22 are particularly notable in various strains of VZV. Initial attempts identified the following three major genotypes: A, B, and C; strains A in parts of Africa and Asia, genotypes B and C were found primarily in Europe, and genotype J was subsequently added to accommodate Japanese strains.<sup>18,19</sup> Genotype B strains were presumed to have arisen from recombination between types A and C viruses. The M group were mosaics, and these strains were later subdivided into distinct M1 and M2 (and possibly M3 and M4) genotypes.

The reasons for the geographic diversity of infections among VZV strains are unclear; climatic factors and immigration patterns may be involved. A study in 18 European countries that included 342 clinical specimens showed E1 in 221 (65%); E2 in 87 (25%); M1 in 20 (6%); M2 in 3 (1%); and M4 in 11 (3%). No M3 or J strains were

observed.<sup>20</sup> The strain diversity may be broader in eastern parts of Australia than in Europe, Africa, and North America. Similarly, Japanese strains may differ considerably from those seen in the United States of America (USA), United Kingdom (UK), Europe, and eastern Australia isolates. Isolates from tropical Africa, India, Bangladesh, China, Central America, and northern Australia also seem to be distinct.<sup>21</sup>

- Genome sequences of the five glycoprotein genes (gH, gI, gL, gB, and gE) and the major transactivator gene that encodes for the immediate-early *protein 62* (IE62) have identified three sub-categories, designated A, B, and C.<sup>22</sup>
- Linear VZV genomes were differentiated based on the packing proteins that form the icosahedral nucleocapsid core, namely, that *orf20*, *orf21*, *orf23*, *orf33*, *orf38*, *orf40*, *orf41* and *orf54*.<sup>23</sup>
- Finally, in a study using complete genome sequence information, VZV was segregated into the following four genotypes: A, B, C, and D. The VZV strains circulating in Japan, Iceland, and The Netherlands have similarities, whereas genotypes circulating in different regions of the US, Thailand, Singapore, and Japan were diverse. This approach defined four distinct genotypes that were also arbitrarily designated A, B, C, and D. Viral isolates from Singapore and Japan were labeled as genotypes B and C, and those from Western Europe and the US as genotypes A and D.<sup>16</sup>

## CLINICAL PRESENTATIONS

### Intrauterine VZV Infection

Infection of the fetus following maternal varicella during the first and the early second trimester can occasionally lead to fetal death or varicella embryopathy that can include cutaneous scarring, limb hypoplasia, eye and central nervous system (CNS) abnormalities (CVS).<sup>24,25</sup> Severe CVS with extensive skin lesions and multisystem disease is shown in Figure 2A and perinatal CVS is shown in Figure 2B. Also shown are postnatal varicella with mild (Fig. 2C) and limited (Fig. 2D) cutaneous lesions.

In 1947, CVS was first described by Laforet and Lynch.<sup>24</sup> The frequency of CVS is very low (0.4%).<sup>26</sup> When the maternal infection occurs between 8 and 20 weeks of gestation, CVS is seen in approximately 2% of fetuses.<sup>27</sup> Although it is thought that maternal viremia in primary maternal varicella infections leads to placental infection and subsequent fetal infection, it is also possible that reactivation of VZV *in utero* can lead to CVS.<sup>28</sup>

The clinical features of CVS in affected infants include the following:

- Intrauterine growth restriction;
- Cicatricial (scarring) skin lesions, which may show localized depression and pigmentation in a dermatomal distribution;
- Ocular defects, such as cataracts, chorioretinitis, Horner syndrome, microphthalmos, and nystagmus;
- Limb abnormalities, such as localized hypoplasia of bone and muscle; and
- The CNS abnormalities, such as cortical atrophy, seizures, and intellectual disability.

Acute and recurrent VZV infections are frequently accompanied by robust innate and acquired immune responses. Innate immune cells in skin and ganglion secrete type I interferon (IFN-I) and proinflammatory cytokines to control VZV. In the postneonatal period, VZV infections subvert the pattern recognition receptor

**Table 1:** We have used a standardized table developed to describe viral pathogens. Major structural components of enteroviruses have been listed

| <i>Structure</i>              | <i>Available information</i>  |
|-------------------------------|---|
| Lipid envelope                | A trilaminar lipoprotein envelope derived from the nuclear membrane of the infected host cell covers the nucleocapsid. <sup>9</sup>   |
| Glycoproteins                 | About 8 nm long viral glycoprotein spikes project from the lipid envelope; bind specific host receptors to facilitate virus entry. <sup>9</sup>   |
| Receptor binding motifs       | Involved in virion attachment to cell surface receptors. Motif binds integrins to promote entry into the cells. <sup>11</sup>   |
| Envelope protein              | A trilaminar lipoprotein envelope containing envelope proteins (as mentioned above). <sup>9</sup>   |
| Membrane protein              | Either not expressed or relevance unclear in fetal/infantile disease.   |
| MHC or HLA Proteins           | During primary VZV infection, both MHC I-restricted, CD8 <sup>+</sup> T lymphocytes and MHC II-restricted, CD4 <sup>+</sup> T lymphocytes are sensitized to VZV antigens. <sup>12</sup>   |
| Spike protein                 | About 8 nm long viral glycoprotein spikes project from the lipid envelope; bind specific host receptors to facilitate virus entry. <sup>9</sup>   |
| Surface tubules               | Either not expressed or relevance unclear in fetal/infantile disease.   |
| Palisade layer                | Either not expressed or relevance unclear in fetal/infantile disease.   |
| Viral tegument                | In mature virus particles, an amorphous proteinaceous layer, the tegument, is seen covering the capsid and is underneath the lipid envelope. <sup>10</sup> The tegument consists of enzymes such as VP16 (described below), which recruits cellular proteins and enzymes into viral nucleic acid replication and in the synthesis of the VHS (virion host shutoff) protein that shuts off the synthesis of host cell proteins in the cytoplasm. |
| Lateral bodies                | Either not expressed or relevance unclear in fetal/infantile disease.   |
| Capsid                        | The capsid is comprised of particles in A-, B-, and C- maturational states. A-particles are empty protein shells formed during abortive DNA packaging, B- contain a proteinaceous core of scaffold proteins, and the C- are matured particles containing a DNA genome. <sup>8</sup>   |
| Capsomeres                    | VZV open reading frame 23 (ORF23) encodes a conserved capsid protein, referred to as VP26 (UL35). <sup>8</sup>  |
| Core membrane                 | Either not expressed or relevance unclear in fetal/infantile disease.   |
| Protein core                  | Details on genome-associated polyprotein described below.   |
| Core fibrils                  | Either not expressed or relevance unclear in fetal/infantile disease.   |
| Matrix                        | Virions penetrating the cell surface get uncoated and the viral genome functions as mRNA for the viral polyprotein. <sup>9</sup>  |
| Enzymes                       | Details scant. Alter the expression of host enzymes. <sup>14</sup>  |
| RNA elements                  | No RNA genome exists.   |
| Nucleus                       | Either not expressed or relevance unclear in fetal/infantile disease.   |
| Nucleosome                    | Either not expressed or relevance unclear in fetal/infantile disease.   |
| DNA                           | Double-stranded DNA genome exists. <sup>8</sup>   |
| RNA                           | No RNA genome exists.   |
| Genome-associated polyprotein | Either not expressed or relevance unclear in fetal/infantile disease.   |
| DNA polymerase                | VZV induces a DNA polymerase similar to that seen in other herpesviruses. Functions as a replicase for viral DNA synthesis in infected cells. <sup>15</sup>   |
| Reverse transcriptase         | Either not expressed or relevance unclear in fetal/infantile disease.   |
| Head                          | Either not expressed or relevance unclear in fetal/infantile disease.   |
| Base plate                    | Either not expressed or relevance unclear in fetal/infantile disease.   |
| Integrase                     | Either not expressed or relevance unclear in fetal/infantile disease.   |
| Tail                          | Either not expressed or relevance unclear in fetal/infantile disease.   |
| Tail fiber                    | Either not expressed or relevance unclear in fetal/infantile disease.   |
| Neck                          | Either not expressed or relevance unclear in fetal/infantile disease.   |

HLA, human leukocyte antigen; MHC, major histocompatibility complex

sensing to modulate antigen presentation and IFN-I production. During primary infections, VZV can promote the accumulation of T-cells in skin lesions and consequent retrograde movement into the axons and ganglia. T- and B-cell memory formed within a few weeks of infection is boosted by reactivation or re-exposure.<sup>26</sup> We could not find a strain-based propensity for varicella viruses affecting pregnant women.

### Diagnosis of CVS

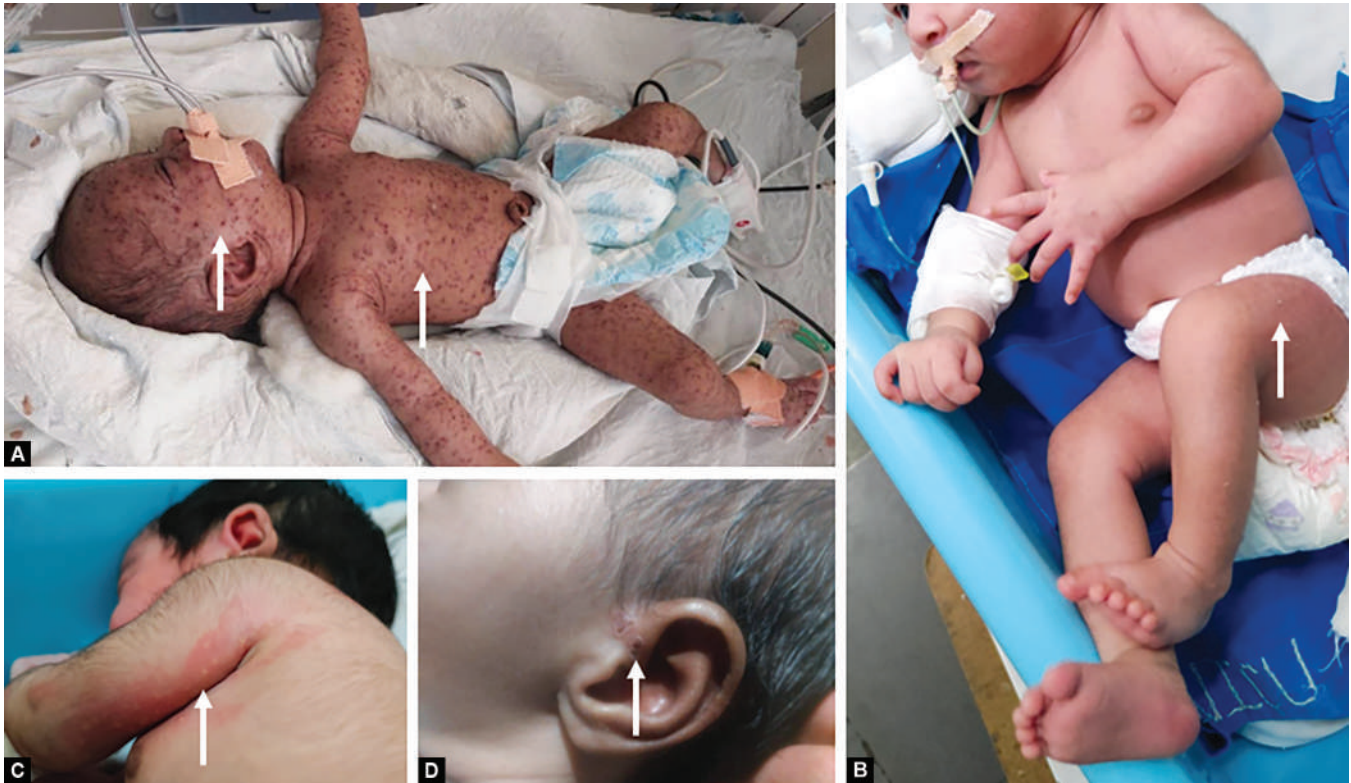The clinical manifestations of CVS are enumerated in [Table 2](#).<sup>29</sup> The diagnostic criteria for CVS are shown in [Table 3](#).<sup>30–32</sup>

### Neonatal Varicella

The appearance of symptoms within the first 10 days after life most likely indicates a prenatal infection because of the 10–20







**Figs 2A to D:** Erythematous vesicular lesions in neonatal varicella (arrows). (A) Severe CVS with extensive skin lesions and multisystem disease. Lung involvement necessitated respiratory support; (B) Perinatal CVS. The infant had feeding difficulties; (C) and (D) Postnatal varicella with mild, limited cutaneous lesions

**Table 2:** Clinical manifestations of CVS

| <i>Skin</i>         | <i>Nervous system</i>         | <i>Eye</i>      | <i>Musculoskeletal</i> | <i>Systemic</i>                 | <i>Gastrointestinal tract</i> | <i>Urinary tract</i>         |
|---------------------|-------------------------------|-----------------|------------------------|---------------------------------|-------------------------------|------------------------------|
| Cicatricial lesions | Intrauterine encephalitis     | Chorioretinitis | Limb hypoplasia        | Intrauterine growth retardation | Gastrointestinal reflux       | Hydrourter                   |
| Cutaneous defects   | Cortical atrophy/porencephaly | Cataracts       | Muscle hypoplasia      | Developmental delay             |                               | Hydronephrosis <sup>29</sup> |
| Hypopigmentation    | Seizures                      | Microphthalmia  |                        | Cardiovascular defects          |                               |                              |
|                     | Mental retardation            | Anisocoria      |                        |                                 |                               |                              |
|                     | Autonomic instability         |                 |                        |                                 |                               |                              |

**Table 3:** Diagnostic criteria of CVS

| <i>S.no.</i> | <i>Diagnostic criteria of CVS</i>  |
|--------------|--|
| 1.           | Appearance of maternal chickenpox during pregnancy   |
| 2.           | Presence of congenital skin lesions in dermatomal distribution and/or neurologic defects, eye disease, limb hypoplasia |
| 3.           | Evidence of intrauterine VZV infection by detection of viral DNA in the infant   |
| 4.           | Presence of specific IgM   |
| 5.           | Persistence of IgG beyond 7 months of age  |
| 6.           | Appearance of zoster during early infancy  |

days incubation period.<sup>33</sup> The highest risk for severe neonatal varicella is seen when the maternal VZV infection occurs between 5 days before and 2 days after delivery. These infants are typically

exposed to high viral loads but have not had the opportunity to acquire maternal protective antibodies. Between 20 and 50% of these infants develop the life-threatening disseminated disease between postnatal days 5–10 and unless treated aggressively, can have case–fatality rates of up to 20%. Nosocomial acquisition of VZV also can occur. Newborns born to mothers who are exposed to VZV or have clinical disease manifestations within the first 2 weeks after birth are at the highest risk of developing symptomatic disease.

Symptoms appearing after postnatal day 13 are more likely to be due to postnatal acquisition of the virus. Although most infants with neonatal varicella have mild disease, some can develop a serious illness with a mortality rate of up to 30%.<sup>34,35</sup> However, postnatally acquired varicella that occurs between 10 and 28 days after birth usually causes mild disease.<sup>36</sup>

The immunological immaturity of neonates places them at higher risk of developing the relatively severe disease compared

to older infants or children.<sup>37</sup> Premature infants are at even higher risk for nosocomial acquisition of VZV compared with infants born at term because the active transfer of maternal immunoglobulin G (IgG) antibodies occurs primarily during the third trimester of pregnancy.<sup>38</sup> In these infants, the risk may increase with increasing postnatal age because the antibody levels decline with age.<sup>39,40</sup>

Neonatal varicella may present with fever occurring within the first 5–10 days of life, followed by a generalized vesicular eruption. The rash starts as macules and rapidly progresses to papules and then to characteristic vesicular lesions before crusting. These lesions may be noted first on the head and then on other parts of the body. The lesions may be seen in various stages of development and healing.<sup>41</sup> The generalized distribution and appearance of lesions in different stages of development distinguish varicella from the vesicular rash seen in neonatal herpes simplex virus (HSV), which tends to occur in localized clusters. In mild cases of neonatal varicella, the lesions heal within 7–10 days. Very rarely, infants develop disseminated disease with varicella pneumonia, hepatitis, and meningoencephalitis.

### Laboratory Diagnosis

The diagnosis of CVS can be accomplished by analyzing amniotic fluid or fetal blood for VZV DNA using the PCR assay together with prenatal ultrasound to detect fetal abnormalities such as limb deformity, microcephaly, hydrocephalus, polyhydramnios, soft tissue calcification and intrauterine growth restriction.<sup>31</sup> The PCR assay for detecting VZV DNA is highly sensitive.<sup>42–44</sup> However, amniocentesis can be usually performed after 16–18 weeks of gestation because of the risk of complications. A normal fetal ultrasound and a negative PCR performed between 17 and 21 weeks of gestation suggests low risk of CVS. The ultrasound imaging should be performed at least 5 weeks after maternal infection to detect fetal abnormalities consistent with CVS.<sup>30</sup>

### Treatment and Prevention of CVS

Prevention and treatment of CVS are comprised of vaccination, antiviral agents and varicella zoster immunoglobulin (VZIG).<sup>30</sup> A brief discussion of each strategy is provided below.

VZV vaccine is a live attenuated varicella vaccine is currently included on the World Health Organization's list of "Essential Medicines for Children." The VZV vaccine is routinely administered during early childhood in several countries including the USA, Canada, Japan, Australia, Brazil and few other European and Middle Eastern countries. Two doses of VZV vaccine in children has been shown to 98% effective in preventing severe disease. However, many of the developing countries and a few developed countries such as the UK have not recommended routine vaccination of all children.

Since the VZV vaccine is not secreted in breast milk, non-immune women should be vaccinated immediately after delivery.<sup>45</sup> In most developing countries, immunity to varicella usually results from natural infection and only 3.9% of adults are non-immune.<sup>46</sup> The VZV vaccination can prevent infection of the mother and fetus and reduce the incidence of both CVS and neonatal chickenpox.<sup>46</sup> If a pregnant woman has had significant exposure to such as household contact with a varicella within the infectious period, sero-status of the exposed individual should be evaluated. In women who have received varicella vaccine, the risk for maternal varicella and CVS are very low.<sup>47</sup> Nonimmune women could receive postexposure prophylaxis immediately.

It is unclear whether antiviral drugs such as acyclovir are effective in reducing the risk of varicella during pregnancy after exposure. Antiviral treatment is indicated for pregnant women with varicella infection.<sup>48–50</sup> However, in early pregnancy, the fetal benefit is controversial.<sup>51</sup> In women with complicated varicella infections such as varicella pneumonia, treatment with IV acyclovir is recommended because of the high mortality rate.<sup>52</sup>

### Management of Pregnant Women Exposed to VZV

Significant exposure such as household contact with varicella infection during pregnancy warrants passive immunization with VZV-specific antibodies to reduce the risk of varicella infection and also to prevent severe disease. Moreover, VZIG is prepared from individuals with recent zoster or from donors screened for high VZV IgG titers. It is a purified human immune globulin preparation made from plasma containing high levels of antiviral antibodies,<sup>53</sup> and is recommended both for women who are exposed and for others who are susceptible to infection with the virus.<sup>54,55</sup> Also, VZIG can prevent maternal disease and complications,<sup>56</sup> and can reduce the risk of fetal infection.<sup>57</sup> It should be administered within 96 hours of chickenpox exposure.<sup>56</sup> However, Varizig is the only preparation available in the US and VZIG has been discontinued. If VZIG or Varizig is not available, intravenous immunoglobulin (IVIG) can be considered, if necessary, at a dose of 400 mg/kg. The recommended dose is 125 units/10 kg of body weight, up to a maximum of 625 units.<sup>33</sup>

The overall risk for CVS is very low and pregnant women affected by varicella during pregnancy should be reassured. This reassurance could lead to a reduced frequency of pregnancy terminations performed because of the risk of congenital anomalies.<sup>58</sup>

### Herpes Zoster in Infancy

Maternal varicella during pregnancy can manifest as an infant zoster in the first or second year of life. The majority of infants who present with herpes zoster early in life do not have malformations and are asymptomatic.<sup>59</sup> Enders et al. estimated the risk of developing herpes zoster in children with maternal varicella infection between the 13th and 36th week of gestation. They noted that 0.8–1.7% of these infants may develop herpes zoster during the first 2 years of life.<sup>60</sup>

### Diagnosis

Neonatal varicella can be suspected based on the characteristic appearance of generalized vesicular skin lesions in various stages of development and healing in an infant born to a mother exposed to VZV or with clinical symptoms close to the time of delivery.

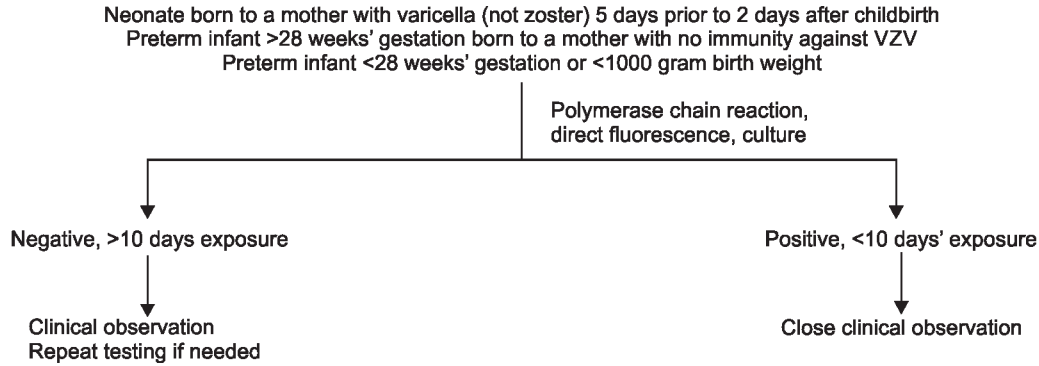
### Laboratory Diagnosis

In infants with uncertain and/or severe clinical manifestations, PCR of swabs from vesicles or other samples for the detection of VZV DNA confirms the diagnosis. Using PCR, it may be possible to distinguish between wild type VZV and vaccine strains. Direct fluorescent antibody (DFA) on scrapings from active vesicular skin lesions can provide a rapid diagnosis.

The sensitivity of viral culture is significantly lower compared with PCow. Serologic testing by examining cord blood for VZV IgM antibodies can also help establish the diagnosis. However, this approach requires acute and convalescent titers and therefore it is not helpful for rapidly establishing the diagnosis. In neonatal varicella infection, acute and convalescent sera demonstrate a rise in VZV IgG titers. In uninfected neonates who received the passive



**Flowchart 1:** Schematic flowchart showing recommendations for clinical investigation and management of infants with varicella infections



CDC recommends two doses of varicella/chickenpox vaccine for children, adolescents, and adults who have not had the disease. Children should receive 2 doses of the vaccine - the first dose at 12–15 months old and a second dose at 4–6 years old.

Individuals who do not have a history of varicella/chickenpox should receive the chickenpox vaccine. Adults in maternal age can get it at any time; should receive 2 doses at least 28 days apart if they have never had varicella.

VZIG 125 units/10 kg (62.5 units if <2 kg, up to a maximum of 625 units).

If VZIG not available, administer IVIG 400 mg/kg

If signs of systemic involvement such as with pneumonia, encephalitis, thrombocytopenia, and/or severe hepatitis, treat with intravenous acyclovir (30 mg/kg per day in 3 divided doses) for 10 days

transfer of maternal antibodies during pregnancy typically have low acute VZV titers and convalescent titers remain low. Moreover, VZV IgM is insensitive in neonates and false positives can occur.

The role of other diagnostic tests, including fluorescent antimembrane antibody (FAMA), latex agglutination (LA), enzyme-linked immunosorbent assay (ELISA), and complement-enhanced neutralization, is not known in neonates.

## CLINICAL MANAGEMENT

### Prophylaxis

Management of newborn infants who are exposed to VZV by maternal infection or contact with affected individuals includes isolation and postexposure prophylaxis. The specific intervention depends upon the timing of exposure, the mother's serologic status, and gestational age.

Prompt postexposure administration of VZIG or Varizig can prevent varicella in exposed neonates or ameliorate the disease course in patients in whom the infection was not fully prevented.<sup>61</sup> The American Academy of Pediatrics (AAP), Centers for Disease Control and Prevention (CDC), and the Advisory Committee on Immunization Practices (ACIP), recommend administration of Varizig to neonates who have had a significant exposure to VZV plus one or more of the following:<sup>62</sup>

- Maternal symptoms – Neonates whose mothers have signs and symptoms of varicella around the time of delivery (within 5 days before or 2 days after) should receive Variizig or VZIG.
- Preterm infants above or equal to 28 weeks of gestation – Hospitalized preterm infants born at  $\geq 28$  weeks of gestation who had significant exposure to VZV and whose mothers do not have documented immunization, serologic immunity, or prior documented history of varicella infection should receive Variizig or VZIG (Flowchart 1).
- Preterm infants less than 28 weeks of gestation – Hospitalized premature infants born at less than 28 weeks of gestation or who weigh less than 1,000 gm at birth who have had significant

exposure to VZV should receive VZIG or Varizig regardless of maternal history of varicella or vaccination.

Healthy term neonates who are exposed to VZV postnatally (including infants whose mother's rash developed 48 hours after delivery) do not require postexposure prophylaxis. This is because postnatally acquired varicella that occurs beyond the immediate newborn period in a term infant generally is mild.<sup>63</sup> Also, VZIG is given intramuscularly at a dose is 125 units to neonates weighing above 2.1–10 kg and 62.5 units to children weighing below or equal to 2 kg.

For postexposure prophylaxis, passive immunization with VZIG or Vaizic should be offered as soon as possible and within 10 days.<sup>64</sup> If VZIG or Varizig is unavailable, IVIG or prophylaxis with acyclovir can be considered.<sup>41</sup>

### Isolation

Isolation for the mother and infant depends upon whether there is active disease and the timing of exposure. Patients who require isolation include the following:

- Active disease – A mother with active VZV lesions must be isolated. The infant is isolated from the mother until she is not infectious. Any infant who develops varicella in the nursery or neonatal intensive care unit (NICU) is also isolated.
- Maternal exposure during the period of 6–21 days before hospitalization – A seronegative mother exposed to VZV 6–21 days before hospital admission should be isolated from other patients and the nursery because she may develop varicella while hospitalized. This calculation takes into account the incubation period of varicella which is usually 14–16 days but sometimes ranges from 10 to 21 days after exposure.<sup>63</sup> The incubation may be prolonged for as long as 28 days after receipt of VZIG or IVIG, and it may be shortened in immunocompromised patients. Her infant, if born at term, should be isolated from the mother. The mother and infant should be cared for only by staff with immunity to VZV. Both should be discharged as soon as possible.

Patients who generally do not require isolation include the following:

- Active disease 21 days before delivery – A mother who has active varicella within 21 days of delivery that resolves before hospitalization does not need to be isolated. However, the newborn should stay in the mother's room and be isolated from other infants.
- Maternal exposure within 6 days of hospitalization – If a seronegative mother was exposed within 6 days of admission and discharged before 48 hours, isolation is not needed, because varicella would not be expected to develop during the hospital stay.

### Nursery Exposure

An infant who develops varicella in the nursery or NICU should be isolated. The more common situation is nursery exposure by a visitor or hospital worker who is infectious. In the newborn nursery, exposed infants typically are discharged before they would be infectious.

### Neonatal Intensive Care Unit Exposure

Exposed infants in the NICU usually are made as cohorts. They are isolated from new patients admitted between 8 and 21 days after exposure.<sup>48</sup> Infants who received VZIG should be isolated from new patients for 28 days.

## TREATMENT

### Acyclovir

Newborns with severe disseminated VZV infection, such as with pneumonia, encephalitis, thrombocytopenia, and/or severe hepatitis are treated with intravenous acyclovir (30 mg/kg per day in 3 divided doses) for 10 days.<sup>63,65</sup> Antiviral treatment must be started as soon as possible after the onset of symptoms because most viral replication has stopped 72 hours after the appearance of the rash.<sup>66,67</sup> Similar to immunocompromised patients, neonates with disseminated VZV are also at increased risk of severe morbidity and higher mortality compared with older immunocompetent patients.

### Breastfeeding

Whether VZV is secreted in human milk is uncertain, although VZV DNA has been detected.<sup>68</sup> However, the transmission of VZV from breast milk is very rare, and therefore breastfeeding is encouraged in infants of mothers infected with varicella. In addition to the known benefits of breastfeeding on the overall health of the infant, breast milk contains antiviral antibodies that may provide protection.<sup>69</sup>

## OUTCOMES

The severity of neonatal varicella that was acquired *in utero* is closely related to the timing of maternal infection as transplacentally-transmitted antibodies may reduce the severity of symptoms in the newborn. The risk of disseminated neonatal varicella is more likely (20%-50%) with significant mortality (~20%) if mothers develop the varicella rash between 5 days before and 2 days after delivery.<sup>6</sup>

## ORCID

Srijan Singh  <https://orcid.org/0000-0002-2103-5232>

Akash Sharma  <https://orcid.org/0000-0003-1045-4367>

Akhil Maheshwari  <https://orcid.org/0000-0003-3613-4054>

## REFERENCES

1. Pergam SA, Limaye AP, AST Infectious Diseases Community of Practice. Varicella-zoster virus (VZV) in solid organ transplant recipients. *Am J Transplant* 2009;9(Suppl. 4):S108–S115. DOI: 10.1111/j.1600-6143.2009.02901.x.
2. Ku CC, Zerboni L, Ito H, et al. Varicella-zoster virus transfer to skin by T cells and modulation of viral replication by epidermal cell interferon- $\alpha$ . *J Exp Med* 2004;200(7):917–925. DOI: 10.1084/jem.20040634.
3. Gilden DH, Vafai A, Shtram Y, et al. Varicella-zoster virus DNA in human sensory ganglia. *Nature* 1983;306(5942):478–480. DOI: 10.1038/306478a0.
4. Zerboni L, Sen N, Oliver SL, et al. Molecular mechanisms of varicella-zoster virus pathogenesis. *Nat Rev Microbiol* 2014;12(3):197–210. DOI: 10.1038/nrmicro3215.
5. Chapman SJ. Varicella in pregnancy. *Seminars perinatol* 1998;22(4):339–346. DOI: 10.1016/s0146-0005(98)80023-2.
6. Sauerbrei A, Wutzler P. Neonatal varicella. *J Perinatol* 2001;21(8):545–549. DOI: 10.1038/sj.jp.7210599.
7. Laing KJ, Ouwendijk WJD, Koelle DM, et al. Immunobiology of varicella-zoster virus infection. *J Infect Dis* 2018;218(Suppl. 2):S68–S74. DOI: 10.1093/infdis/jiy403.
8. Sun J, Liu C, Peng R, et al. Cryo-EM structure of the varicella-zoster virus A-capsid. *Nat Commun* 2020;11(1):4795. DOI: 10.1038/s41467-020-18537-y.
9. Edson CM, Hosler BA, Poodry CA, et al. Varicella-zoster virus envelope glycoproteins: biochemical characterization and identification in clinical material. *Virology* 1985;145(1):62–71. DOI: 10.1016/0042-6822(85)90201-6.
10. Wang W, Cheng T, Zhu H, et al. Insights into the function of tegument proteins from the varicella-zoster virus. *Sci China Life Sci* 2015;58(8):739–749. DOI: 10.1007/s11427-015-4887-3.
11. Li Q, Krogmann T, Ali MA, et al. The amino terminus of varicella-zoster virus (VZV) glycoprotein E is required for binding to insulin-degrading enzyme, a VZV receptor. *J Virol* 2007;81(16):8525–8532. DOI: 10.1128/JVI.00286-07.
12. Abendroth A, Lin I, Slobedman B, et al. Varicella-zoster virus retains major histocompatibility complex class I proteins in the Golgi compartment of infected cells. *J Virol* 2001;75(10):4878–4888. DOI: 10.1128/JVI.75.10.4878-4888.2001.
13. Visalli MA, House BL, Selariu A, et al. The varicella-zoster virus portal protein is essential for cleavage and packaging of viral DNA. *J Virol* 2014;88(14):7973–7986.
14. Hew K, Dahlroth SL, Veerappan S, et al. Structure of the varicella-zoster virus thymidylate synthase establishes functional and structural similarities as the human enzyme and potentiates itself as a target of brivudine. *PLoS One* 2015;10(12):e0143947. DOI: 10.1371/journal.pone.0143947.
15. Meier JL, Straus SE. Varicella-zoster virus DNA polymerase and major DNA-binding protein genes have overlapping divergent promoters. *J Virol* 1993;67(12):7573–7581. DOI: 10.1128/JVI.67.12.7573-7581.1993.
16. Loparev VN, Rubtcova EN, Bostik V, et al. Identification of five major and two minor genotypes of varicella-zoster virus strains: A practical two-amplicon approach used to genotype clinical isolates in Australia and New Zealand. *J Virol* 2007;81(23):12758–12765. DOI: 10.1128/JVI.01145-07.
17. Loparev V, Martro E, Rubtcova E, et al. Toward universal varicella-zoster virus (VZV) genotyping: Diversity of VZV strains from France and Spain. *J Clin Microbiol* 2007;45(2):559–563. DOI: 10.1186/s12879-016-1863-x.
18. Quinlivan M, Hawrami K, Barrett-Muir W, et al. The molecular epidemiology of varicella-zoster virus: Evidence for geographic segregation. *J Infect Dis* 2002;186(7):888–894. DOI: 10.1086/344228.
19. Muir WB, Nichols R, Breuer J. Phylogenetic analysis of varicella-zoster virus: evidence of intercontinental spread of genotypes and recombination. *J Virol* 2002;76(4):1971–1979. DOI: 10.1128/jvi.76.4.1971-1979.2002.



20. Loparev VN, Rubtcova EN, Bostik V, et al. Distribution of varicella-zoster virus (VZV) wild-type genotypes in northern and southern Europe: Evidence for high conservation of circulating genotypes. *Virology* 2009;383(2):216–225. DOI: 10.1016/j.virol.2008.10.026.
21. Loparev VN, Gonzalez A, Deleon-Carnes M, et al. Global identification of three major genotypes of varicella-zoster virus: Longitudinal clustering and strategies for genotyping. *J Virol* 2004;78(15):8349–8358. DOI: 10.1128/JVI.78.15.8349-8358.2004.
22. Moffat J, Ku CC, Zerboni L, et al. VZV: Pathogenesis and the disease consequences of primary infection. In: Arvin A, Campadelli-Fiume G, Mocarski E, Moore PS, et al, editors. *Human Herpesviruses: Biology, Therapy, and Immunoprophylaxis*. Cambridge: Cambridge University Press; 2007, Chapter 37.
23. Zerboni L, Sen N, Oliver SL, et al. Molecular mechanisms of varicella-zoster virus pathogenesis. *Nat Rev Microbiol* 2014;12(3):197–210. DOI: 10.1038/nrmicro3215.
24. Laforet EG, Lynch CL Jr. Multiple congenital defects following maternal varicella: Report of a case. *N Engl J Med* 1947;236(15):534–537. DOI: 10.1056/NEJM194704102361504.
25. Pastuszak AL, Levy M, Schick B, et al. Outcome after maternal varicella infection in the first 20 weeks of pregnancy. *N Engl J Med* 1994;330(13):901–905. DOI: 10.1056/NEJM199403313301305.
26. Gershon AA, Breuer J, Cohen JI, et al. Varicella-zoster virus infection. *Nat Rev Dis Primers* 2015;1:15016. DOI: 10.1038/nrdp.2015.16.
27. Kett JC. Perinatal varicella. *Pediatr Rev* 2013;34(1):49–51. DOI: 10.1542/pir.34-1-49.
28. Higa K, Dan K, Manabe H. Varicella-zoster virus infections during pregnancy: Hypothesis concerning the mechanisms of congenital malformations. *Obstetrics and Gynaecology* 1987;69(2):214–222. PMID: 3027637.
29. Dworsky M, Whitley R, Alford C. Herpes zoster in early infancy. *Am J Dis Child* 1980;134:618–619. DOI: 10.1001/archpedi.1980.02130180074021.
30. Ahn KH, Park YJ, Hong SC, et al. Congenital varicella syndrome: A systematic review. *J Obstet Gynaecol* 2016;36(5):563–566. DOI: 10.3109/01443615.2015.1127905.
31. Alkalay AL, Pomerance JL, Rimoin DL. Fetal varicella syndrome. *Journal of Paediatrics* 1987;111(3):320–323. DOI: 10.1016/s0022-3476(87)80447-x.
32. Paryani SG, Arvin AM. Intrauterine infection with varicella-zoster virus after maternal varicella. *N Engl J Med* 1986;314(24):1542–1546. DOI: 10.1056/NEJM198606123142403.
33. Smith CK, Arvin AM. Varicella in the fetus and newborn. *Semin Fetal Neonatal Med* 2009;14(4):209–217. DOI: 10.1016/j.siny.2008.11.008.
34. Meyers JD. Congenital varicella in term infants: risk reconsidered. *J Infect Dis* 1974;129(2):215. DOI: 10.1093/infdis/129.2.215.
35. American Academy of Pediatrics. *Varicella-zoster virus infections*. In: *Red Book 2018: Report of the Committee on Infectious Diseases*, 31st edition, Kim berlin DW, Brady MT, Jackson MA, editors. Itasca, Illinois, USA: American Academy of Pediatrics, 2018. pp.869–883.
36. Bailey JE, Toltzis P. Perinatal viral infections. In: *Neonatal-Perinatal Medicine: Diseases of the Fetus and Infant*, 9th edition. Martin RJ, Fanaroff AA, Walsh MC, editors. St. Louis: Elsevier Mosby, 2011. Vol. 2, p.841.
37. Prober CG, Gershon AA, Grose C, et al. Consensus: Varicella-zoster infections in pregnancy and the perinatal period. *Pediatr Infect Dis J* 1990;9(12):865–869. PMID: 2277741.
38. Saji F, Samejima Y, Kamiura S, et al. Dynamics of immunoglobulins at the fetomaternal interface. *Rev Reprod* 1999;4(2):81–89. DOI: 10.1530/ror.0.0040081.
39. Lipton SV, Brunell PA. Management of varicella exposure in a neonatal intensive care unit. *JAMA* 1989; 261:1782.
40. Ng PC, Lyon DJ, Wong MY, et al. Varicella exposure in a neonatal intensive care unit: Emergency management and control measures. *J Hosp Infect* 1996;32(3):229–236. DOI: 10.1016/s0195-6701(96)90149-8.
41. Blair RJ. Varicella-zoster virus. *Pediatr Rev* 2019;40(7):375–377. DOI: 10.1542/pir.2017-0242.
42. Leung J, Harpaz R, Baughman AL, et al. Evaluation of laboratory methods for diagnosis of varicella. *Clin Infect Dis* 2010;51(1):23–32. DOI: 10.1086/653113.
43. Mendelson E, Aboudy Y, Smetana Z, et al. Laboratory assessment and diagnosis of congenital viral infections: Rubella, cytomegalovirus (CMV), varicella-zoster virus (VZV), herpes simplex virus (HSV), parvovirus B19 and human immunodeficiency virus (HIV). *Reprod Toxicol* 2006;21(4):350–382. DOI: 10.1016/j.reprotox.2006.02.001.
44. Mouly F, Mirllesse V, Meritet JF, et al. Prenatal diagnosis of fetal varicella-zoster virus infection with polymerase chain reaction of amniotic fluid in 107 cases. *Am J Obstet Gynecol* 1997;177(4):894–898. DOI: 10.1016/s0002-9378(97)70291-6.
45. Bohlke K, Galil K, Jackson LA, et al. Postpartum varicella vaccination: Is the vaccine virus excreted in breast milk? *Obstet Gynaecol* 2003;102:970–977. DOI: 10.1016/s0029-7844(03)00860-3.
46. Hanaoka M, Hisano M, Watanabe N, et al. Changes in the prevalence of the measles, rubella, varicella-zoster, and mumps virus antibody titers in Japanese pregnant women. *Vaccine* 2013;31(19):2343–2347. DOI: 10.1016/j.vaccine.2013.03.012.
47. Watson B, Civen R, Reynolds M, et al. Validity of self-reported varicella disease history in pregnant women attending prenatal clinics. *Public Health Rep* 2007;122(4):499–506. DOI: 10.1177/003335490712200411.
48. Heuchan AM, Isaacs D. The management of varicella-zoster virus exposure and infection in pregnancy and the newborn period. Australasian Subgroup in Paediatric Infectious Diseases of the Australasian Society for Infectious Diseases. *Med J Aust* 2001;174(6):288–292. DOI: 10.5694/j.1326-5377.2001.tb143273.x.
49. Tan MP, Koren G. Chickenpox in pregnancy: Revisited. *Reprod Toxicol* 2006;21(4):410–420. DOI: 10.1016/j.reprotox.2005.04.011.
50. Lamont RF, Sobel JD, Carrington D, et al. Varicella-zoster virus (chickenpox) infection in pregnancy. *BJOG* 2011;118(10):1155–1162. DOI: 10.1111/j.1471-0528.2011.02983.x.
51. Mandelbrot L. Fetal varicella: Diagnosis, management, and outcome. *Prenat Diagn* 2012;32(6):511–518. DOI: 10.1002/pd.3843.
52. American Academy of Pediatrics Committee on Infectious Diseases. The use of oral acyclovir in otherwise healthy children with varicella. *Pediatrics* 1993;91(3):674–676. PMID: 8382784.
53. Centers for Disease Control and Prevention (CDC). A new product (VariZIG) for postexposure prophylaxis of varicella available under an investigational new drug application expanded access protocol. *MMWR Morb Mortal Wkly Rep* 2006;55(8):209–210. PMID: 16511443.
54. Maranich AM, Rajnik M. Varicella-specific immunoglobulin G titers in commercial intravenous immunoglobulin preparations. *Pediatrics* 2009;124(3):e484–e488. DOI: 10.1542/peds.2009-0047.
55. Miller E, Craddock-Watson JE, Ridehalgh MK. Outcome in newborn babies given anti-varicella-zoster immunoglobulin after perinatal maternal infection with varicella-zoster virus. *Lancet* 1989;2(8659):371–373. DOI: 10.1016/s0140-6736(89)90547-3.
56. Marin M, Guris D, Chaves SS, et al. Prevention of varicella: recommendations of the Advisory Committee on Immunization Practices (ACIP). *MMWR Recomm Rep* 2007;56(RR-4):1–40. DOI: 10.1016/s0029-7844(03)00860-3.
57. Cohen A, Moschopoulos P, Stiehm RE, et al. Congenital varicella syndrome: the evidence for secondary prevention with varicella-zoster immune globulin. *CMAJ* 2011;183(2):204–208. DOI: 10.1503/cmaj.100615.
58. Harger JH, Ernest JM, Thurnau GR, et al. Frequency of congenital varicella syndrome in a prospective cohort of 347 pregnant women. *Obstet Gynecol* 2002;100(2):260–265. DOI: 10.1016/s0029-7844(02)02059-8.
59. Figueroa-Damian R, Arredondo-Garcia JL. Perinatal outcome of pregnancies complicated with varicella infection during the first 20 weeks of gestation. *Am J Perinatol* 1997;14(07):411–414. DOI: 10.1055/s-2007-994170.
60. Enders G, Miller E, Craddock-Watson J, et al. Consequences of varicella and herpes zoster in pregnancy: Prospective study of

- 1739 cases. *Lancet* 1994;343(8912):1548–1551. DOI: 10.1016/s0140-6736(94)92943-2.
61. Tebruegge M, Pantazidou A, Curtis N. Towards evidence based medicine for paediatricians. How effective is varicella–zoster immunoglobulin (VZIG) in preventing chickenpox in neonates following perinatal exposure? *Arch Dis Child* 2009;94(7):559. DOI: 10.1136/adc.2008.154542.
  62. Centers for Disease Control and Prevention (CDC). Morbidity and Mortality Weekly Report. Updated recommendations for Use of VariZIG–United States. 2013. Available at: <https://www.cdc.gov/mmwr/preview/mmwrhtml/mm6228a4.htm>. Accessed date: 18 August, 2022
  63. American Academy of Pediatrics. Varicella–zoster virus infections. In: Red Book: 2018 Report of the Committee on Infectious Diseases, 31st edition, Kim berlin DW, Brady MT, Jackson MA, et al., editors. Itasca, IL: American Academy of Pediatrics, 2018. p. 871.
  64. Centers for Disease Control and Prevention (CDC). FDA approval of an extended period for administering VariZIG for postexposure prophylaxis of varicella. *MMWR Morb Mortal Wkly Rep* 2012; 61:212.
  65. Kesson AM, Grimwood K, Burgess MA, et al. Acyclovir for the prevention and treatment of varicella-zoster in children, adolescents and pregnancy. *J Paediatr Child Health* 1996;32(3):211. DOI: 10.1111/j.1440-1754.1996.tb01556.x.
  66. Williams H, Latif A, Morgan J, et al. Acyclovir in the treatment of neonatal varicella. *J Infect* 1987;15:65–67. DOI: 10.1016/s0163-4453(87)91501-5.
  67. Singalavanija S, Limpongsanurak W, Horpoapan S, Ratrisawadi V. Neonatal varicella: A report of 26 cases. *J Med Assoc Thai* 1999; 82(10):957–962. PMID: 10561956.
  68. Yoshida M, Yamagami N, Tezuka T, et al. Case report: Detection of varicella–zoster virus DNA in maternal breast milk. *J Med Virol* 1992;38(2):108–110. DOI: 10.1002/jmv.1890380207.
  69. Grumach AS, Carmona RC, Lazarotti D, et al. Immunological factors in milk from Brazilian mothers delivering small-for-date term neonates. *Acta Paediatr* 1993;82(3):284–290. DOI: 10.1111/j.1651-2227.1993.tb12661.x.

# Gastroschisis: Anatomic Defects, Etiopathogenesis, Treatment, and Prognosis

Roya Huseynova Arif<sup>1</sup>, Latifa Bin Mahmoud<sup>2</sup>, Abdel Basit El Syed Ali<sup>3</sup>, Adli Abdelrahim<sup>4</sup>, Oktay Huseynov Ilham<sup>5</sup>, Fazal Nouman Wahid<sup>6</sup>, Mohammad Mozibur Rahman<sup>7</sup>, Nalinikanta Panigrahy<sup>8</sup>, Devendra Panwar<sup>9</sup>, Gangajal Kasniya<sup>10</sup>, Kamlesh Jha<sup>11</sup>, Akhil Maheshwari<sup>12</sup>

Received on: 10 September 2022; Accepted on: 14 September 2022; Published on: 07 October 2022

## ABSTRACT

Gastroschisis is a congenital defect in the abdominal wall that is typically located to the right of the umbilicus. The intestines, and sometimes parts of the liver and the stomach, also protrude into the amniotic space. Unlike in omphaloceles, these visceral organs do not have a covering sac and are directly exposed to the amniotic fluid. The organs show variable degrees of inflammatory changes and scarring. In this review, we have summarized currently available information on the anatomical changes in the intestine directly exposed to the amniotic fluid, the etiopathogenesis, treatment, and prognosis.

**Keywords:** Abdominal wall defect, Amniotic fluid, Atresia, Chronic hypertension, Congenital, Gastroschisis, Neonatal intensive care unit, Pulmonary.

*Newborn* (2022): 10.5005/jp-journals-11002-0041

## HIGHLIGHTS

- Gastroschisis is a congenital abdominal wall defect in which the intestines and other abdominal viscera protrude into the amniotic space. The incidence is 4.3 per 10,000 live births.
- The lesions of gastroschisis are typically classified as either simple or complex. Simple gastroschisis is an isolated anomaly, whereas complex gastroschisis is complicated by problems such as intestinal atresia, stenosis, perforation, volvulus, and bowel wall ischemia and/or necrosis.
- In gastroschisis, there is an incomplete fusion of lateral body wall folds of the embryo during the fourth week of gestation. This results in the protrusion of abdominal organs through the abdominal wall.
- Gastroschisis can be diagnosed on prenatal ultrasound scans as early as 12 weeks gestation. Careful monitoring of these fetuses before delivery can improve outcomes.
- Surgical treatment varies by institution. Some experts favor an initial silo bag placement with staged closures in most patients, whereas others may choose primary closures in some infants.

## INTRODUCTION

Gastroschisis is a rare congenital abdominal wall defect in which the intestines, and occasionally the stomach and/or the liver protruding into the amniotic space.<sup>1,2</sup> The parts of the gastrointestinal tract exposed to amniotic fluid frequently show edema and inflammatory changes, which can damage the seromuscular layer. In this review, we have summarized currently available information on the anatomical changes, etiology, pathophysiological changes, clinical features, treatment, and prognosis of gastroschisis. We have included data from our clinical units and an extensive literature search in the databases

All authors are members of the Global Newborn Society (<https://www.globalnewbornsociety.org/>).

<sup>1,2,4</sup>Division of Neonatology, King Saud Medical City, Riyadh, Saudi Arabia

<sup>3,5</sup>Department of Surgery, Azerbaijan Medical University, Baku, Azerbaijan

<sup>6</sup>Department of Pediatric Surgery, King Saud Medical City, Riyadh, Saudi Arabia

<sup>7</sup>Division of Neonatology, Institute of Child and Mother Health, Dhaka, Bangladesh

<sup>8</sup>Rainbow Children's Hospital and Perinatal Care, Hyderabad, Telangana, India

<sup>9</sup>Lifeline Medical Institutions, Jalandhar, Punjab, India

<sup>10</sup>Department of Pediatrics, Cohen Children's Medical Center, New York, United States of America

<sup>11</sup>Division of Neonatology, Mount Sinai Children's Hospital, Chicago, Illinois, United States of America

<sup>12</sup>Weatherby Healthcare, Fort Lauderdale, Florida, United States of America

**Corresponding Author:** Roya Huseynova Arif, Division of Neonatology, King Saud Medical City, Riyadh, Saudi Arabia, Phone: +96 6508463068, e-mail: r.huseynova@ksmc.med.sa

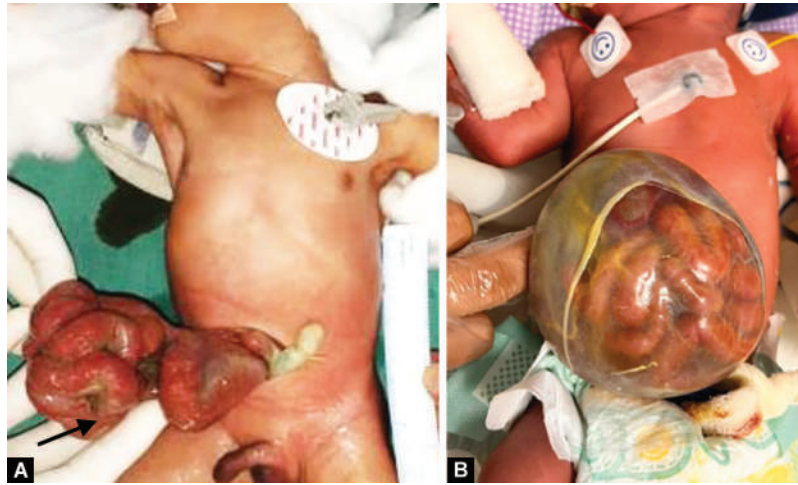
**How to cite this article:** Arif RH, Mahmoud LB, Ali ABES, *et al.* Gastroschisis: Anatomic Defects, Etiopathogenesis, Treatment, and Prognosis. *Newborn* 2022;1(3):287–296.

**Source of support:** Nil

**Conflict of interest:** None

PubMed, EMBASE, and Scopus. To avoid bias in the identification of studies, keywords were short-listed in *a priori* discussions and from PubMed's Medical Subject Heading (MeSH) thesaurus.

The term gastroschisis is derived from the Greek word "laproschisis," meaning "belly-cleft." It was used in the nineteenth and early twentieth centuries by teratologists to designate all abdominal wall defects. Anatomically, gastroschisis is seen most frequently located to the right of a normally-positioned



**Figs 1A and B:** Anterior abdominal wall defects in gastroschisis, compared with an omphalocele. (A) In gastroschisis, there is no covering over the intestinal loops. Many segments show obvious inflammation with matting, dilatation, and a covering of a fibrinous inflammatory rind (arrow). The abdominal wall defect is frequently inferolateral to the umbilicus on the right side; (B) Gastroschisis should be differentiated from an omphalocele, which is an anterior abdominal wall defect where the viscera herniate through the umbilical cord and are enclosed in most cases within a covering amniotic sac

umbilicus (Fig. 1). The frequency of intrauterine fetal demise is low, although the incidence of preterm delivery and intrauterine fetal growth restriction may be high.<sup>3</sup> Gastroschisis is generally not associated with other congenital anomalies, but 5–20% may have neuromuscular, cardiac, pulmonary, renal, or urological abnormalities.<sup>4</sup> Chromosomal abnormalities are uncommon in infants with gastroschisis.<sup>5</sup>

Gastroschisis lesions are typically classified as either simple or complex. Simple gastroschisis is an isolated anomaly and needs treatment for intestinal anatomy and autonomy. In contrast, one-third of these patients have complex gastroschisis with associated intestinal atresia, stenosis, perforation, volvulus, bowel ischemia, and/or necrosis.<sup>6</sup> These infants need support for gut dysmotility, but may also require extensive medical and/or surgical treatment for the associated intestinal anomalies.<sup>7</sup> In most cases, gastroschisis is readily detectable on prenatal fetal ultrasonography (US). The specificity figures may reach as high as >95%, and may allow for a planned delivery in an appropriately specialized obstetrical/neonatal units with appropriate surgical support.<sup>8</sup>

Treatment of gastroschisis is associated with considerable practice variation in terms of timing of delivery, closure techniques, and nutritional management, and postnatal management. Compromised mesenteric perfusion can result in necrosis of the bowel, atresia, and short bowel syndrome. After surgery, many patients may have prolonged feeding intolerance. The morbidity of gastroschisis is principally determined by the severity of the bowel damage existing at birth, and postnatal management purposes include reducing the bowel back into the abdominal cavity without trauma to the intestine, closure of the abdominal wall defect, avoiding increased intraabdominal pressure, and enteral feed initiation.<sup>9</sup> The mortality figures may reach up to 5%.<sup>10</sup>

## EPIDEMIOLOGY

The overall incidence of gastroschisis is 4.3 per 10,000 live births. Unlike the observations in many other anomalies, the average age of women who gave birth to infants with gastroschisis may be lower than that of controls.<sup>11,12</sup> In the past few decades, the incidence of

gastroschisis may have increased;<sup>13</sup> in one study, the rate increased from 2.9 to 6.4 per 1,000 discharges over 12 years (1997–2008) and then declined gradually over the next 4 years (2008–2011) to 4.7 per 1,000 discharges. The frequency seems to have stabilized since then.<sup>14</sup>

Gastroschisis has been associated with teen pregnancies with age maternal less than 20 years and age-independent nulliparity; maternal exposure to cigarette smoke, illicit substances, alcohol, and environmental chemicals; lower maternal body mass index (BMI) and poor nutrition; and lower socioeconomic status.<sup>15–20</sup> Urinary and sexually-transmitted infections acquired shortly before or during the first trimester of gestation have also been associated with increased gastroschisis, possibly due to altered immune responses.<sup>21–23</sup> In contrast, higher pre-pregnancy BMI may be protective.<sup>24</sup> Other protective factors may include chronic hypertension, high educational attainment, and non-Hispanic black race.<sup>25–27</sup>

## ANATOMICAL ORIGIN OF GASTROSCHISIS

In gastroschisis, there is an incomplete fusion of lateral body wall folds of the embryo to form the anterior body wall which occurs normally during the fourth week of gestation. Consequently, the abdominal organs extrude through the abdominal wall and the intestines herniate to the right of the umbilicus. The etiopathogenesis leading to the observed pathoanatomy of gastroschisis is poorly understood. Several hypotheses have been proposed:

Duhamel<sup>28</sup> proposed that the defect arises as a result of the failure of differentiation of the embryonic somatopleural mesenchyme due to some teratogenic exposure during the 4th week of gestation leading to intestinal herniation. However, this hypothesis fails to explain why the mesoderm defect would occur in such a small area.

Shaw<sup>29</sup> suggested rupture of the amnion around the umbilical ring causing weakening of the body wall allowing gut herniation, however, the mechanism was not clearly determined, and the hypothesis was not supported by any pathological changes notable in the embryos.



DeVries<sup>30</sup> hypothesized that the abnormal involution of the right umbilical vein resulted in diminished viability of the surrounding mesenchyme and paraumbilical tissue in the body wall in that region, leading to gut herniation. However, the relative lack of umbilical venous drainage of the anterior abdominal wall reduces its credibility.

Hoyme et al.<sup>31</sup> postulated that the rupture of the right vitelline artery (omphalomesenteric) in the umbilical region with subsequent infarction and necrosis of the body wall at the base of the cord resulted in intestinal herniation. However, this postulated sequence of events has lost some credibility because of evidence that the abdominal wall may be perfused primarily by the dorsolateral aortic branches, not the vitelline arteries.

Feldkamp et al.<sup>32</sup> proposed that the abdominal wall defects in gastroschisis may be created by abnormal folding of the ventral body wall. Asymmetry in body folds, the position of organs, and vascular development may explain the occurrence of gastroschisis specifically on the right side, and the skin growth between the defect and the umbilical cord may result from the growth of ectodermal tissues.

Stevenson et al.<sup>33</sup> postulated that the presence of folding defect cause failure of the yolk sac and related vitelline structures to be incorporated into the umbilical stalk and create a new defect in the abdominal wall separating the abdominal cord through which the intestine gets extruded into the amniotic cavity at the right side of the umbilical ring.

Rittler et al.<sup>34</sup> reported the presence of amnion weakness, vascular changes, or insufficient tissue development in the periumbilical region leading to a defective umbilical ring with a subsequent detachment of the umbilical cord towards the right side of the ring and gut evisceration.

Lubinsky<sup>35</sup> proposed vascular thrombotic event in the space to the umbilical ring generated by the normal involution of the right umbilical vein damaging the adjacent tissue growth and causing herniation of the abdominal viscera.

Bargy and Beaudoin<sup>36</sup> stated that teratogens may cause a rupture of the amnion in the flaccid part of the umbilical cord during the early gestational weeks, the period of physiological umbilical hernia.

Opitz et al.<sup>37</sup> considered that gastroschisis is a primary midline defect that involves the umbilical canal from amniotic to peritoneal space and its umbilical ring, either through non-closure or rupture of the membrane covering the area, mostly to the right, between the cord and the edge of the ring.

## ETIOLOGY

Current information emphasizes the primary role of non-genetic/environmental factors as primary; genetic factors may possibly enhance the individual's susceptibility. As noted above, epidemiological associations have been noted with maternal age, early initiation of sexual activity, and genitourinary infections.<sup>21</sup> Stress-induced enhancement of inflammation might also be an important variable.<sup>23</sup> Maternal exposure to tobacco, alcohol or illicit drugs may be associated. Environmental exposures to nitrosamines such as atrazine, cyclooxygenase inhibitors such as aspirin and ibuprofen, decongestants such as pseudoephedrine and phenylpropanolamine, and pain relievers/addiction agents such as opioids;<sup>15</sup> antihistamines;<sup>38</sup> antithyroid medications;<sup>39</sup> and radiation<sup>40</sup> may also be important. Studies have also associated

nutritional factors such as a high preconception caloric intake; deficiency of methionine and threonine;<sup>41</sup> and that of folic acid.<sup>42</sup>

The role of genetic factors in the pathogenesis of gastroschisis is less clear. Family cases of twins and distant relatives have been noted.<sup>43,44</sup> Chromosomal anomalies have been associated with an isolated frequency of 82.1%.<sup>17,45</sup> There is a possibility that gastroschisis may result from the interaction between biological and molecular mechanisms in genetically-predisposed embryos/fetuses during the first 10 weeks of development.<sup>45</sup> Some studies have linked genes related to vascular compromise with environmental factors as increasing the risk of gastroschisis. In a case-control study of 57 gastroschisis cases and 506 controls, Torfs et al.<sup>46</sup> linked DNA polymorphisms in 32 genes important in maintaining angiogenesis, blood vessel integrity, inflammation, wound repair, and dermal/epidermal strength. Single nucleotide polymorphisms (SNPs) in the intercellular adhesion molecule (ICAM)-1, the nitric oxide synthase (NOS)-3, and the natriuretic peptide precursor (NPPA)-3 have been identified with increased risk for gastroschisis for heterozygotes. In ICAM1, glycine 241 to arginine [G241R; odds ratio (OR) = 1.7]; a glutamic acid to aspartate (glu298-to-asp variant 163729.0001; OR = 1.9; and 2238T>C, OR = 1.9, respectively) have been implicated. The three SNPs showed a strong interaction with maternal smoking (OR, 5.2–6.4) for smokers carrying 1 or 2 variant alleles compared to wildtype nonsmokers. In another study, Lammer et al.<sup>47</sup> reviewed the evidence supporting a gene-environment model of gastroschisis involving the VEGF-NOS3 pathway. Gastroschisis has also been associated with Smith-Lemli-Opitz syndrome.<sup>48,49</sup>

## PRENATAL DIAGNOSIS – ULTRASOUND; DIFFERENTIATION FROM OMPHALOCELES

Gastroschisis can be diagnosed on prenatal ultrasound scans as early as 12 weeks' gestation.<sup>20,50</sup> Gastroschisis should be suspected when there is (a) appearance of eviscerated bowel, with features such as bowel dilatation and/or wall thickening; (b) absence of a covering membrane or a sac; (c) identification of the site of cord insertion relative to the defect (the defect is paraumbilical, most often right-sided); (d) identification of eviscerated organs; and (e) identification of associated malformations to (i) differentiate simple vs complex gastroschisis, and (ii) to identify sonographic risk features that predict the possibility of bowel injury at birth.<sup>50</sup> Fetal bowel dilatation >20 mm prior to delivery has been associated with poorer outcomes.<sup>51</sup> Other prenatal sonographic features in gastroschisis that are associated with poor outcomes are intestinal atresia, volvulus, or perforation.<sup>52</sup> Overall, it has a much better prognosis than omphalocele.<sup>33,50</sup> The reported rate of associated anomalies seen in gastroschisis ranges from 7% to 17%; very few are thought to have a genetic basis, and most prenatal diagnostic centers do not routinely offer fetal karyotyping for gastroschisis.<sup>50</sup>

The importance of differentiating gastroschisis from omphalocele is critical given the differences in the associated malformation profile of the two anomalies (Fig. 1). Omphalocele is an anterior abdominal wall defect with visceral herniation through the umbilicus. This is a developmental defect where the intestine that is normally herniated into the amniotic cavity fails to return to the abdomen at approximately 12 weeks of gestation.<sup>53</sup> Omphalocele can be differentiated from gastroschisis based on the presence of a covering amniotic sac. The location of the defect relative to the umbilical cord insertion is also of diagnostic

**Table 1:** Differences between gastroschisis and omphalocele

| <i>Gastroschisis</i>  | <i>Omphalocele</i>   |
|---|--|
| Gastroschisis: 1 case in 2,229 births (about 1,871 infants each year). <sup>57</sup>  | Omphalocele: 1 case in 5,386 births (about 775 babies annually). <sup>57</sup>   |
| Epidemiologic data over the last few decades show that the incidence of gastroschisis has increased 3–4-fold. <sup>14</sup>                     | Epidemiologic data over the last 4–5 decades show that the incidence of omphalocele has remained constant. <sup>14</sup>         |
| Gastroschisis is more common in young mothers with low gravida; it is associated with prematurity and small-for-gestational-age (SGA) neonates. | Omphaloceles are associated with increased maternal age. <sup>13</sup>   |
| Embryopathy.  | Fetopathy.   |
| Location: right side.   | Location: center.  |
| No umbilical cord.  | Umbilical cord inserted in the caudal area of the hernial sac.   |
| Content not covered by sac.   | Has peritoneum-amniotic membrane.  |
| High level of serum levels of $\alpha$ -fetoprotein due to evisceration even higher than in omphalocele cases. <sup>50</sup>                    | Lower level of $\alpha$ -fetoprotein compared to gastroschisis.  |
| Content: intestine (100%), colon, bladder, gonads (occasionally).   | Content: intestine, liver, spleen, colon, bladder (occasionally).  |
| Rarely associated with other congenital anomalies (15%).  | Frequently associated with other congenital anomalies (40–80%).  |
|   | Omphaloceles are associated with trisomy 13, 18, and 21 (in 25–50% of cases) and with Beckwith–Wiedemann syndrome. <sup>58</sup> |
|   | Higher mortality rate compared to those with gastroschisis. <sup>59</sup>  |
| Lower overall mortality in infants with gastroschisis compared to those with omphalocele.   |  |

importance; the defect in omphalocele is within the insertion of the umbilical cord into the abdominal wall. This contrasts with the defects in gastroschisis that are paraumbilical, most often to the right. Unlike in gastroschisis, the intestine does not show inflammation as it is not continuously exposed to amniotic fluid.<sup>54</sup> A prenatal diagnosis of omphalocele in the first trimester conveys a greater than 50% risk of associated chromosomal abnormality, in addition to a risk of other major syndromic and isolated somatic malformations, many of which are lethal.<sup>55</sup> Rarely, a ruptured omphalocele may result in the inadvertent sonographic diagnosis of gastroschisis.<sup>56</sup> The distinction between gastroschisis and omphalocele is summarized in Table 1.

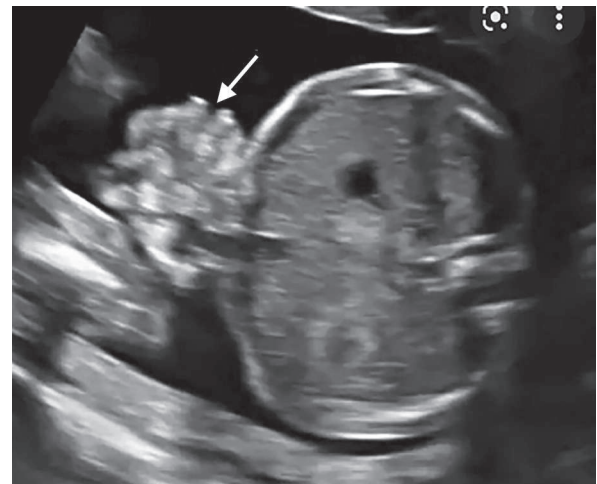Although ultrasound is still the gold standard for the assessment of fetal malformations, many centers have now started offering magnetic resonance imaging (MRI) for prognostic assessment of gastroschisis with intestinal atresia, allowing better perinatal management and parental counseling.<sup>52,60</sup> Fetal MRI volumetry can predict the need for silo bag treatment in gastroschisis with reasonable accuracy and might help in planning for treatment.<sup>61</sup>

## MANAGEMENT

The management of infants with gastroschisis requires the following:

- Prenatal care;
- Delivery at a specialized center with expertise in monitoring and pediatric surgery;
- Management guided by the physiological stability and condition of the intestine;
- Close monitoring of general condition, respiratory condition, and bowel viability;
- Reduction of the bowel back into the abdominal cavity with minimal injury;<sup>9,62</sup> and
- Initiation and optimal management of enteral feeding.

All these aspects of management continue to be debated and there is still considerable center-to-center variability in treatment.



**Fig. 2:** Prenatal ultrasound evaluation shows characteristic features of gastroschisis. Bowel loops can be seen floating outside the fetal abdomen in the amniotic cavity (arrow). Unlike in omphaloceles (not shown), there is no peritoneal covering

The following sections summarize the evidence for each of these domains of care.

### Prenatal Management

Once gastroschisis is diagnosed, fetal growth and amniotic fluid volume are measured by sonographic assessment at 3–4-week intervals starting at 24-weeks' gestation (Fig. 2).<sup>63</sup> Oligohydramnios may be related to fetal growth restriction and is a risk for cord compression, while polyhydramnios may be predictive of bowel atresia.<sup>64</sup> Growth restriction in fetuses with abdominal wall defects may predict increased adverse neonatal outcomes.<sup>65</sup>

Although fewer infants with isolated gastroschisis have chromosomal anomalies, the risk is higher in those with

extraintestinal structural abnormalities. In these cases, amniocentesis may be warranted for evaluation and further management.<sup>66</sup>

### Time of Delivery

The preferred mode of delivery and timing of delivery is controversial. Although gastroschisis can be easily recognized on prenatal ultrasound with the visualization of intestinal loops floating in the amniotic cavity without a covering membrane, there is still no consensus on the ideal timing of delivery, the prognosis, and the best treatment strategy. Consequently, there is considerable variability in treatment.<sup>67</sup>

Some studies favor premature delivery based on the assumption that intestinal inflammation progressively increases with the duration of pregnancy due to continued exposure to amniotic fluid.<sup>68,69</sup> However, other studies such as one by Segel et al.<sup>70</sup> found no benefit for Cesarean sections in terms of bowel ischemia, small bowel obstruction, necrotizing enterocolitis, sepsis, and mortality.

Early delivery has also been considered to reduce bowel matting. However, there are data showing above 3% reduction in severe matting with every extra week a fetus was *in utero*.<sup>71</sup> Hence, planned delivery before 36 weeks of completed gestation does not seem to confer any short- or long-term advantages in outcome but may actually contribute to adverse outcomes related to prematurity.<sup>72</sup> Premature delivery (<35 0/7 weeks) was associated with a longer duration of ventilation support and longer dependence on the parenteral nutrition (PN) compared to the late preterm (35 0/7–36 6/7 weeks) and early term (from 37 0/6 to 38 6/7 weeks) gestation.<sup>73</sup> The authors also found a similar frequency of stillbirths and neonatal deaths during late preterm and term periods.

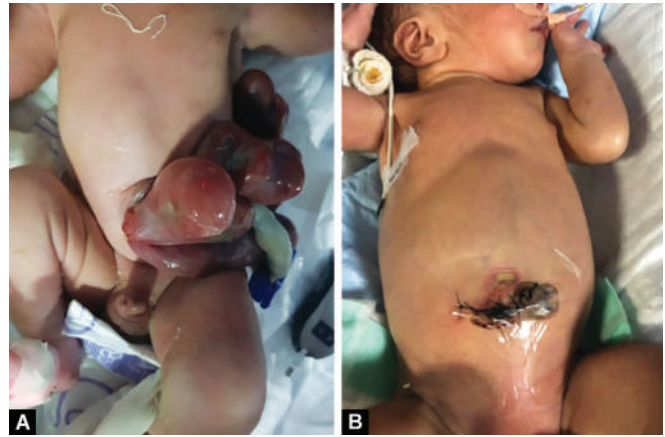
### Mode of Delivery

The advantages of a Cesarean section versus vaginal delivery have been evaluated with many studies. Current literature does not advocate routine Cesarean delivery for fetuses with gastroschisis, and the decisions to determine the mode of delivery may be based on obstetrical indications.<sup>74</sup> The fetal/neonatal outcomes do not seem to be influenced by the mode of delivery;<sup>75</sup> there are actually some data indicating that Cesarean deliveries performed for obstetric reasons were actually associated with higher rates of respiratory distress, gastrointestinal dysfunction, and bowel stenosis.

### Surgical Procedures

The goals of surgical management are reduction of the herniated viscera into the peritoneal cavity and closure of the abdominal wall defect, while minimizing the risk of abdominal compartment syndrome. While the condition of the exposed bowel and the degree of abdominal-visceral disproportion primarily dictate the type and timing of surgical intervention, other factors such as gestational maturity, infant's weight, and co-morbidities also need to be considered. Two surgical options are currently available, primary- and staged-reduction.

Primary reduction of gastroschisis is usually performed if the herniated bowel can be safely placed back into the abdominal cavity without causing excessive intra-abdominal pressure (Fig. 3). Following the reduction of the bowel into the abdominal cavity, the defect can be closed either by the sutured fascial closure or by sutureless closure technique. If there is a risk of increased intra-abdominal pressure, only the skin can be approximated, and the fascial defect can be repaired later as an umbilical hernia. One study

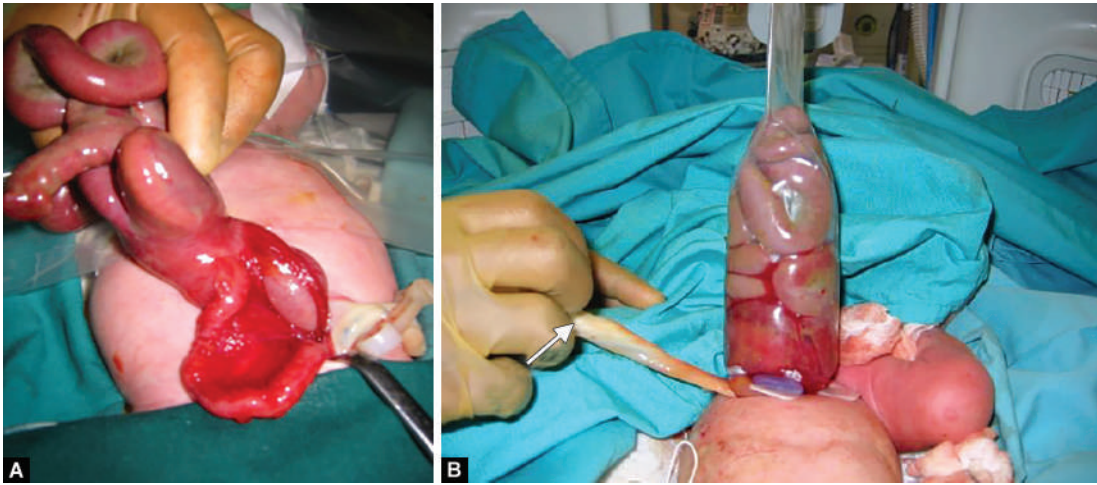


**Figs 3A and B:** Primary reduction of gastroschisis. This procedure is usually performed if the herniated bowel (A) can be safely placed back into the abdominal cavity without causing excessive intra-abdominal pressure. The defect in the abdominal cavity can be closed either by the sutured fascial closure (B) or by a sutureless closure technique. This infant required endotracheal intubation and short-term treatment with low-medium ventilatory settings

showed that primary closure allows recovery with fewer ventilator days, shorter duration of PN, and shorter length of hospital stay.<sup>76</sup> Another showed that primary closure showed improved neonatal outcomes, including shorter time to initiate and reach full enteral feeds, length of hospitalization, and lower risk of surgical wound infection.<sup>73</sup>

Unfortunately, many infants run the risk of developing abdominal compartment syndrome after primary reduction. This is a serious and potentially-life-threatening complication, and may be associated with respiratory compromise and ischemia of the lower limb, kidneys or the intestines. Intra-gastric or intravesical pressures above 20 mm Hg, or central venous pressure above 4 mm Hg may correlate with decreased renal and/or intestinal perfusion, and may manifest with abdominal compartment syndrome.<sup>77,78</sup> In infants receiving respiratory support, peak inspiratory pressures below 25 cm H<sub>2</sub>O after closure are reassuring and predict lower risk for abdominal compartment syndrome.<sup>79</sup>

If a primary repair is expected to increase the abdominal pressure and possibly impede respiratory and circulatory function, staged reduction should be performed. Staged reduction is achieved by the placement of a spring-loaded silo that provides coverage to the exposed bowel, protects it from infection or loss of fluids (Fig. 4). The spring-loaded ring of the silo is inserted through the abdominal wall defect and rests beneath the fascia inside the abdominal cavity without the need for placement of fascial sutures. The procedure can be performed at the bedside under mild sedation/analgesia, without the need for endotracheal intubation. The transparent bag covers the eviscerated bowel, which is reduced daily. Once the bowel is completely reduced into the abdomen closure is performed using either the sutured fascial closure or the sutureless closure techniques. This gradual approach has shown an overall survival rate of more than 90%.<sup>80</sup> Staged reduction has shown comparable results to the primary reduction.<sup>80</sup> In a meta-analysis of randomized studies, the placement of a silo with delayed closure showed better outcomes.<sup>80</sup> Staged reduction with silo placement has the advantage of achieving reduced intra-abdominal pressure at the time of definitive closure, leading to improved splanchnic perfusion, resulting in faster return of bowel

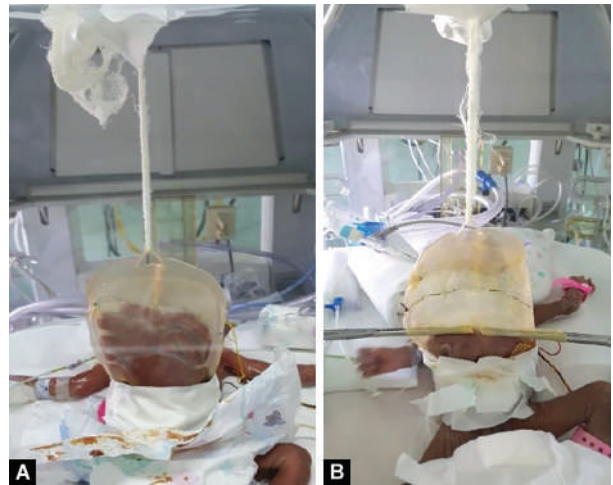

**Figs 4A and B:** Staged reduction of gastroschisis. (A) Gastroschisis at birth; (B) Many surgeons adopt a staged approach in which they place the bowel loops into a silo bag until there is improvement in perfusion with decreased cyanosis, edema, and inflammation. Once there is notable improvement in the physical condition of the bowel loops, these infants are taken for a secondary surgical procedure with replacement of the loops into the abdominal cavity

function, reduced rates of necrotizing enterocolitis and decreased risk of long-term bowel dysfunction.<sup>81,82</sup> Placement of a silo also allowed for ongoing assessment of bowel perfusion through the transparent bag. Prolonged use of the silo, however, can lead to pressure necrosis around the silo ring.

In a meta-analysis that included studies with least selection bias, staged closure with silo was associated with better outcomes and a significant reduction in ventilator days, time to first feed, and infection rates.<sup>83</sup> However, in the same meta-analysis, when all studies were included, primary closure was associated with improved outcomes. A recent large, multicenter retrospective observational study involving 866 neonates with gastroschisis compared infants who underwent immediate closure with those who had a silo placed for  $\leq 5$  days.<sup>84</sup> The two groups had generally-equivalent outcomes, except for a higher incidence of ventral hernias in infants who underwent immediate closure compared to those who had silo placed for a short duration. There were no significant differences between the two groups in terms of mortality, time to tolerance of full enteral feeds, duration of total parenteral nutrition (TPN), or the length of hospital stay.

The umbilical turban or “plastic” sutureless closure method has gained popularity in recent years due to its simplicity, and advantages of the ability to perform the procedure at the bedside, lower intra-abdominal pressures after closure, shorter duration of mechanical ventilation, decreased need for pain medication, superior cosmetic appearance of the umbilicus, and lower hospital cost.<sup>85–87</sup> This technique utilizes the umbilical cord, left deliberately long at the time of birth, as a biologic dressing. After careful reduction of the eviscerated bowel into the abdomen, the gastroschisis defect is covered with the umbilical cord. A clear plastic dressing can be placed over the defect. Eventually the defect epithelizes and the umbilical cord desiccates and detaches, occasionally leaving patients with an umbilical hernia.<sup>88</sup> This technique can be used after primary reduction as well as following staged reduction with silo placement. In the latter case, the cord is wrapped in Vaseline gauze and kept moist while the silo is in place to maintain viability. In a large, single-center cohort study of 97 neonates with gastroschisis, sutureless repair was associated with



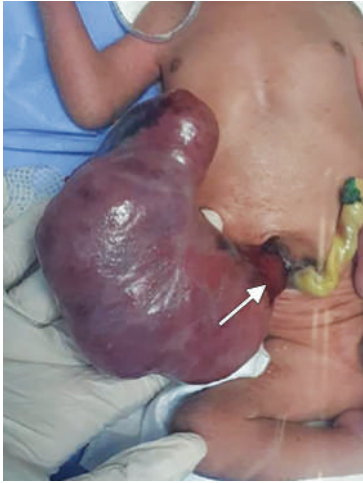**Figs 5A and B:** If a preformed spring-loaded silo bag is not available, various kinds of sterile bags have been used such a blood bag (as shown in photographs A and B)

significant reduction in duration of mechanical ventilation and pain medication requirements, but with an increased risk of umbilical hernias, compared to sutured closure.<sup>89</sup>

In low-income countries or places where preformed spring-loaded silo bags are not available, various kinds of sterile bags have been used instead including saline or a blood bag (Fig. 5) which require suturing of edge of bag to fascia under anesthesia. Although rare, the narrow fascial defect can compromise intestinal blood flow in some neonates with a closing gastroschisis, and requires urgent enlargement of the defect to preserve bowel perfusion and facilitate reduction (Fig. 6).

## Nutrition

Infants with gastroschisis frequently require prolonged PN due to intestinal ileus and dysmotility, resulting in variable degrees of feeding intolerance.<sup>90,91</sup> Total PN and gastric decompression should be provided during the abnormal intestinal motility period until enteral feeding is initiated.<sup>92</sup> Prolonged exposure to PN and delay



**Fig. 6:** Gastroschisis defects may sometimes be narrow and compromise the vascularity of the extruded bowel. Such defects may need urgent enlargement (arrow)

in enteral feeding contributes to cholestasis, feeding intolerance, and risk of late-onset sepsis.<sup>93</sup>

There is still a need to standardize and formulate evidence-based care for infant nutrition with gastroschisis.<sup>94,95</sup> Many centers recommend early introduction of enteral feeding, particularly direct feeding or suction feeding. In addition, breast milk was significantly associated with a sooner home discharge.<sup>96</sup>

### Prognosis

The overall postnatal survival rate of neonates with gastroschisis is more than 90%.<sup>96,97</sup> However, the condition is associated with significant morbidities that may result from the primary disease or the surgical procedure, including sepsis, necrotizing enterocolitis, short bowel syndrome, intestinal atresia, bowel obstruction, and volvulus which influenced the neonate's final prognosis.<sup>97,98</sup>

Complex gastroschisis is associated with increased, up to 7-fold, in-hospital mortality as compared to simple gastroschisis.<sup>99,100</sup> The presence of a higher incidence of cardiac and pulmonary comorbidities in neonates with complex gastroschisis in the presence of other comorbidities may also contribute to the poorer outcome for complex patients. Complex disease is associated with worse outcomes, including failed closure, central line infections, bacteremia, shock, ventilator-associated pneumonia, sepsis, feeding intolerance with difficulties in initiation and achievement of goal feeds, and prolonged hospitalization. Interestingly, lower gestational age and the presence of bowel matting were associated with increased length of stay, while lower birth weight was associated with mortality.<sup>101</sup> Furthermore, long-term morbidity from gastroschisis could be related to intestinal dysmotility (pseudointestinal obstruction), malabsorption (mucosal injury), and gastroesophageal reflux disease. Difficulty obtaining wound closure contributes to morbidity by prolonging intestinal dysfunction (ileus) and creating ventral hernias, which may require surgical repair.

Prenatal sonographic findings of intra-abdominal bowel dilatation, gastric dilatation, and polyhydramnios have been associated with inferior outcomes.<sup>102</sup> Liver herniation was also a marker of poor outcome (survival rate of 43% with herniation versus 97% without).<sup>103</sup> The Canadian Pediatric Surgery Network has noted bowel matting with thickening of the bowel wall,

rigidity, adherence of dilated bowel loops, and discoloration to be associated with poorer outcomes.<sup>104</sup> Higher gestational age and birth weight improved survival.<sup>105</sup>

The predictors of long-term outcomes are not well-defined. Infants in whom the umbilicus was sacrificed in surgical procedures reported psychosocial stress related to the absence of the umbilicus.<sup>106</sup> There is a need for studies of body composition.<sup>107</sup> An umbilicoplasty or umbilical reconstruction surgery can be considered in this patient group. Neurodevelopmental delay, learning issues, and overall health-related quality of life have not been well defined but are reported in preliminary studies to be within a normal range.<sup>108</sup>

### REFERENCES

- Skarsgard ED. Management of gastroschisis. *Curr Opin Pediatr*. 2016;28(3):363–369. DOI: 10.1097/MOP.0000000000000336.
- Aktoz F, Ozyuncu O, Tanacan A, et al. Gestational outcomes of pregnancies with prenatally detected gastroschisis and omphalocele. *Fetal Pediatr Pathol* 2019;38(4):282–289. DOI: 10.1080/15513815.2019.1585501.
- David AL, Tan A, Curry J. Gastroschisis: Sonographic diagnosis, associations, management and outcome. *Prenat Diagn* 2008;28(7):633–644. DOI: 10.1002/pd.1999.
- Hong CR, Fullerton BS, Han SM, et al. Impact of disease-specific volume and hospital transfer on outcomes in gastroschisis. *J Pediatr Surg* 2019;54(1):65–69. DOI: 10.1016/j.jpedsurg.2018.10.034.
- Tassin M, Benachi A. Diagnosis of abdominal wall defects in the first trimester. *Curr Opin Obstet Gynecol* 2014;26(2):104–109. DOI: 10.1097/GCO.0000000000000053.
- Oakes MC, Porto M, Chung JH. Advances in prenatal and perinatal diagnosis and management of gastroschisis. *Semin Pediatr Surg* 2018;27(5):289–299. DOI: 10.1053/j.sempedsurg.2018.08.006.
- Laje P, Fraga MV, Peranteau WH, et al. Complex gastroschisis: Clinical spectrum and neonatal outcomes at a referral center. *J Pediatr Surg* Oct 2018;53(10):1904–1907. DOI: 10.1016/j.jpedsurg.2018.03.011.
- Briganti V, Luvero D, Gulia C, et al. A novel approach in the treatment of neonatal gastroschisis: A review of the literature and a single-center experience. *J Matern Fetal Neonatal Med* 2018;31(9):1234–1240. DOI: 10.1080/14767058.2017.1311859.
- Dekonenko C, Fraser JD. Approaches for closing gastroschisis. *Adv Pediatr* 2020;67:123–129. DOI: 10.1016/j.yapd.2020.03.005.
- Gamba P, Midrio P. Abdominal wall defects: Prenatal diagnosis, newborn management, and long-term outcomes. *Semin Pediatr Surg* 2014;23(5):283–290. DOI: 10.1053/j.sempedsurg.2014.09.009.
- Jones AM, Isenburg J, Salemi JL, et al. Increasing prevalence of gastroschisis—14 states, 1995–2012. *MMWR Morb Mortal Wkly Rep* 2016;65(2):23–26. DOI: 10.15585/mmwr.mm6502a2.
- Raitio A, Tauriainen A, Leinonen MK, et al. Maternal risk factors for gastroschisis: A population-based case-control study. *Birth Defects Res* 2020;112(13):989–995. DOI: 10.1002/bdr2.1703.
- Stallings EB, Isenburg JL, Short TD, et al. Population-based birth defects data in the United States, 2012–2016: A focus on abdominal wall defects. *Birth Defects Res* 2019;111(18):1436–1447. DOI: 10.1002/bdr2.1607.
- Allman R, Sousa J, Walker MW. The epidemiology, prevalence and hospital outcomes of infants with gastroschisis. *J Perinatol* 2016;36(10):901–905. DOI: 10.1038/jp.2016.99.
- Short TD, Stallings EB, Isenburg J, et al. Gastroschisis trends and ecologic link to opioid prescription rates: United States, 2006–2015. *MMWR Morb Mortal Wkly Rep* 2019;68(2):31–36. DOI: 10.15585/mmwr.mm6802a2.
- Souther C, Puapong DP, Woo R, et al. Possible etiologies of increased incidence of gastroschisis. *Pediatr Surg Int* 2017;33(11):1209–1213. DOI: 10.1007/s00383-017-4166-4.
- Salinas-Torres VM, Gallardo-Blanco HL, Salinas-Torres RA, et al. Bioinformatic analysis of gene variants from gastroschisis recurrence

- identifies multiple novel pathogenetic pathways: Implication for the closure of the ventral body wall. *Int J Mol Sci* 2019;20(9):2295. DOI: 10.3390/ijms20092295.
18. Castilla EE, Mastroiacovo P, Orioli IM. Gastroschisis: International epidemiology and public health perspectives. *Am J Med Genet C Semin Med Genet* 2008;148C(3):162–179. DOI: 10.1002/ajmg.c.30181.
  19. Skarsgard ED, Meaney C, Bassil K, et al. Maternal risk factors for gastroschisis in Canada. *Birth Defects Res A Clin Mol Teratol* 2015;103(2):111–118. DOI: 10.1002/bdra.23349.
  20. AIUM practice parameter for the performance of detailed second- and third-Trimester diagnostic obstetric ultrasound examinations. *J Ultrasound Med* 2019;38(12):3093–3100. DOI: 10.1002/jum.15163.
  21. Feldkamp ML, Arnold KE, Krikov S, et al. Risk of gastroschisis with maternal genitourinary infections: The US national birth defects prevention study 1997–2011. *BMJ Open* 2019;9(3):e026297. DOI: 10.1136/bmjopen-2018-026297.
  22. Parker SE, Werler MM, Gissler M, et al. Maternal antibodies to *Chlamydia trachomatis* and risk of gastroschisis. *Birth Defects Res* 2017;109(8):543–549. DOI: 10.1002/bdr2.1001.
  23. Werler MM, Guery E, Waller DK, et al. Gastroschisis and cumulative stressor exposures. *Epidemiology* 2018;29(5):721–728. DOI: 10.1097/EDE.0000000000000860.
  24. Hale J, Derbyshire A, Taylor A, et al. Relationship between neonatal gastroschisis and maternal body mass index in a United Kingdom population. *Eur J Obstet Gynecol Reprod Biol* 2017;210:292–294. DOI: 10.1016/j.ejogrb.2016.12.015.
  25. Baer RJ, Chambers CD, Jones KL, et al. Maternal factors associated with the occurrence of gastroschisis. *Am J Med Genet A* 2015;167(7):1534–1541. DOI: 10.1002/ajmg.a.37016.
  26. Getz KD, Anderka MT, Werler MM, Case AP. Short interpregnancy interval and gastroschisis risk in the national birth defects prevention study. *Birth Defects Res A Clin Mol Teratol* 2012;94(9):714–720. DOI: 10.1002/bdra.23061.
  27. Friedman AM, Ananth CV, Siddiq Z, et al. Gastroschisis: Epidemiology and mode of delivery, 2005–2013. *Am J Obstet Gynecol* 2016;215(3):348 e1–e9. DOI: 10.1016/j.ajog.2016.03.039.
  28. Duhamel B. Embryology of exomphalos and allied malformations. *Arch Dis Child* 1963;38(198):142–147. DOI: 10.1136/adc.38.198.142.
  29. Shaw A. The myth of gastroschisis. *J Pediatr Surg* 1975;10(2):235–244. DOI: 10.1016/0022-3468(75)90285-7.
  30. deVries PA. The pathogenesis of gastroschisis and omphalocele. *J Pediatr Surg* 1980;15(3):245–251. DOI: 10.1016/s0022-3468(80)80130-8.
  31. Hoyme HE, Higginbottom MC, Jones KL. The vascular pathogenesis of gastroschisis: Intrauterine interruption of the omphalomesenteric artery. *J Pediatr* 1981;98(2):228–231. DOI: 10.1016/s0022-3476(81)80640-3.
  32. Feldkamp ML, Carey JC, Sadler TW. Development of gastroschisis: Review of hypotheses, a novel hypothesis, and implications for research. *Am J Med Genet A* 2007;143A(7):639–652. DOI: 10.1002/ajmg.a.31578.
  33. Stevenson RE, Rogers RC, Chandler JC, et al. Escape of the yolk sac: A hypothesis to explain the embryogenesis of gastroschisis. *Clin Genet* 2009;75(4):326–333. DOI: 10.1111/j.1399-0004.2008.01142.x.
  34. Rittler M, Vauthay L, Mazzitelli N. Gastroschisis is a defect of the umbilical ring: evidence from morphological evaluation of stillborn fetuses. *Birth Defects Res A Clin Mol Teratol* 2013;97(4):198–209. DOI: 10.1002/bdra.23130.
  35. Lubinsky M. A vascular and thrombotic model of gastroschisis. *Am J Med Genet A* 2014;164A(4):915–917. DOI: 10.1002/ajmg.a.36370.
  36. Bargy F, Beaudoin S. Comprehensive developmental mechanisms in gastroschisis. *Fetal Diagn Ther* 2014;36(3):223–230. DOI: 10.1159/000360080.
  37. Opitz JM, Feldkamp ML, Botto LD. An evolutionary and developmental biology approach to gastroschisis. *Birth Defects Res* 2019;111(6):294–311. DOI: 10.1002/bdr2.1481.
  38. Lin S, Munsie JP, Herdt-Losavio ML, et al. Maternal asthma medication use and the risk of gastroschisis. *Am J Epidemiol* 2008;168(1):73–79. DOI: 10.1093/aje/kwn098.
  39. Purnamasari D, Setyowati S, Yunir E, et al. Gastroschisis following treatment with high-dose ethimazole in pregnancy: A case report. *Drug Saf Case Rep* 2019;6(1):5. DOI: 10.1007/s40800-019-0099-2.
  40. Muller WU, Streffer C. Lethal and teratogenic effects after exposure to X-rays at various times of early murine gestation. *Teratology* 1990;42(6):643–650. DOI: 10.1002/tera.1420420609.
  41. Centofanti SF, Francisco RPV, Phillippi ST, et al. Maternal nutrient intake and fetal gastroschisis: A case–control study. *Am J Med Genet A* 2019;179(8):1535–1542. DOI: 10.1002/ajmg.a.61265.
  42. Paranjothy S, Broughton H, Evans A, et al. The role of maternal nutrition in the aetiology of gastroschisis: An incident case–control study. *Int J Epidemiol* 2012;41(4):1141–1152. DOI: 10.1093/ije/dys092.
  43. Binet A, Ceaux E, Bory JP, et al. Recurrence of pregnancies with gastroschisis: A case report. *Arch Pediatr* 2015;22(10):1039–1041. DOI: 10.1016/j.arcped.2015.07.011.
  44. Beaudoin S. Insights into the etiology and embryology of gastroschisis. *Semin Pediatr Surg* 2018;27(5):283–288. DOI: 10.1053/j.sempedsurg.2018.08.005.
  45. Salinas–Torres VM, Salinas–Torres RA, Cerda–Flores RM, et al. Familial occurrence of gastroschisis: A population-based overview on recurrence risk, sex-dependent influence, and geographical distribution. *Pediatr Surg Int* 2018;34(3):277–282. DOI: 10.1007/s00383-018-4224-6.
  46. Torfs CP, Christianson RE, Iovannisci DM, et al. Selected gene polymorphisms and their interaction with maternal smoking, as risk factors for gastroschisis. *Birth Defects Res A Clin Mol Teratol* 2006;76(10):723–730. DOI: 10.1002/bdra.20310.
  47. Lammer EJ, Iovannisci DM, Tom L, et al. Gastroschisis: A gene-environment model involving the VEGF-NOS3 pathway. *Am J Med Genet C Semin Med Genet* 2008;148C(3):213–218. DOI: 10.1002/ajmg.c.30182.
  48. Quelin C, Loget P, Verloes A, et al. Phenotypic spectrum of fetal Smith–Lemli–Opitz syndrome. *Eur J Med Genet* 2012;55(2):81–90. DOI: 10.1016/j.ejmg.2011.12.002.
  49. Garne E, Rissmann A, Addor MC, et al. Epidemiology of septo-optic dysplasia with focus on prevalence and maternal age: A EUROCAT study. *Eur J Med Genet* 2018;61(9):483–488. DOI: 10.1016/j.ejmg.2018.05.010.
  50. Torres US, Portela–Oliveira E, Braga Fdel C, et al. When closure fails: What the radiologist needs to know about the embryology, anatomy, and prenatal imaging of ventral body wall defects. *Semin Ultrasound CT MR* 2015;36(6):522–536. DOI: 10.1053/j.sult.2015.01.001.
  51. Christison–Lagay ER, Kelleher CM, Langer JC. Neonatal abdominal wall defects. *Semin Fetal Neonatal Med* 2011;16(3):164–172. DOI: 10.1016/j.siny.2011.02.003.
  52. Nakagawa M, Hara M, Shibamoto Y. MRI findings in fetuses with an abdominal wall defect: gastroschisis, omphalocele, and cloacal exstrophy. *Jpn J Radiol* 2013;31(3):153–159. DOI: 10.1007/s11604-012-0163-7.
  53. Sermer M, Benzie RJ, Pitson L, et al. Prenatal diagnosis and management of congenital defects of the anterior abdominal wall. *Am J Obstet Gynecol* 1987;156(2):308–312. DOI: 10.1016/0002-9378(87)90274-2.
  54. Ledbetter DJ. Gastroschisis and omphalocele. *Surg Clin North Am* 2006;86(2):249–260, vii. DOI: 10.1016/j.suc.2005.12.003.
  55. Ghi T, Huggon IC, Zosmer N, et al. Incidence of major structural cardiac defects associated with increased nuchal translucency but normal karyotype. *Ultrasound Obstet Gynecol* 2001;18(6):610–614. DOI: 10.1046/j.0960-7692.2001.00584.x.
  56. Betat Rda S, Telles JA, Gobatto AM, et al. Ruptured omphalocele mimicking gastroschisis in a fetus with Edwards syndrome. *Am J Med Genet A* 2014;164A(2):559–560. DOI: 10.1002/ajmg.a.36289.

57. Prevention CfDca. Data and statistics on birth defects. Available at: <https://www.cdc.gov/ncbddd/birthdefects/data.html> Accessed on: 1 November 2019.
58. Iacovella C, Contro E, Ghi T, et al. The effect of the contents of exomphalos and nuchal translucency at 11–14 weeks on the likelihood of associated chromosomal abnormality. *Prenat Diagn* 2012;32(11):1066–1070. DOI: 10.1002/pd.3959.
59. Kong JY, Yeo KT, Abdel-Latif ME, et al. Outcomes of infants with abdominal wall defects over 18years. *J Pediatr Surg* 2016;51(10):1644–1649. DOI: 10.1016/j.jpedsurg.2016.06.003.
60. Matos APP, Duarte LB, Castro PT, et al. Evaluation of the fetal abdomen by magnetic resonance imaging. Part 2: abdominal wall defects and tumors. *Radiol Bras* 2018;51(3):187–192. DOI: 10.1590/0100-3984.2016.0142.
61. Sezen P, Prayer F, Prayer D, et al. Is fetal magnetic resonance imaging volumetry of eventrated organs in gastroschisis predictive for surgical treatment? *Pediatr Radiol* 2021;51(10):1818–1825. DOI: 10.1007/s00247-021-05066-z.
62. Haddock C, Skarsgard ED. Understanding gastroschisis and its clinical management: Where are we? *Expert Rev Gastroenterol Hepatol* 2018;12(4):405–415. DOI: 10.1080/17474124.2018.1438890.
63. Amin R, Domack A, Bartoletti J, et al. National practice patterns for prenatal monitoring in gastroschisis: Gastroschisis outcomes of delivery (GOOD) provider survey. *Fetal Diagn Ther* 2019;45(2):125–130. DOI: 10.1159/000487541.
64. Japaraj RP, Hockey R, Chan FY. Gastroschisis: Can prenatal sonography predict neonatal outcome? *Ultrasound Obstet Gynecol* 2003;21(4):329–333. DOI: 10.1002/uog.85.
65. Nicholas SS, Stamilio DM, Dicke JM, et al. Predicting adverse neonatal outcomes in fetuses with abdominal wall defects using prenatal risk factors. *Am J Obstet Gynecol* 2009;201(4):383:e1–e6. DOI: 10.1016/j.ajog.2009.06.032.
66. Mastroiacovo P, Lisi A, Castilla EE, et al. Gastroschisis and associated defects: an international study. *Am J Med Genet A* 2007;143A(7):660–671. DOI: 10.1002/ajmg.a.31607.
67. Landisch RM, Yin Z, Christensen M, et al. Outcomes of gastroschisis early delivery: A systematic review and meta-analysis. *J Pediatr Surg* 2017;52(12):1962–1971. DOI: 10.1016/j.jpedsurg.2017.08.068.
68. Api A, Olguner M, Hakguder G, et al. Intestinal damage in gastroschisis correlates with the concentration of intraamniotic meconium. *J Pediatr Surg* 2001;36(12):1811–1815. DOI: 10.1053/jpsu.2001.28846.
69. Morrison JJ, Klein N, Chitty LS, et al. Intra-amniotic inflammation in human gastroschisis: Possible aetiology of postnatal bowel dysfunction. *Br J Obstet Gynaecol* 1998;105(11):1200–1204. DOI: 10.1111/j.1471-0528.1998.tb09975.x.
70. Segel SY, Marder SJ, Parry S, et al. Fetal abdominal wall defects and mode of delivery: a systematic review. *Obstet Gynecol* 2001;98(5 Pt. 1):867–873. DOI: 10.1016/s0029-7844(01)01571-x.
71. Youssef F, Laberge JM, Baird RJ, et al. The correlation between the time spent *in utero* and the severity of bowel matting in newborns with gastroschisis. *J Pediatr Surg* 2015;50(5):755–759. DOI: 10.1016/j.jpedsurg.2015.02.030.
72. Al-Kaff A, MacDonald SC, Kent N, et al. Delivery planning for pregnancies with gastroschisis: Findings from a prospective national registry. *Am J Obstet Gynecol* 2015;213(4):557:e1–e8. DOI: 10.1016/j.ajog.2015.06.048.
73. Palatnik A, Loichinger M, Wagner A, et al. The association between gestational age at delivery, closure type and perinatal outcomes in neonates with isolated gastroschisis. *J Matern Fetal Neonatal Med* 2020;33(8):1393–1399. DOI: 10.1080/14767058.2018.1519538.
74. Martins BMR, Abreu I, Meio MDB, et al. Gastroschisis in the neonatal period: A prospective case series in a Brazilian referral center. *J Pediatr Surg* 2020;55(8):1546–1551. DOI: 10.1016/j.jpedsurg.2020.04.011.
75. Fraga MV, Laje P, Peranteau WH, et al. The influence of gestational age, mode of delivery and abdominal wall closure method on the surgical outcome of neonates with uncomplicated gastroschisis. *Pediatr Surg Int* 2018;34(4):415–419. DOI: 10.1007/s00383-018-4233-5.
76. Banyard D, Ramones T, Phillips SE, et al. Method to our madness: An 18-year retrospective analysis on gastroschisis closure. *J Pediatr Surg* 2010;45(3):579–584. DOI: 10.1016/j.jpedsurg.2009.08.004.
77. Yaster M, Scherer TL, Stone MM, et al. Prediction of successful primary closure of congenital abdominal wall defects using intraoperative measurements. *J Pediatr Surg* 1989;24(12):1217–1220. DOI: 10.1016/s0022-3468(89)80554-8.
78. Olesevich M, Alexander F, Khan M, et al. Gastroschisis revisited: Role of intraoperative measurement of abdominal pressure. *J Pediatr Surg* 2005;40(5):789–792. DOI: 10.1016/j.jpedsurg.2005.01.043.
79. Petrosyan M, Sandler AD. Closure methods in gastroschisis. *Semin Pediatr Surg* 2018;27(5):304–308. DOI: 10.1053/j.sempedsurg.2018.08.009.
80. Kunz SN, Tieder JS, Whitlock K, et al. Primary fascial closure versus staged closure with silo in patients with gastroschisis: A meta-analysis. *J Pediatr Surg* 2013;48(4):845–857. DOI: 10.1016/j.jpedsurg.2013.01.020.
81. Schlatter M, Norris K, Uitvlugt N, et al. Improved outcomes in the treatment of gastroschisis using a preformed silo and delayed repair approach. *J Pediatr Surg* 2003;38(3):459–464. DOI: 10.1053/jpsu.2003.50079.
82. Kidd JN Jr, Jackson RJ, Smith SD. Evolution of staged versus primary closure of gastroschisis. *Ann Surg* 2003;237(6):759–764. DOI: 10.1097/01.SLA.0000071568.95915.DC.
83. Hawkins RB, Raymond SL, St. Peter SD, et al. Immediate versus silo closure for gastroschisis: Results of a large multicenter study. *J Pediatr Surg* 2020;55(7):1280–1285. DOI: 10.1016/j.jpedsurg.2019.08.002.
84. Sandler A, Lawrence J, Meehan J, et al. A “plastic” sutureless abdominal wall closure in gastroschisis. *J Pediatr Surg* 2004;39(5):738–741. DOI: 10.1016/j.jpedsurg.2004.01.040.
85. Emami CN, Youssef F, Baird RJ, et al. A risk-stratified comparison of fascial versus flap closure techniques on the early outcomes of infants with gastroschisis. *J Pediatr Surg* 2015;50(1):102–106. DOI: 10.1016/j.jpedsurg.2014.10.009.
86. Pet GE, Stark RA, Meehan JJ, et al. Outcomes of bedside sutureless umbilical closure without endotracheal intubation for gastroschisis repair in surgical infants. *Am J Surg* 2017;213(5):958–962. DOI: 10.1016/j.amjsurg.2017.03.017.
87. Witt RG, Zobel M, Padilla B, et al. Evaluation of clinical outcomes of sutureless vs sutured closure techniques in gastroschisis repair. *JAMA Surg* 2019;154(1):33–39. DOI: 10.1001/jamasurg.2018.3216.
88. Lao OB, Larison C, Garrison MM, et al. Outcomes in neonates with gastroschisis in U.S. children’s hospitals. *Am J Perinatol* 2010;27(1):97–101. DOI: 10.1055/s-0029-1241729.
89. Williams SL, Tkach JA, Rattan MS, et al. Feeding tolerance, intestinal motility, and superior mesenteric Artery blood flow in infants with gastroschisis. *Neonatology* 2020;117(1):95–101. DOI: 10.1159/000504226.
90. Cairo SB, Osak AH, Berkelhamer SK, et al. Direct hyperbilirubinemia in newborns with gastroschisis. *Pediatr Surg Int* 2019;35(3):293–301. DOI: 10.1007/s00383-018-4415-1.
91. Bhat V, Moront M, Bhandari V. Gastroschisis: A state-of-the-art review. *Children (Basel)* 2020;7(12):302. DOI:10.3390/children7120302.
92. Wessel JJ. Nutrition for the surgical infant with gastroschisis. *Neonatal Netw* 2019;38(1):17–26. DOI: 10.1891/0730-0832.38.1.17.
93. Hobson D, Spence K, Trivedi A, et al. Differences in attitudes to feeding post repair of gastroschisis and development of a standardized feeding protocol. *BMC Pediatr* 2019;19(1):475. DOI: 10.1186/s12887-019-1858-z.
94. Raymond SL, Hawkins RB, St. Peter SD, et al. Predicting morbidity and mortality in neonates born with gastroschisis. *J Surg Res* 2020;245:217–224. DOI: 10.1016/j.jss.2019.07.065.
95. Storm AP, Bowker RM, Klonoski SC, et al. Mother’s own milk dose is associated with decreased time from initiation of feedings to discharge and length of stay in infants with gastroschisis. *J Perinatol* 2020;40(8):1222–1227. DOI: 10.1038/s41372-020-0595-3.

96. Brebner A, Czuzoj-Shulman N, Abenhaim HA. Prevalence and predictors of mortality in gastroschisis: A population-based study of 4803 cases in the USA. *J Matern Fetal Neonatal Med* 2020;33(10):1725–1731. DOI: 10.1080/14767058.2018.1529163.
97. Ferreira RG, Mendonca CR, Ramos LLG, et al. Gastroschisis: A systematic review of diagnosis, prognosis and treatment. *J Matern Fetal Neonatal Med* 2021;25:1–14. DOI: 10.1080/14767058.2021.1909563.
98. Lap CC, Brizot ML, Pistorius LR, et al. Outcome of isolated gastroschisis: An international study, systematic review and meta-analysis. *Early Hum Dev* 2016;103:209–218. DOI: 10.1016/j.earlhumdev.2016.10.002.
99. Bergholz R, Boettcher M, Reinshagen K, et al. Complex gastroschisis is a different entity to simple gastroschisis affecting morbidity and mortality: A systematic review and meta-analysis. *J Pediatr Surg* 2014;49(10):1527–1532. DOI: 10.1016/j.jpedsurg.2014.08.001.
100. Nitzsche K, Fitze G, Rudiger M, et al. Prenatal prediction of outcome by fetal gastroschisis in a tertiary referral center. *Diagnostics (Basel)* 2020;10(8):540. DOI: 10.3390/diagnostics10080540.
101. Dekonenko C, Fraser JD, Deans KJ, et al. Outcomes in gastroschisis: Expectations in the postnatal period for simple vs complex gastroschisis. *J Perinatol* 2021;41(7):1755–1759. DOI: 10.1038/s41372-021-01093-8.
102. Fisher SG, Anderson CM, Steinhardt NP, et al. It is complex: Predicting gastroschisis outcomes using prenatal imaging. *J Surg Res* 2021;258:381–388. DOI: 10.1016/j.jss.2020.08.067.
103. McClellan EB, Shew SB, Lee SS, et al. Liver herniation in gastroschisis: Incidence and prognosis. *J Pediatr Surg* 2011;46(11):2115–2118. DOI: 10.1016/j.jpedsurg.2011.07.010.
104. D'Antonio F, Virgone C, Rizzo G, et al. Prenatal risk factors and outcomes in gastroschisis: A meta-analysis. *Pediatrics* 2015;136(1):e159–e69. DOI: 10.1542/peds.2015-0017.
105. Davis RP, Treadwell MC, Drongowski RA, et al. Risk stratification in gastroschisis: can prenatal evaluation or early postnatal factors predict outcome? *Pediatr Surg Int* 2009;25(4):319–325. DOI: 10.1007/s00383-009-2342-x.
106. Koivusalo A, Lindahl H, Rintala RJ. Morbidity and quality of life in adult patients with a congenital abdominal wall defect: A questionnaire survey. *J Pediatr Surg* 2002;37(11):1594–1601. DOI: 10.1053/jpsu.2002.36191.
107. McNelis K, Poindexter A, Goddard G, et al. Body composition of infants with congenital gastroschisis. *J Pediatr Gastroenterol Nutr* 2022;74(2):e35–e38. DOI: 10.1097/MPG.0000000000003288.
108. Harris EL, Hart SJ, Minutillo C, et al. The long-term neurodevelopmental and psychological outcomes of gastroschisis: A cohort study. *J Pediatr Surg* 2016;51(4):549–553. DOI: 10.1016/j.jpedsurg.2015.08.062.



# Enteroviral Infections in Infants

Srijan Singh<sup>1</sup>, Sushant Satish Mane<sup>2</sup>, Gangajal Kasniya<sup>3</sup>, Sofia Cartaya<sup>4</sup>, Mohd Mujibur Rahman<sup>5</sup>, Akhil Maheshwari<sup>6</sup>, Mario Motta<sup>7</sup>, Pradeep Dudeja<sup>8</sup>

Received on: 14 September 2022; Accepted on: 14 September 2022; Published on: 07 October 2022

## ABSTRACT

Enteroviruses (EVs) are major pathogens in young infants. These viruses were traditionally classified into the following four subgenera: polio, coxsackie A and B, and echoviruses. Now that poliomyelitis seems to be controlled in most parts of the world, coxsackie and echoviruses are gaining more attention because (i) the structural and pathophysiological similarities and (ii) the consequent possibilities in translational medicine. Enteroviruses are transmitted mainly by oral and fecal–oral routes; the clinical manifestations include a viral prodrome including fever, feeding intolerance, and lethargy, which may be followed by exanthema; aseptic meningitis and encephalitis; pleurodynia; myopericarditis; and multi-system organ failure. Laboratory diagnosis is largely based on reverse transcriptase–polymerase chain reaction, cell culture, and serology. Prevention and treatment can be achieved using vaccination, and administration of immunoglobulins and antiviral drugs. In this article, we have reviewed the properties of these viruses, their clinical manifestations, and currently available methods of detection, treatment, and prognosis.

**Keywords:** Coxsackie virus, Enteroviruses, Neonate, Newborn.

*Newborn* (2022): 10.5005/jp-journals-11002-0036

## INTRODUCTION

Enteroviruses belong to the Picornaviridae family of viruses.<sup>1</sup> In infants, these pathogens can cause varied clinical manifestations, including hand, foot, and mouth disease; respiratory illness; myocarditis; meningitis; and sepsis; and even lethal multi-system organ failure. These viruses are transmitted primarily from one person to another.<sup>2</sup>

Enteroviruses were identified as a distinct class of viruses in 1957.<sup>3</sup> These pathogens were named based on their natural enteric habitat.<sup>3</sup> Many serotypes were identified based upon neutralization with specific antisera and with polymerase chain reactions,<sup>4</sup> and were initially classified into the following four subgenera:<sup>2</sup> (a) Polioviruses (serotypes 1–3); (b) Coxsackieviruses (CVs) group A (CV-A; serotypes 1–22 and 24); (c) CV-B; serotypes 1–6); and (d) echoviruses (serotypes 1–9, 11–21, 24–27, and 29–33). Newer classifications divide EVs into four species, A–D, based on the regions of the viral RNA that encode for the VP1 capsid protein.<sup>5</sup> Serotypes added after 1970 are simply named as EVs with a species designation (such as EV-D68) (Table 1).<sup>6</sup> New serotypes are being continuously added and the number now exceeds more than 100.<sup>7,8</sup> Now that poliomyelitis seems to be better controlled, the CVs and the echoviruses are receiving more attention.

## VIROLOGY

Enteroviruses are small (approximately 27 nm), non-enveloped virions with an icosahedral capsid with 60 subunits, each formed from four proteins (from VP1 to VP4).<sup>9</sup> Each virion has a linear, single-stranded, positive-sense RNA genome of about 7.5 kB (Fig. 1).<sup>10</sup> We have developed a standardized 16-component table to describe viral pathogens. Detailed information is available for some of these components in EVs (Table 2).

## Intracellular Replication

Enteroviruses replication is initiated by attachment to cell membrane receptors which determine host cell susceptibility.<sup>11</sup>

<sup>1,2</sup>Department of Pediatrics, Grant Government Medical College and Sir JJ Group of Hospitals, Mumbai, Maharashtra, India

<sup>3</sup>Department of Pediatrics, Cohen Children's Medical Center, New Hyde Park, New York, United States of America

<sup>4</sup>Department of Pediatrics, University of South Florida, Tampa, Florida, United States of America

<sup>5</sup>Department of Neonatology, Institute of Child and Mother Health, Dhaka, Bangladesh

<sup>6</sup>Global Newborn Society, Clarksville, Maryland, United States of America

<sup>7</sup>Neonologia e Terapia Intensiva Neonatale ASST Spedali Civili di Brescia, Italy

<sup>8</sup>Department of Gastroenterology, University of Illinois at Chicago, Illinois, United States of America

**Corresponding Author:** Srijan Singh, Department of Pediatrics, Grant Government Medical College and Sir JJ Group of Hospitals, Mumbai, Maharashtra, India, Phone: +91 9953537342, e-mail: srijanstar89@gmail.com

**How to cite this article:** Singh S, Mane SS, Kasniya G, et al. Enteroviral Infections in Infants. *Newborn* 2022;1(3):297–305.

**Source of support:** This project was supported in part by the NIH awards DK054016 and DK092441 (PKD).

**Conflict of interest:** None

Penetration and uncoating of the virions lead to the release of RNA into the cell cytoplasm and synthesis of negative-strand RNA begins within 30 minutes.<sup>12</sup> The newly formed positive-strand RNAs serve as a message for translation and are incorporated into newly formed virions. Complete virions can be seen by electron microscopy within hours.<sup>13</sup>

Coxsackieviruses and echoviruses are non-enveloped virions with an icosahedral capsid structure containing linear single-stranded RNA (Fig. 1).<sup>10</sup> As described above, group A has 23 serotypes (1–22 and 24). Coxsackieviruses-B are usually classified into 6 serotypes (1–6), namely, the CV-B1, CV-B2, CV-B3, CV-B4, CV-B5, and CV-B6.<sup>14</sup>

**EPIDEMIOLOGY**

**Seasonal and Demographic Distribution**

Enteroviruses infections occur throughout the year in warmer regions. This differs from the temperate climates, where the incidence is higher in summer and fall.<sup>15</sup> Infants are most susceptible, particularly males.<sup>16</sup> The incubation periods for enterovirus infections vary with different clinical syndromes.<sup>17</sup>

**Transmission**

Transmission of EVs occurs mainly by oral and fecal–oral routes.<sup>13</sup> It is enhanced by poor sanitary conditions, contaminated water, food, and fomites.<sup>18</sup> Flies appear to be a significant vector in situations of poor sanitation and heavy human infection.<sup>19</sup> Swimming pools are

a major channel of spread during summer.<sup>20</sup> Respiratory route is an important mode of transmission for some serotypes, including CV A21 and EV-D68.<sup>21</sup> Moreover, EV-D70 is shed with tears and spreads via fingers and fomites.<sup>22</sup> There is a high incidence of secondary infection in household contacts, especially in infants.<sup>23</sup>

Furthermore, CV-B affects infants of both genders with equal incidence. Compared to older children and adults, neonates and young infants may be affected more frequently and with higher severity of the disease.<sup>24</sup> Also, CV-B4 has higher mortality than other serotypes. Moreover, CV-B virus is the major cause of viral myocarditis, especially in neonates and younger children.<sup>1,25</sup> The prevalence of echovirus excretion in the community resembles the general population. Most transmission is vertical, from the mother to her fetus/newborn.<sup>26</sup>

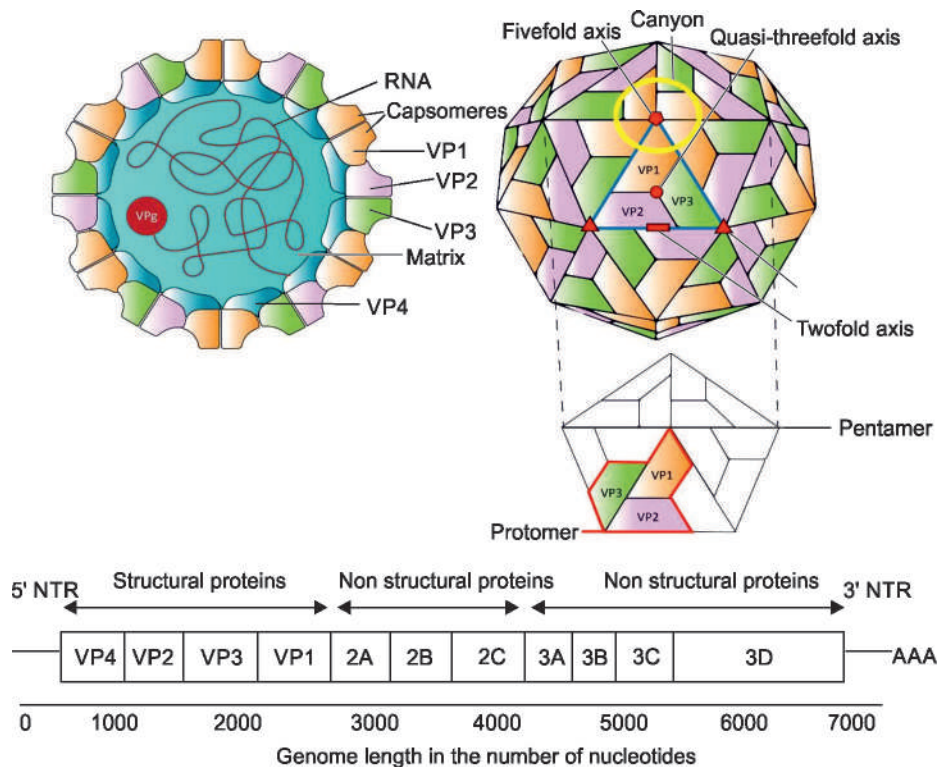
**Table 1:** Genomic classification of EVs

| Species designation         | Types   |
|-----------------------------|---|
| Human enterovirus A (HEV-A) | CV A2–8, A10, A12, A14, and A16<br>EV A71, A76, A89, A90, A91, A114, and A119   |
| Human enterovirus B (HEV-B) | CV A9<br>CV B1–6<br>Echovirus 1–9, 11–21, 24–27, and 29–33<br>Enterovirus 69, B73–B75, B77–B78, B93, B97, B98, B100, B101, B106, and B107 |
| Human enterovirus C (HEV-C) | Poliovirus 1–3<br>CV A1, A11, A13, A17, A19–22, and A24<br>Enterovirus C95, C96, C99, C102, C104, C105, C109, C113, C116–118              |
| Human enterovirus D (HEV-D) | Enterovirus D68, D70, D94, and D111   |

**PATHOPHYSIOLOGY**

These virions penetrate the cell surface, get uncoated, and the viral genome functions as mRNA for the viral polyprotein (Fig. 2). The polyprotein has three domains, from P1 to P3, which are cleaved into three to four proteins each. Domain P1 is liberated from the polyprotein by 2A protein and gets split into three proteins, VP0, VP1, and VP3, by 3C protease. Protein VP0 is processed further into smaller proteins, VP4 and VP2. They form eight-stranded antiparallel  $\beta$ -sheets. The amino acids in the loops that connect the  $\beta$ -strands and the N-terminal and C-terminal sequences that extend from the  $\beta$ -barrel domain of VP1, VP2, and VP3 give the EVs their distinct antigenicity.<sup>27</sup>

The coxsackie–adenovirus receptor (CAR) and the decay-accelerating factor (DAF) are receptors involved in the pathogenesis of coxsackie B virus infections.<sup>27</sup> Interaction of CV-B with CAR and



**Fig. 1:** Schematic diagram showing the structure of EVs. Left-side of the schematic panel shows a cross-section with the location of the RNA, capsomeres, the matrix, and the viral proteins (VPs); Right-side of the schematic panel shows the surface with the location of structural and non-structural VPs on the surface of viral particles



**Table 2:** List of major structural components of EVs have been listed (we have used a standardized table developed to describe viral pathogens)

| Structure                     | Available information  |
|-------------------------------|--|
| Lipid envelope                | EVs are small, spherical viruses made up of an RNA genome surrounded by a protein shell. These viruses lack a "membrane." <sup>87</sup>  |
| Glycoproteins                 | Proteins such as A9 and 3A are important; interact with host secretory carrier membrane protein 3 and participate in viral replication. <sup>87</sup>  |
| Receptor-binding motifs       | The arginine–glycine–aspartic acid (RGD) motif found in the VP1 capsid protein of CV-A9 has a role in cell entry. This motif binds integrins to promote entry into the cells. <sup>88</sup>  |
| Envelope protein E            | Either not expressed or relevance unclear in fetal/infantile disease.  |
| Membrane protein              | Either not expressed or relevance unclear in fetal/infantile disease.  |
| MHC or HLA Proteins           | Either not expressed or relevance unclear in fetal/infantile disease.  |
| Spike protein                 | Either not expressed or relevance unclear in fetal/infantile disease.  |
| Surface tubules               | Lipid droplets (LDs) are transported to lysosomes by autophagy. Lipases are recruited to the LD surface for sequential hydrolysis of TGs stored within LDs. After enterovirus infection, TGs within LDs transformed into fatty acids. <sup>89</sup>                  |
| Palisade layer                | Either not expressed or relevance unclear in fetal/infantile disease.  |
| Viral tegument                | Either not expressed or relevance unclear in fetal/infantile disease.  |
| Lateral bodies                | Either not expressed or relevance unclear in fetal/infantile disease.  |
| Capsid                        | EVs are small (approximately 27 nm), non-enveloped virions with an icosahedral capsid with 60 subunits, each formed from four proteins (VP1 to VP4). <sup>9</sup>  |
| Capsomeres                    | Viral polyprotein domains (from P1 to P3) are cleaved into 3–4 domains each; P1 is liberated from the polyprotein by 2A protein. Amino acids in the loops that extend from the $\beta$ -barrel domain of VP1, VP2, and VP3 give the EVs their distinct antigenicity. |
| Core membrane                 | Either not expressed or relevance unclear in fetal/infantile disease. <sup>9</sup>   |
| Protein core                  | Details on genome-associated polyprotein are described below.  |
| Core fibrils                  | Either not expressed or relevance unclear in fetal/infantile disease.  |
| Matrix                        | Virions penetrating the cell surface get uncoated and the viral genome functions as mRNA for the viral polyprotein. <sup>90</sup>  |
| Enzymes                       | Details scant. Alter the expression of host enzymes. <sup>91</sup>   |
| RNA elements                  | Enteroviral 3' non-translated regions (3'NTR) are comprised of two (X and Y) hairpin structures. <sup>92</sup>   |
| Nucleus                       | Either not expressed or relevance unclear in fetal/infantile disease.  |
| Nucleosome                    | Either not expressed or relevance unclear in fetal/infantile disease.  |
| DNA                           | No DNA genome exists   |
| RNA                           | The enteroviral genome (7.5-8 kb) is flanked by a 5'-UTR that is composed of an RNA cloverleaf structure and an internal ribosomal entry site (IRES). <sup>5,9</sup>   |
| Genome-associated polyprotein | A single polyprotein is cleaved by the host and viral protease into 4 capsid VP proteins and 7 non-structural proteins. The capsid protein VP1 varies and confers antigenic properties. <sup>93</sup>  |
| RNA polymerase                | The RNA-dependent RNA polymerase (RdRP), known as 3D protein, functions as a replica for viral RNA synthesis in infected cells. <sup>94</sup>  |
| Reverse transcriptase         | Either not expressed or relevance unclear in fetal/infantile disease.  |
| Head                          | Either not expressed or relevance unclear in fetal/infantile disease.  |
| Base plate                    | Either not expressed or relevance unclear in fetal/infantile disease.  |
| Integrase                     | Either not expressed or relevance unclear in fetal/infantile disease.  |
| Tail                          | Either not expressed or relevance unclear in fetal/infantile disease.  |
| Tail fiber                    | Either not expressed or relevance unclear in fetal/infantile disease.  |
| Neck                          | Either not expressed or relevance unclear in fetal/infantile disease.  |

HLA, human leukocyte antigens; MHC, major histocompatibility complex; TGs, triglycerides

DAF leads to the pathogenesis of various clinical manifestations, especially acute and chronic myocarditis. The CAR is expressed in the intercalated discs in the heart. DAF is expressed mostly in epithelial and endothelial cells. Interaction of cardiotropic CV-B with DAF and CAR enhances viral entry into myocardial cells and is responsible for myocarditis.<sup>28</sup> Pathogenesis of CNS infections may involve hematogenous spread or axonal transport. Also, CV-B is subdivided into the following two DAF-binding phenotypes: The

CV-B that does not bind to DAF (CV-B2, 4, and 6) and the CV-B that binds to DAF and requires CAR for infection.

Echoviruses bind to integrin  $\alpha_v\beta_3$  (vitronectin receptor; serotypes 1, 9),<sup>29</sup> integrin  $\alpha_2\beta_1$  (serotypes 1 and 8), and the human neonatal Fc receptor (FcRn; binds serotypes 5–7, 9, 11, 13, and 30).<sup>30</sup> Moreover, FcRn is a pan-echovirus receptor; it is expressed in the placenta, intestinal epithelium, hepatocytes, and cerebral endothelial cells. This pattern of expression is consistent with the

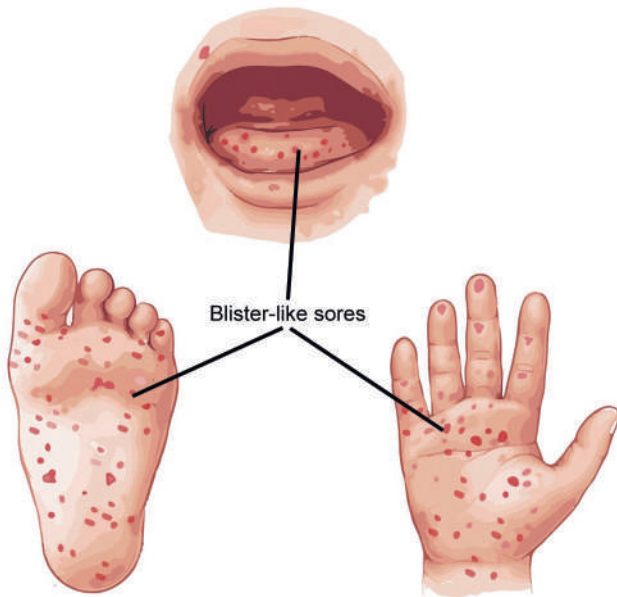
organ sites targeted by echoviruses, as the primary entry site of infection is the intestinal, and secondary sites of infection include the liver and brain.<sup>31</sup>

**Host Factors**

Neonates are predisposed to infections with CV-B and certain serotypes of echovirus (such as 11). Vertical transmission is more common than postnatal transmission. Infection is more frequent in seasonal community outbreaks of CV-B disease. Neonates are predisposed to severe infections with EVs, but the involved mechanisms are still not known.<sup>32</sup> The relative functional inability

of neonatal macrophages and dysregulated cytokine/chemokine responses have been implicated.<sup>33</sup>

Passively acquired antibodies from mothers seem to be protective against serious disease and death.<sup>34</sup> Infants with transplacental acquired antibodies have relatively asymptomatic infections. The timing of the mother's infection determines the outcome of neonatal CV-B infection. Maternal infections beginning more than 5–7 days before delivery allow transplacental passage of specific immunoglobulin G (IgG) antibodies and prevents severe neonatal disease. Infants with maternal infections in the immediate peripartum period have a relatively poor prognosis. The clinical expression of neonatal CV-B disease depends on the timing of maternal infection, age, and passively acquired maternal antibodies.



**Fig. 2:** An artist's recall of vesico–bullous (blister-like) sores in hand, foot, and mouth disease.

**CLINICAL MANIFESTATIONS**

These viruses can cause a range of clinical manifestations including fever, lethargy, myalgia, ileus, and diarrhea; exanthemata; aseptic meningitis and encephalitis; pleurodynia; and myopericarditis.

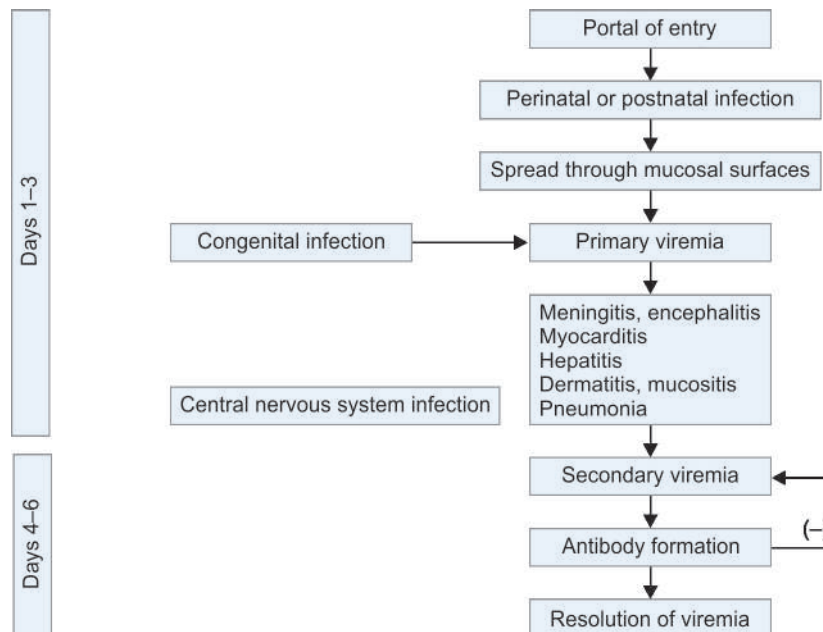
**Hand, Foot, and Mouth Disease (HFMD)**

The HFMD is a common illness in children characterized by fever, vesicles on the buccal mucosa and tongue, and tender cutaneous lesions on the hands, feet, buttocks, and genitalia (Flowchart 1).<sup>35</sup> Moreover, EV-A71 is the most frequently seen causative organism and can be associated with encephalitis, pulmonary edema and heart failure.<sup>36,37</sup> An atypical presentation of HFMD characterized by vesiculobullous lesions is caused by CV-A6.<sup>38,39</sup> Echovirus serotypes 3 and 33 have also been isolated.<sup>40,41</sup>

**Herpangina**

The CVs are a major cause of herpangina, a vesicular enanthem of the in the oral cavity.<sup>42</sup> Echoviruses can also rarely be the causative agents. It affects infants only when they have

**Flowchart 1:** Temporal evolution of enterovirus infections before and after birth



reached the age of 3 years or more of age and is more common in summers.<sup>43</sup> Sore throat, fever, and odynophagia are the predominant symptoms.

### Maculopapular Eruptions

Generalized maculopapular eruptions are seen with EV infections.<sup>44,45</sup> The “Boston exanthem” is a febrile 24–36-hour prodrome followed by the appearance of small, non-pruritic, pink maculopapular eruptions on the face and upper chest.<sup>46</sup> Patechial and purpuric rashes have been associated with echoviruses 9 and 25 and CV-A9 infections.<sup>44,47,48</sup>

### Urticaria-like Eruptions

Cutaneous manifestations of CV A9 and some echoviruses can range from *urticarial*, scarlatiniform, vesicular, pustular, and/or patechial lesions.<sup>49</sup>

### Central Nervous System Infections

Acute CNS infection occurs at all ages. Aseptic meningitis is the most common CNS manifestation. Polioviruses, EV-D68, and EV-A71 target motor nuclei within the brainstem and spinal cord, causing acute paresis of cranial and spinal nerves. The CV-A2 and echovirus 9 have also been identified.<sup>50,51</sup>

### Myocarditis

The CV-B types 2, 3, 4, and 5 are the most common causes of neonatal myocarditis.<sup>5,50,52,53</sup> Onset of symptoms is generally before day 10 of life. It has a biphasic presentation. Non-specific signs and symptoms of lethargy, poor feeding, or mild respiratory distress precede the onset of myocarditis by 2–5 days.<sup>54</sup> These infants continue to have respiratory distress, tachycardia, jaundice, and diarrhea. There may also be temperature instability, tachycardia, arrhythmias, hepatomegaly, and poor perfusion. The EKGs show low voltage and other electrophysiologic abnormalities. Echocardiographic studies indicate poor left ventricular or biventricular function.

Infants with CV-B myocarditis may have concomitant meningoencephalitis, pneumonia, hepatitis, pancreatitis, and adrenalitis. Mortality among infants with myocarditis alone is around 30–50% and is higher in cases with multisystem involvement. Meningoencephalitis may manifest with altered sensorium, seizures, flaccid paralysis, and coma.

Echovirus infections have been associated with neonatal hepatitis. Congenital infections with echovirus 11, 21, and 30 can cause fulminant neonatal hepatitis, which can be lethal.<sup>55,56</sup> Echovirus 6 has been associated with fever, respiratory distress, sepsis-like syndrome, acute respiratory and renal failure, and disseminated intravascular coagulopathy. Autopsy studies have shown jaundice, anasarca, massive hepatic necrosis, adrenal hemorrhagic necrosis, renal medullary hemorrhage, hemorrhagic non-inflammatory pneumonia, and severe encephalomalacia.<sup>56</sup>

The histopathology of neonatal EV infections typically shows diffuse or scattered lesions with perivascular infiltration, consisting of mononuclear cells and polymorphonuclear leukocytes in the cerebrum, cerebellum, pons, medulla, and spinal cord.

### Undifferentiated Fever and Aseptic Meningitis

Viral meningitis is most common in infants less than 1 year of age.<sup>15,16</sup> More than 90% of viral meningitis in infants is due to species B EVs (group B CVs and most echoviruses).

Neonates infected with CV-B are at risk for a severe systemic illness especially meningitis or meningoencephalitis.<sup>53</sup> Infection due to CV-B is a cause of 53–63% of the cases of fever without focus in infants less than 3 months of age.<sup>57,58</sup> The CV-B serotypes 2, 4, and 5 are most commonly identified in these infants. Infants may present with irritability, lethargy, poor feeding, vomiting, diarrhea, exanthems, and respiratory distress.<sup>59</sup> A sepsis screen can help rule out bacterial infection. The cerebrospinal fluid (CSF) study reveals aseptic meningitis in almost half of the infants with enterovirus infection.<sup>60</sup>

The CSF typically shows monocytic pleocytosis (100–1000 cells/mm<sup>3</sup>) with normal or decreased glucose and slightly increased protein levels. Most infants recover within 2–10 days without complications. Also, 10% of infants may progress to develop seizures, obtundation, or raised intracranial pressure. The short-term prognosis of enterovirus meningitis is good. It is not associated with long-term neurodevelopmental deficits in most patients.<sup>2</sup>

Overall, about 5% of all cases of acute encephalitis are caused by EVs.<sup>61</sup> The CV serotypes A9, B2, and B5, and echovirus serotypes 6 and 9 are frequently associated with encephalitis.

### Respiratory Tract Diseases

Many CV-B infections are accompanied by respiratory distress and non-specific radiological signs.<sup>62</sup> Echovirus 6 and CV-A serotypes 4, 6, 9, and 10 are other causative agents.<sup>56</sup>

### Ocular infections

Acute hemorrhagic conjunctivitis is a highly contagious but self-limited ocular infection. A CV-A24 variant is responsible for outbreaks.<sup>63</sup> Transmission is by eye discharge, fingers, and fomites. Symptoms peak in 2–3 days and it resolves within 10 days without complication.

### Hepatitis

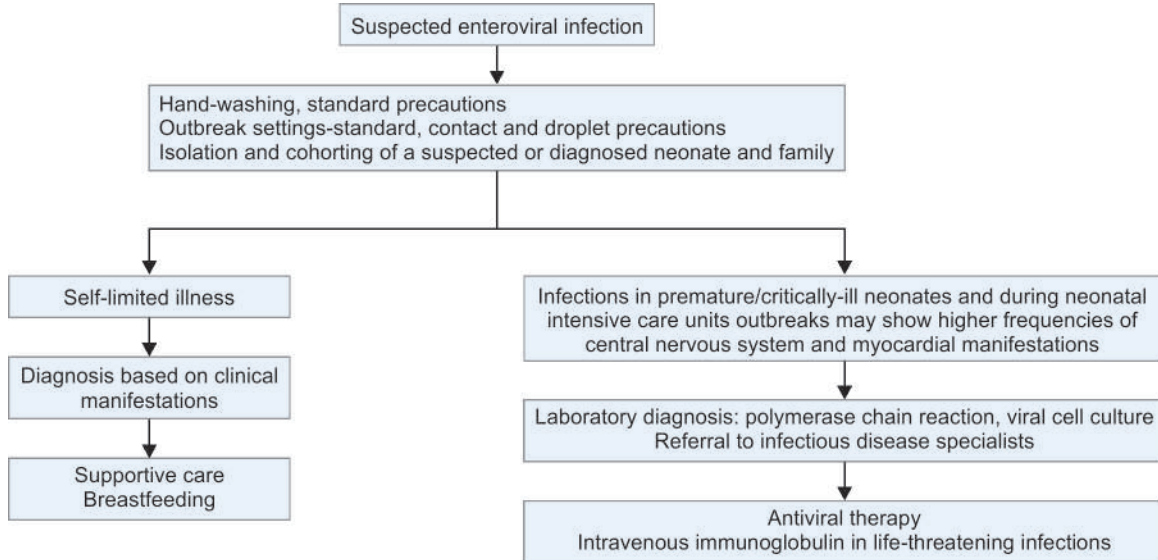
Echoviruses, particularly serotypes 5–7, 9, 11, 14, 19–21, and 30 may cause severe hepatitis with foci of hepatic necrosis.<sup>64</sup> Upper respiratory infection, general signs of sepsis-like illness, meningitis, gastroenteritis, aseptic meningitis, gastroenteritis, meningoencephalitis, and fatal interstitial pneumonia may be seen. No association was found between maternal echovirus serotype 9 infection and congenital malformations.<sup>65,66</sup> Echoviral infections can cause considerable mortality in epidemics.

### Cloud Baby

Echovirus 20 has been associated with Staphylococcal colonization and dissemination in nurseries. Eichenwald and associates identified this phenomenon and named these infants as “cloud babies.” Active staphylococcal dissemination occurred only during the time that echovirus 20 was recovered from the nasopharynx; hence, viral-bacterial synergism was postulated as a mechanism.

## DIAGNOSIS

Most EV cause self-limited illnesses and are diagnosed based on clinical manifestations. A laboratory diagnosis is required when the identification of the causative organism has management implications as in central nervous system infections, myopericarditis, and in neonates and immunocompromised patients. Laboratory diagnosis is also required in disease outbreaks.

**Flowchart 2:** Algorithm for management of a neonate with suspected enteroviral infection

## LAB DIAGNOSIS

### Reverse Transcriptase–Polymerase Chain Reaction

Detection of virus in the blood, CSF, pericardial fluid, lacrimal fluid, urine, respiratory secretions, or tissue by reverse transcriptase polymerase chain reaction (RT-PCR) is diagnostic of infection.<sup>67–70</sup> A positive RT-PCR test from stool may represent the carrier state. In CSF, RT-PCR is more rapid and sensitive than cell culture.

### Viral Isolation (Cell Culture)

For serotype identification, specimens should be sent to a reference laboratory where an isolate can be amplified in cell culture and identified at the serotype level with special PCR primers or genomic sequencing.<sup>67–69</sup>

Cell culture is expensive and culture in multiple cell lines is required for optimal sensitivity. Recovery of an isolate in cell culture helps in its typing for clinical and epidemiologic purposes. The characteristic enterovirus cytopathic effect (CPE) requires 2–6 days to develop in primary cell culture.<sup>70,71</sup> Indirect immunofluorescence may be used to confirm the virus causing the CPE.<sup>71</sup>

### Serology

Serology is not generally used for the diagnosis of acute enteroviral illnesses except when infection with a specific serotype is suspected. The diagnosis of acute infection can be made retrospectively with a 4-fold or greater increase in antibody titers between acute and convalescent specimens separated by a minimum of 4 weeks. Serum IgM antibodies to the CV-B can often be detected early in the course of illness.<sup>72,73</sup> Type-specific immunoassays that measure the antibody response against the more common enterovirus serotypes are of limited utility due to cross-reactivity and standardization issues.

## MANAGEMENT

The management of CVB disease in the newborn is predominantly supportive care (Flowchart 2). The severity of disease and poor prognosis have generated interest in immunoglobulins (Ig) for the treatment of neonatal enterovirus infections.

### Antiviral Therapy for Severe Cases

Most enteroviral infections are self-limited and do not require specific therapy. Exceptions are fulminant neonatal infection, severe myocarditis, chronic infection, and disseminated infections in B cell-immunodeficient patients and hematologic malignancies.

### Antiviral Drugs

Antiviral drugs against EVs have limited availability. There are a few available options:

- Capsid inhibitors are drugs that inhibit viral attachment and uncoating. They have been shown to have activity against EVs. Pocopavir is an orally administered drug under development to treat chronic enterovirus infections, although resistance was quick to develop.<sup>74</sup> It is available only for poliovirus infections in B cell-deficient patients.
- Pleconaril, an orally administered capsid inhibitor, has been tested clinically against enterovirus and rhinovirus infections but is not currently available for systemic administration.<sup>75</sup>

### Intravenous (Ig)

There is no clear evidence of benefit. It may be used in life-threatening enteroviral infections but is not recommended for routine use.<sup>76</sup> A retrospective study showed that intravenous immune globulin (IVIg) increases survival.<sup>76</sup> However, a randomized controlled trial at a dose of 750 mg/kg found no clinical benefit.<sup>77</sup> There is also no convincing evidence of benefit in acute myocarditis. There is anecdotal, not convincing, evidence for the use of IVIg and maternal plasma transfusions in echovirus infections.<sup>78,79</sup>

## PREVENTION

### General Measures

Simple hygienic measures, such as hand washing, are important to prevent the spread of infection.<sup>80</sup> Alcohol-based hand sanitizers may not be optimally effective for EVs.<sup>81</sup> In hospitalized patients, standard precautions are indicated to control outbreaks.<sup>82</sup> In outbreak settings, standard contact and droplet precautions for suspect cases in healthcare settings have been recommended.

## Vaccines

Three inactivated enterovirus A71 vaccines have been tested in China for use in pediatric patients.<sup>83–85</sup> In a multi-center RCT in children aged from 2 to 71 months who received the B4 genotype-based enterovirus A71 vaccine, the vaccine efficacy was found to be 96.8%.<sup>86</sup>

## Pregnant Women

Neonatal CV-B infections are acquired in the peripartum period either from the mother or nosocomial sources. The risk of maternal infection late in gestation can be avoided by hand washing, especially after changing diapers and after close contact with objects contaminated by feces, urine, or respiratory secretions. Strict enforcement of recommended infection control practices for health care workers is warranted to reduce transmission in newborn nurseries. If feasible, the delivery may be delayed till 5–10 days after symptoms onset to allow the transplacental transfer of maternal IgG antibodies to improve outcomes.

## FUTURE DIRECTIONS

We need specific antivirals and vaccines targeting coxsackie virus infections in neonates. There is also a need for well-controlled trials to evaluate IVIG as a preventive measure against nosocomial transmission of EVs.

## ORCID

Srijan Singh  <https://orcid.org/0000-0002-2103-5232>

Akhil Maheshwari  <https://orcid.org/0000-0003-3613-4054>

## REFERENCES

1. Baggen J, Thibaut HJ, Strating J, et al. The life cycle of non-polio enteroviruses and how to target it. *Nat Rev Microbiol* 2018;16(6): 368–381. DOI: 10.1038/s41579-018-0005-4.
2. Hawkes MT, Vaudry W. Nonpolio enterovirus infection in the neonate and young infant. *Paediatr Child Health* 2005;10(7):383–388. PMID: 19668644.
3. Horstmann DM. Enterovirus infections: Etiologic, epidemiologic and clinical aspects. *Calif Med* 1965;103:1–8. PMID: 14336786.
4. Oberste MS, Maher K, Williams AJ, et al. Species-specific RT-PCR amplification of human enteroviruses: A tool for rapid species identification of uncharacterized enteroviruses. *J Gen Virol* 2006;87 (Pt. 1):119–128. DOI: 10.1099/vir.0.81179-0.
5. Oberste MS, Maher K, Kilpatrick DR, et al. Molecular evolution of the human enteroviruses: Correlation of serotype with VP1 sequence and application to picornavirus classification. *J Virol* 1999;73(3):1941–1948. DOI: 10.1128/JVI.73.3.1941-1948.1999.
6. National Collaborating Centre for Infectious Diseases C. EV-D68. University of Manitoba. Available at: <https://nccid.ca/debrief/ev-d68/> Accessed on: 23 August 2022.
7. Tapparel C, Siegrist F, Petty TJ, et al. Picornavirus and enterovirus diversity with associated human diseases. *Infect Genet Evol* 2013;14:282–293. DOI: 10.1016/j.meegid.2012.10.016.
8. Pons-Salort M, Parker EP, Grassly NC. The epidemiology of non-polio enteroviruses: Recent advances and outstanding questions. *Curr Opin Infect Dis* 2015;28(5):479–487. DOI: 10.1097/QCO.0000000000000187.
9. Jiang P, Liu Y, Ma HC, et al. Picornavirus morphogenesis. *Microbiol Mol Biol Rev* 2014;78(3):418–437. DOI: 10.1128/MMBR.00012-14.
10. Payne S. Introduction to RNA viruses. *Viruses* 2017;97–105. DOI: 10.1016/B978-0-12-803109-4.00010-6.
11. Laitinen OH, Svedin E, Kapell S, et al. Enteroviral proteases: Structure, host interactions and pathogenicity. *Rev Med Virol* Jul 2016;26(4): 251–267. DOI: 10.1002/rmv.1883.
12. Groppelli E, Levy HC, Sun E, et al. Picornavirus RNA is protected from cleavage by ribonuclease during virion uncoating and transfer across cellular and model membranes. *PLoS Pathog* 2017;13(2):e1006197. DOI: 10.1371/journal.ppat.1006197.
13. Wells AI, Coyne CB. Enteroviruses: A gut-wrenching game of entry, detection, and evasion. *Viruses* 2019;11(5):460. DOI: 10.3390/v11050460.
14. Stone VM, Hankaniemi MM, Laitinen OH, et al. A hexavalent coxsackievirus B vaccine is highly immunogenic and has a strong protective capacity in mice and nonhuman primates. *Sci Adv* 2020;6(19):eaaz2433. DOI: 10.1126/sciadv.aaz2433.
15. Lugo D, Krogstad P. Enteroviruses in the early 21st century: New manifestations and challenges. *Curr Opin Pediatr* 2016;28(1):107–113. DOI: 10.1097/MOP.0000000000000303.
16. Olchawa-Czech A, Ptak K, Szymonska I, et al. Severe enterovirus infections in infants <3 months of age and the importance of medical history. *J Mother Child* 2021;24(3):37–44. DOI: 10.34763/jmotherandchild.20202403.2022.d-20-00007.
17. Bopegamage S. Enterovirus infections: Pivoting role of the adaptive immune response. *Virulence* 2016;7(5):495–497. DOI: 10.1080/21505594.2016.1175701.
18. Rodriguez-Lazaro D, Cook N, Ruggeri FM, et al. Virus hazards from food, water and other contaminated environments. *FEMS Microbiol Rev* 2012;36(4):786–814. DOI: 10.1111/j.1574-6976.2011.00306.x.
19. Tiwari S, Dhole TN. Assessment of enteroviruses from sewage water and clinical samples during eradication phase of polio in North India. *Virol J* 2018;15(1):157. DOI: 10.1186/s12985-018-1075-7.
20. Keswick BH, Gerba CP, Goyal SM. Occurrence of enteroviruses in community swimming pools. *Am J Public Health*. 1981;71(9): 1026–1030. DOI: 10.2105/ajph.71.9.1026.
21. Imamura T, Oshitani H. Global reemergence of enterovirus D68 as an important pathogen for acute respiratory infections. *Rev Med Virol* 2015;25(2):102–114. DOI: 10.1002/rmv.1820.
22. Noor A, Krilov LR. Enterovirus Infections. *Pediatr Rev* 2016;37(12): 505–515. DOI: 10.1542/pir.2016-0103.
23. Chang LY, Tsao KC, Hsia SH, et al. Transmission and clinical features of enterovirus 71 infections in household contacts in Taiwan. *JAMA* 2004;291(2):222–227. DOI: 10.1001/jama.291.2.222.
24. Yen M, Tsao H, Huang Y, et al. Viral load in blood is correlated with disease severity of neonatal coxsackievirus B3 infection: Early diagnosis and predicting disease severity is possible in severe neonatal enterovirus infection. *Clin Infect Dis* 2007;44(10):e78–e81. DOI: 10.1086/515399.
25. Moore M, Kaplan MH, McPhee J, et al. Epidemiologic, clinical, and laboratory features of coxsackie B1–B5 infections in the United States, 1970–1979. *Public Health Rep* 1984;99(5):515–522. PMID: 6091168.
26. Modlin JF, Polk BF, Horton P, et al. Perinatal echovirus infection: Risk of transmission during a community outbreak. *N Engl J Med* 1981;305(7):368–371. DOI: 10.1056/NEJM198108133050703.
27. Hendry E, Hatanaka H, Fry E, et al. The crystal structure of coxsackievirus A9: New insights into the uncoating mechanisms of enteroviruses. *Structure* 1999;7(12):1527–1538. DOI: 10.1016/S0969-2126(00)88343-4.
28. Selinka HC, Wolde A, Sauter M, et al. Virus-receptor interactions of coxsackie B viruses and their putative influence on cardiotropism. *Med Microbiol Immunol* 2004;193(2–3):127–131. DOI: 10.1007/s00430-003-0193-y.
29. Nelsen-Salz B, Eggers HJ, Zimmermann H. Integrin  $\alpha(v)\beta3$  (vitronectin receptor) is a candidate receptor for the virulent echovirus 9 strain Barty. *J Gen Virol* 1999;80(Pt. 9):2311–2313. DOI: 10.1099/0022-1317-80-9-2311.
30. Jokinen J, White DJ, Salmela M, et al. Molecular mechanism of  $\alpha2\beta1$  integrin interaction with human echovirus 1. *EMBO J* 2010;29(1):196–208. DOI: 10.1038/emboj.2009.326.




31. Morosky S, Wells AI, Lemon K, et al. The neonatal Fc receptor is a pan-echovirus receptor. *Proc Natl Acad Sci U S A* 2019;116(9):3758–3763. DOI: 10.1073/pnas.1817341116.
32. Modlin JF. Treatment of neonatal enterovirus infections. *J Pediatric Infect Dis Soc* 2016;5(1):63–64. DOI:10.1093/jpids/piv030.
33. Gong X, Zhou J, Zhu W, et al. Excessive proinflammatory cytokine and chemokine responses of human monocyte-derived macrophages to enterovirus 71 infection. *BMC Infect Dis* 2012;12:224. DOI: 10.1186/1471-2334-12-224.
34. Wei X, Yang J, Gao L, et al. The transfer and decay of maternal antibodies against enterovirus A71, and dynamics of antibodies due to later natural infections in Chinese infants: A longitudinal, paired mother–neonate cohort study. *Lancet Infect Dis* 2021;21(3):418–426. DOI: 10.1016/S1473-3099(20)30480-1.
35. Chen B, Yang Y, Xu X, et al. Epidemiological characteristics of hand, foot, and mouth disease in China: A meta-analysis. *Medicine (Baltimore)* 2021;100(20):e25930. DOI: 10.1097/MD.00000000000025930.
36. Alexander JP Jr, Baden L, Pallansch MA, et al. Enterovirus 71 infections and neurologic disease—United States, 1977–1991. *J Infect Dis* 1994;169(4):905–908. DOI: 10.1093/infdis/169.4.905.
37. Lum LC, Wong KT, Lam SK, et al. Fatal enterovirus 71 encephalomyelitis. *J Pediatr* 1998;133(6):795–798. DOI: 10.1016/S0022-3476(98)70155-6.
38. Feder HM Jr, Bennett N, Modlin JF. Atypical hand, foot, and mouth disease: A vesiculobullous eruption caused by coxsackie virus A6. *Lancet Infect Dis* 2014;14(1):83–86. DOI: 10.1016/S1473-3099(13)70264-0.
39. Stewart CL, Chu EY, Introcaso CE, et al. Coxsackievirus A6-induced hand–foot–mouth disease. *JAMA Dermatol* 2013;149(12):1419–1421. DOI: 10.1001/jamadermatol.2013.6777.
40. Davia JL, Bel PH, Ninet VZ, et al. Onychomadesis outbreak in Valencia, Spain associated with hand, foot, and mouth disease caused by enteroviruses. *Pediatr Dermatol*. 2011;28(1):1–5. DOI: 10.1111/j.1525-1470.2010.01161.x.
41. Zhang J, Liu H, Zhao Y, et al. Identification of a new recombinant strain of echovirus 33 from children with hand, foot, and mouth disease complicated by meningitis in Yunnan, China. *Virol J* 2019;16(1):63. DOI: 10.1186/s12985-019-1164-2.
42. Bian L, Gao F, Mao Q, et al. Hand, foot, and mouth disease associated with coxsackievirus A10: more serious than it seems. *Expert Rev Anti Infect Ther* 2019;17(4):233–242. DOI: 10.1080/14787210.2019.1585242.
43. Li W, Gao HH, Zhang Q, et al. Large outbreak of herpangina in children caused by enterovirus in summer of 2015 in Hangzhou, China. *Sci Rep* 2016;6:35388. DOI: 10.1038/srep35388.
44. Sabin AB, Krumbiegel ER, Wigand R. ECHO type 9 virus disease. *AMA J Dis Child* 1958;96(2):197–219. DOI: 10.1001/archpedi.1958.02060060199011.
45. Bell EJ, Ross CA, Grist NR. ECHO 9 infection in pregnant women with suspected rubella. *J Clin Pathol* 1975;28(4):267–269. DOI: 10.1136/jcp.28.4.267.
46. Neva FA. A second outbreak of Boston exanthem disease in Pittsburgh during 1954. *N Engl J Med* 1956;254(18):838–843. DOI: 10.1056/NEJM195605032541806.
47. Frothingham TE. ECHO virus type 9 associated with three cases simulating meningococemia. *N Engl J Med* 1958;259(10):484–485. DOI: 10.1056/NEJM195809042591007.
48. Cherry JD, Jahn CL. Herpangina: The etiologic spectrum. *Pediatrics* 1965;36(4):632–634. PMID: 5834068.
49. Emer JJ, Bernardo SG, Kovalerchik O, et al. Urticaria multiforme. *J Clin Aesthet Dermatol* 2013;6(3):34–39.
50. Nagai T, Hanaoka N, Katano H, et al. A fatal case of acute encephalopathy in a child due to coxsackievirus A2 infection: A case report. *BMC Infect Dis* 2021;21(1):1167. DOI: 10.1186/s12879-021-06858-2.
51. Dalwai A, Ahmad S, Pacsa A, et al. Echovirus type 9 is an important cause of viral encephalitis among infants and young children in Kuwait. *J Clin Virol* 2009;44(1):48–51. DOI: 10.1016/j.jcv.2008.10.007.
52. Dancea AB. Myocarditis in infants and children: A review for the paediatrician. *Paediatr Child Health* 2001;6(8):543–545. DOI: 10.1093/pch/6.8.543.
53. Kaplan MH, Klein SW, McPhee J, et al. Group B coxsackievirus infections in infants younger than three months of age: A serious childhood illness. *Rev Infect Dis* 1983;5(6):1019–1032. DOI: 10.1093/clinids/5.6.1019.
54. Eichenwald HF, Shinefield HR. Viral infections of the fetus and of the premature and newborn infant. *Adv Pediatr* 1962;12:249–305. PMID: 13889553.
55. Pedrosa C, Lage MJ, Virella D. Congenital echovirus 21 infection causing fulminant hepatitis in a neonate. *BMJ Case Rep* 2013;2013 DOI: 10.1136/bcr-2012-008394.
56. Ventura KC, Hawkins H, Smith MB, Walker DH. Fatal neonatal echovirus 6 infection: Autopsy case report and review of the literature. *Mod Pathol* 2001;14(2):85–90. DOI: 10.1038/modpathol.3880260.
57. Leggiadro RJ, Darras BT. Viral and bacterial pathogens of suspected sepsis in young infants. *Pediatr Infect Dis* 1983;2(4):287–289. DOI: 10.1097/00006454-198307000-00006.
58. Krober MS, Bass JW, Powell JM, et al. Bacterial and viral pathogens cause fever in infants less than 3 months old. *Am J Dis Child* 1985;139(9):889–892. DOI: 10.1001/archpedi.1985.02140110043025.
59. Rorabaugh ML, Berlin LE, Heldrich F, et al. Aseptic meningitis in infants younger than 2 years of age: Acute illness and neurologic complications. *Pediatrics* 1993;92(2):206–211.
60. Modlin JF, Rotbart HA. Group B coxsackie disease in children. *Curr Top Microbiol Immunol* 1997;223:53–80. DOI: 10.1007/978-3-642-60687-8\_4.
61. Fowlkes AL, Honarmand S, Glaser C, et al. Enterovirus-associated encephalitis in the California encephalitis project, 1998–2005. *J Infect Dis* 2008;198(11):1685–1691. DOI: 10.1086/592988.
62. Chonmaitree T, Menegus MA, Powell KR. The clinical relevance of ‘CSF viral culture’. A two-year experience with aseptic meningitis in Rochester, NY. *JAMA* 1982;247(13):1843–1847.
63. Zhang L, Zhao N, Huang X, et al. Molecular epidemiology of acute hemorrhagic conjunctivitis caused by coxsackie A type 24 variant in China, 2004–2014. *Sci Rep* 2017;7:45202. DOI: 10.1038/srep45202.
64. Hughes JR, Wilfert CM, Moore M, et al. Echovirus 14 infection associated with fatal neonatal hepatic necrosis. *Am J Dis Child* 1972;123(1):61–67. DOI: 10.1001/archpedi.1972.02110070111017.
65. Kleinman H, Prince JT, Mathey WE, et al. ECHO 9 virus infection and congenital abnormalities: A negative report. *Pediatrics* 1962;29:261–269. PMID: 14456823.
66. Landsman JB, Grist NR, Ross CA. ECHO 9 virus infection and congenital malformations. *Br J Prev Soc Med* 1964;18:152–156. DOI: 10.1136/jech.18.3.152.
67. Mirand A, Henquell C, Archimbaud C, et al. Prospective identification of enteroviruses involved in meningitis in 2006 through direct genotyping in cerebrospinal fluid. *J Clin Microbiol* 2008;46(1):87–96. DOI: 10.1128/JCM.01020-07.
68. Nix WA, Oberste MS, Pallansch MA. Sensitive, seminested PCR amplification of VP1 sequences for direct identification of all enterovirus serotypes from original clinical specimens. *J Clin Microbiol* 2006;44(8):2698–2704. DOI: 10.1128/JCM.00542-06.
69. Oberste MS, Maher K, Kilpatrick DR, et al. Typing of human enteroviruses by partial sequencing of VP1. *J Clin Microbiol* 1999;37(5):1288–1293. DOI: 10.1128/JCM.37.5.1288-1293.1999.
70. Dagan R, Menegus MA. A combination of four cell types for rapid detection of enteroviruses in clinical specimens. *J Med Virol* 1986;19(3):219–228. DOI: 10.1002/jmv.1890190304.
71. Trabelsi A, Grattard F, Nejmeddine M, et al. Evaluation of an enterovirus group-specific anti-VP1 monoclonal antibody, 5-D8/1, in comparison with neutralization and PCR for rapid identification of enteroviruses in cell culture. *J Clin Microbiol* 1995;33(9):2454–2457. DOI: 10.1128/jcm.33.9.2454-2457.1995.





72. Bell EJ, McCartney RA, Basquill D, et al. Mu-antibody capture ELISA for the rapid diagnosis of enterovirus infections in patients with aseptic meningitis. *J Med Virol* 1986;19(3):213–217. DOI: 10.1002/jmv.1890190303.
73. Pozzetto B, Gaudin OG, Aouni M, et al. Comparative evaluation of immunoglobulin M neutralizing antibody response in acute-phase sera and virus isolation for the routine diagnosis of enterovirus infection. *J Clin Microbiol* 1989;27(4):705–708. DOI: 10.1128/jcm.27.4.705-708.1989.
74. Torres-Torres S, Myers AL, Klatte JM, et al. First use of investigational antiviral drug pocapavir (v-073) for treating neonatal enteroviral sepsis. *Pediatr Infect Dis J* 2015;34(1):52–54. DOI: 10.1097/INF.0000000000000497.
75. Pevear DC, Tull TM, Seipel ME, et al. Activity of pleconaril against enteroviruses. *Antimicrob Agents Chemother* 1999;43(9):2109–2115. DOI: 10.1128/AAC.43.9.2109.
76. Yen MH, Huang YC, Chen MC, et al. Effect of intravenous immunoglobulin for neonates with severe enteroviral infections with emphasis on the timing of administration. *J Clin Virol* 2015;64:92–96. DOI: 10.1016/j.jcv.2015.01.013.
77. Abzug MJ, Keyserling HL, Lee ML, et al. Neonatal enterovirus infection: Virology, serology, and effects of intravenous immune globulin. *Clin Infect Dis* 1995;20(5):1201–1206. DOI: 10.1093/clinids/20.5.1201.
78. Johnston JM, Overall JC Jr. Intravenous immunoglobulin in disseminated neonatal echovirus 11 infection. *Pediatr Infect Dis J* 1989;8(4):254–256. PMID: 2717278.
79. Jantusch BA, Luban NL, Duffy L, et al. Maternal plasma transfusion in the treatment of disseminated neonatal echovirus 11 infection. *Pediatr Infect Dis J* 1995;14(2):154–155. PMID: 7746702.
80. Ruan F, Yang T, Ma H, et al. Risk factors for hand, foot, and mouth disease and herpangina and the preventive effect of hand-washing. *Pediatrics* 2011;127(4):e898–e904. DOI: 10.1542/peds.2010-1497.
81. Chang SC, Li WC, Huang KY, et al. Efficacy of alcohols and alcohol-based hand disinfectants against human enterovirus 71. *J Hosp Infect* 2013;83(4):288–293. DOI:10.1016/j.jhin.2012.12.010.
82. Siegel JD, Rhinehart E, Jackson M, et al. 2007 Guideline for isolation precautions: Preventing transmission of infectious agents in healthcare settings. *Am J Infect Control* 2007;35(10 Suppl. 2):S65–164. DOI: 10.1016/j.ajic.2007.10.007.
83. Li Y, Zhou Y, Cheng Y, et al. Effectiveness of EV-A71 vaccination in prevention of paediatric hand, foot, and mouth disease associated with EV-A71 virus infection requiring hospitalisation in Henan, China, 2017–18: A test-negative case-control study. *Lancet Child Adolesc Health* 2019;3(10):697–704. DOI: 10.1016/S2352-4642(19)30185-3.
84. Wei M, Meng F, Wang S, et al. 2-Year efficacy, immunogenicity, and safety of Vigoo enterovirus 71 vaccine in healthy Chinese children: A randomized open-label study. *J Infect Dis* 2017;215(1):56–63. DOI: 10.1093/infdis/jiw502.
85. Li R, Liu L, Mo Z, et al. An inactivated enterovirus 71 vaccine in healthy children. *N Engl J Med* 2014;370(9):829–837. DOI: 10.1056/NEJMoa1303224.
86. Nguyen TT, Chiu CH, Lin CY, et al. Efficacy, safety, and immunogenicity of an inactivated, adjuvanted enterovirus 71 vaccine in infants and children: a multiregion, double-blind, randomised, placebo-controlled, phase 3 trial. *Lancet* 2022;399(10336):1708–1717. DOI: 10.1016/S0140-6736(22)00313-0.
87. Lu JY, Brewer G, Li ML, et al. Secretory carrier membrane protein 3 interacts with 3A viral protein of enterovirus and participates in viral replication. *Microbiol Spectr* 2021;9(1):e0047521. DOI: 10.1128/Spectrum.00475-21.
88. Shakeel S, Seitonen JJ, Kajander T, et al. Structural and functional analysis of coxsackievirus A9 integrin alphavbeta6 binding and uncoating. *J Virol* 2013;87(7):3943–3951. DOI: 10.1128/JVI.02989-12.
89. Laufman O, Perrino J, Andino R. Viral generated inter-organelle contacts redirect lipid flux for genome replication. *Cell* 2019;178(2):275–289.e16. DOI: 10.1016/j.cell.2019.05.030.
90. Louten J. Virus replication. *Essential Human Virol* 2016:49–70. DOI: 10.1016/B978-0-12-800947-5.00004-1.
91. Maciejewski S, Nguyen JH, Gomez-Herreros F, et al. Divergent requirement for a DNA repair enzyme during enterovirus infections. *mBio* 2015;7(1):e01931–15. DOI: 10.1128/mBio.01931-15.
92. Merkle I, van Ooij MJ, van Kuppeveld FJ, et al. Biological significance of a human enterovirus B-specific RNA element in the 3' nontranslated region. *J Virol* 2002;76(19):9900–9909. DOI: 10.1128/jvi.76.19.9900-9909.2002.
93. Yuan J, Shen L, Wu J, et al. Enterovirus A71 proteins: Structure and function. *Front Microbiol* 2018;9:286. DOI: 10.3389/fmicb.2018.00286.
94. Lee KM, Wu CC, Wu SE, et al. The RNA-dependent RNA polymerase of enterovirus A71 associates with ribosomal proteins and positively regulates protein translation. *RNA Biol* 2020;17(4):608–622. DOI: 10.1080/15476286.2020.1722448.

# Advancement of Enteral Feeding in Very-low-birth-weight Infants: Global Issues and Challenges

Krystle Perez<sup>1</sup>, Gregory Charles Valentine<sup>2</sup>, Sushma Nangia<sup>3</sup>, Douglas G Burrin<sup>4</sup>, Akhil Maheshwari<sup>5</sup>, Mahlet Abayneh<sup>6</sup>, Redeat Workneh<sup>7</sup>, Maggie Jerome<sup>8</sup>, N Alejandro Dinerstein<sup>9</sup>, Ariel Salas<sup>10</sup>

Received on: 10 July 2022; Accepted on: 15 September 2022; Published on: 07 October 2022

## ABSTRACT

In very-low-birth-weight (VLBW) infants, the initiation of enteral feedings is frequently delayed and the feeding volumes are advanced very slowly. Clinicians often express concerns about gut immaturity and consequent increased risk of feeding intolerance, spontaneous intestinal perforation (SIP), and necrotizing enterocolitis (NEC). Late initiation and ultracautious advancement of enteral feedings are seen all over the world, despite known associations with a prolonged need for central venous access and increased risk of sepsis, which is one of the leading causes of neonatal mortality. Promoting early establishment of full enteral feeding, particularly when maternal or donor milk is available, can improve neonatal outcomes, particularly the incidence of central-line-associated bacterial infections, the length of hospital stay, and survival. This review highlights current evidence for maximizing enteral feeding strategies for VLBW infants in various settings. Specifically, we will outline the physiologic evidence for early and continued enteral feedings in VLBW infants, discuss considerations for the initiation and advancement of enteral feedings, and highlight future areas of research focused on these issues. Consideration for the evidence from low- as well as high-resource settings is critical to inform optimal feeding strategies of VLBW infants globally.

**Keywords:** Enteral nutrition, Necrotizing enterocolitis, Prematurity.

*Newborn* (2022): 10.5005/jp-journals-11002-0038

## INTRODUCTION

Despite increasing awareness of the importance of enteral feeding with human milk, delayed initiation and slow progression of enteral feedings is still an impediment in the care of VLBW infants. Most drivers of delays to enteral feedings are fear-based related to concerns about gut immaturity, dysmotility, feeding intolerance, development of SIP, or NEC. There is increasing evidence that these feeding practices have not improved outcomes and may even be potentially harmful. Furthermore, inadequate enteral feedings can prolong the need for central lines, extend the use of parenteral nutrition, and increase the risk of central-line-associated infections and death.<sup>1,2</sup> Delayed initiation and advancement of enteral feeding increase the length and cost of hospitalization in addition to increased morbidity. Thus, with amassing evidence focused on timely initiation and progression of exclusive human-milk-based diets among VLBW infants, we aim to revisit the current feeding practices globally.

Although historical observational studies have suggested an association between rapid advancement of enteral feeding and the occurrence of NEC, modern trials of differing feeding advancement rates have not shown significant differences. The cohorts in these studies frequently had a prolonged period of fasting for weeks prior to initiation of enteral feeds, with advantages of human-milk diets not yet realized.<sup>3</sup> Recent randomized clinical trials (RCTs) evaluating enteral feeding initiation and/or advancements have demonstrated benefits such as reduction in the use of parenteral nutrition, the need for central venous access, and the risk of invasive infections, all without any increase in risk of SIP or NEC.<sup>4-8</sup>

Following the clear and significant benefits inferred from early use of human milk for VLBW infants,<sup>9</sup> the practice of providing trophic feeding has been largely accepted. However, practices regarding the ideal time for initiation of enteral feeding, the

<sup>1</sup>Division of Neonatology, University of Washington/Seattle Children's Hospital, Seattle, Washington, United States of America

<sup>2</sup>Department of Pediatrics, Division of Neonatology, University of Washington, Seattle, Washington, United States of America

<sup>3</sup>Department of Neonatology, Lady Hardinge Medical College and Kalawati Saran Children's Hospital, New Delhi, India

<sup>4</sup>USDA-ARS Children's Nutrition Research Center, Pediatrics, Gastroenterology and Nutrition, Baylor College of Medicine, Houston, Texas, United States of America

<sup>5</sup>Global Newborn Society, Clarksville, Maryland, United States of America

<sup>6</sup>St Paul's Hospital Millennium Medical College, Addis Ababa, Ethiopia

<sup>8</sup>Department of Nutrition Sciences, University of Alabama at Birmingham, Birmingham, Alabama, United States of America

<sup>9</sup>Division of Neonatology and Newborn Medicine, Hospital Materno Infantil Ramon Sarda, Buenos Aires, Argentina

<sup>10</sup>University of Alabama at Birmingham, Birmingham, Alabama, United States of America

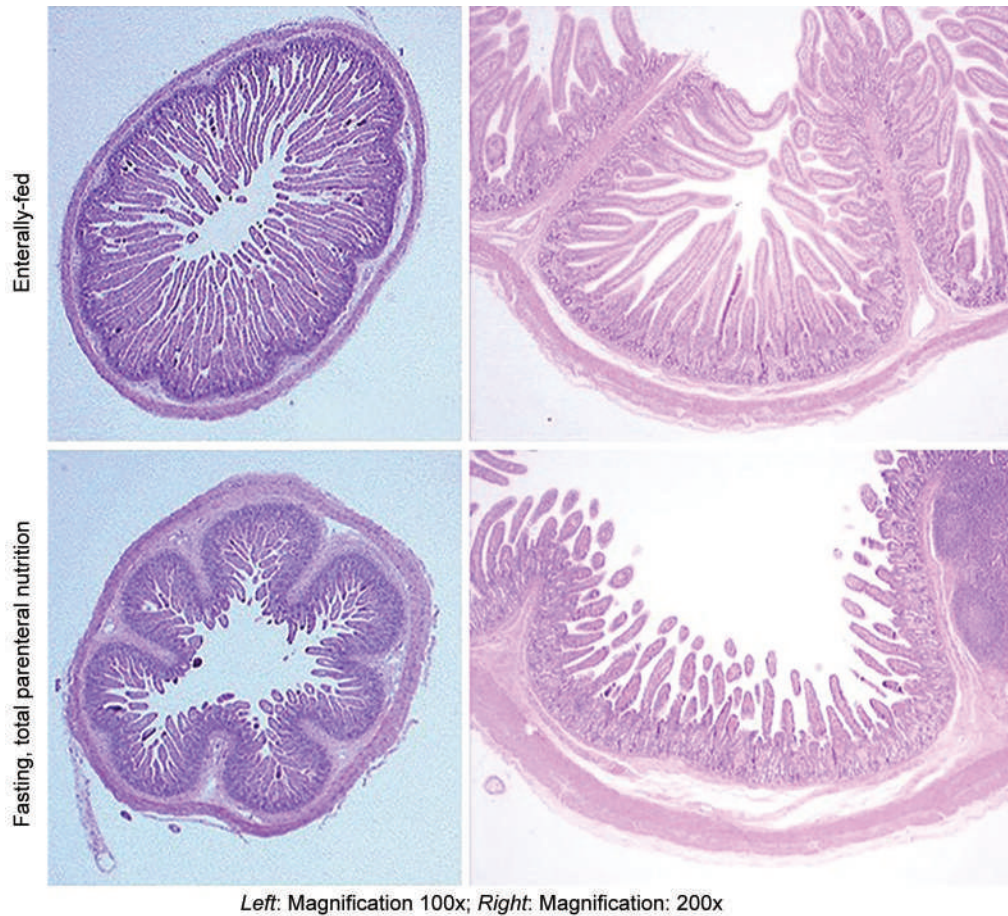
**Corresponding Author:** Ariel Salas, University of Alabama at Birmingham, Birmingham, Alabama, United States of America, Phone: +2059344680, e-mail: asalas@uab.edu

**How to cite this article:** Perez K, Valentine GC, Nangia S, *et al.* Advancement of Enteral Feeding in Very-low-birth-weight Infants: Global Issues and Challenges. *Newborn* 2022;1(3):306-313.

**Source of support:** Nil

**Conflict of interest:** None

duration and volume of initial feedings, and the rate of progression of feeding volumes to establish full enteral feeding among VLBW infants are widely variable. Promotion of early and rapid establishment of full enteral feeding, particularly when maternal



**Fig. 1:** Effect of enteral fasting on the crypt–villus axis in the gut mucosa in newborn piglets. Photomicrographs show hematoxylin–eosin stained sections from the jejunum from 4-day-old piglets that received (top) enteral feedings or (bottom) were enterally fasted and reared on total parenteral nutrition. The magnification was (left) 100 $\times$  and (right) 200 $\times$ . Enterally fasted piglets show atrophic changes with villus stunting as compared with the control animals that received milk from the dams

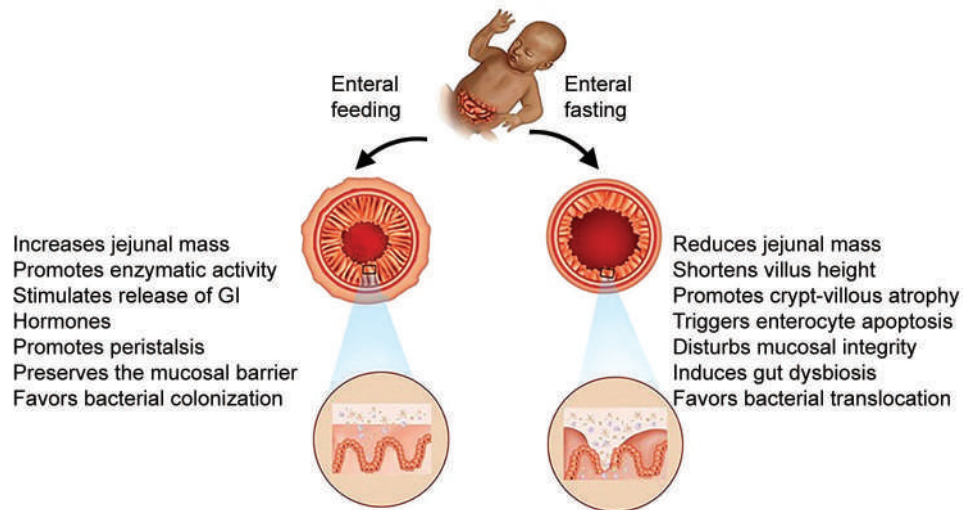
milk is available, is critical to reducing neonatal mortality from sepsis and healthcare costs worldwide, including neonatal units in low-resource settings. In this review, we will summarize the findings of RCTs and meta-analyses exploring enteral feeding initiation and progression for VLBW infants, with particular attention to balancing known and unknown confounders that contribute to the complex relationships between enteral feeding and outcomes of interest. Furthermore, we will highlight ongoing areas of study and a call for future research endeavors to continue to inform practices in high-resource settings and low-resource settings, with importance in the bidirectionality of evidence exchange rather than the “usual” high-resource setting studies informing those in low-resource settings with promising preliminary data for early total enteral nutrition and larger total fluid volumes.

## PHYSIOLOGIC EVIDENCE TO IMPORTANCE OF ENTERAL FEEDING

Enteral feeding is the postnatal route to administer nutrients. *In utero*, the ingestion of up to 500 mL/day of amniotic fluid promotes the development of the crypt–villus histoarchitecture.<sup>10–13</sup> By 16–20 weeks of gestation, the digestive and absorptive functions of the gastrointestinal (GI) tract are developed.<sup>14,15</sup>

After birth, the digestive and absorption functions,<sup>16,17</sup> including gastric acid output, bile synthesis, and exocrine pancreatic function, have been correlated with sustainable growth.<sup>18–22</sup> However, the autoregulation in splanchnic circulation<sup>23–25</sup> and gut motility may remain immature among preterm newborns,<sup>26</sup> as effective propulsion of nutrients with anterograde, organized peristaltic contractions via parasympathetic and sympathetic systems is limited.<sup>27</sup> In fact, even though most neural elements of the GI tract develop by 15–18 weeks’ gestation,<sup>28</sup> functional maturity may not be seen until later in the third trimester.<sup>27,29–31</sup>

The first few postnatal weeks are critical for the growth and development of the GI tract. In the developing intestine, even transient feeding interruptions can cause mucosal and villous atrophy, suppress the expression of digestive enzymes, and inhibit nutrient absorption.<sup>31,32</sup> Enteral fasting also decreases the gut hormonal response,<sup>33</sup> decreases mucosal IgA, and increases expression of adhesion molecules that promote leukocyte recruitment.<sup>33,34</sup> Prolonged enteral fasting can lead to up to 50% loss of mucosal mass, crypt–villus atrophy, and enterocyte apoptosis.<sup>35</sup> In parenterally fed piglets, enteral fasting induces gut mucosal atrophy (Fig. 1) with increased enterocyte apoptosis, decreased crypt-cell proliferation, and decreased jejunal mass by more than one-third, decreased villus height by almost half, and decreased villus area by more than 50%.<sup>36–38</sup> This resulting



**Fig. 2:** Schematic diagram showing the impact of enteral fasting on mucosal development, endocrine changes, and intestinal function

mucosal atrophy promotes lymphocyte activation,<sup>39</sup> increases expression of adhesion molecules,<sup>40,41</sup> favors recruitment of neutrophils, and increases expression of inflammatory cytokines.<sup>42–44</sup>

Delayed introduction of enteral feeding in newborn infants is associated with altered maturation of the mucosal crypt–villus axis or secondary atrophy (Fig. 2) that can increase bacterial translocation and the risk of infections. Infants are also known to show hyperinflammatory responses in the intestine. The structural immaturity and the altered inflammatory changes are known to increase permeability to macromolecules and luminal bacteria<sup>36</sup> and thereby increase the risk of gut-derived sepsis and NEC.<sup>32,45</sup> The deleterious effects of prolonged or transient periods of enteral fasting on the GI mucosa<sup>31–34,46</sup> may be observed after feeding interruptions that are either consciously or inadvertently prescribed to prevent feeding intolerance during treatment of patent ductus arteriosus with prostaglandin inhibitors, after the diagnosis of NEC, and in infants recovering after surgery. Specifically for NEC, a recent systematic review and meta-analysis, including 119 infants from three observational studies, found a reduced incidence of recurrent NEC and/or post-NEC stricture (OR 0.27, 95% CI 0.10, 0.75;  $p = 0.012$ ) among infants re-initiated on enteral feedings sooner (median 4 days vs median 10 days).<sup>47</sup>

In animal models, early introduction of enteral colostrum and milk feeding is associated with an increased intestinal weight by 50–75%.<sup>48,49</sup> These findings are consistent with rapid growth of the small intestine observed during the early neonatal period in humans.<sup>50,51</sup> Early initiation of enteral feeding with colostrum also enhances resistance to NEC,<sup>52</sup> promotes intestinal peristalsis, promotes enzymatic activity, augments intestinal blood flow, maintains intestinal-barrier function, prevents gut dysbiosis, and reduces infections.<sup>53–57</sup>

In human clinical studies, delayed introduction of enteral feeding has not been shown to confer protection against feeding intolerance, NEC, or abnormal gut mucosal permeability compared with early enteral feeding.<sup>3,53,58–63</sup> Delayed enteral feeding is associated with prolonged hospital stay, even among cohorts of growth-restricted infants.<sup>3,53,58–63</sup> Moreover, early postnatal enteral feeding can stimulate gut motility, promote release of GI hormones,<sup>64</sup> reduce feeding intolerance, facilitate the delivery of essential micronutrients, favor the development of a healthy gut

microbiome,<sup>65–67</sup> and even prevent severe hyperbilirubinemia.<sup>68</sup> Ultimately, the amassing literature demonstrates significant benefits and limited risk with early introduction of human milk enterally to preterm newborns, including those at-risk for NEC.

## SLOW VS RAPID PROGRESSION OF ENTERAL FEEDINGS

Following initiation of trophic feedings to prime the gut and improve feeding tolerance,<sup>69,70</sup> a gradual increase of these feeding volumes is necessary to establish full enteral feeding. The duration of trophic feeding, related to early/delayed initiation or slow/rapid advancement of enteral feedings, remains a variable parameter across neonatal units, despite a lack of benefit related to delayed and/or slower progression of enteral feeding. Compounding this issue, clinicians often reference “feeding intolerance” as a reason for slow advancement or even for the cessation of all enteral feeds for a period of time. However, this term is often used in a subjective sense and remains ill-defined, it may differ within and between institutions. Efforts focused on preventing or treating feeding intolerance are diverse and not evidence-based, leading to substantially different feeding initiation, reinitiation, and advancement practices.<sup>71–74</sup>

Randomized clinical trials have not shown increased risk of NEC with early progression of enteral feeding volumes (i.e., within the first 96 hours). Multiple well-designed RCTs of early progression of feeding volumes have shown that VLBW infants, even those critically ill between 22 and 28 weeks’ gestation, can tolerate and attain full enteral feeding within the first 10 days of life without any increase in the risk of adverse outcomes.<sup>75</sup> In a large multicenter trial, 404 small-for-gestational-age preterm newborns who were believed to be at high risk of NEC<sup>61</sup> (due to documented absence/reversal of diastolic blood flow in the umbilical artery/aorta in antenatal Doppler studies)<sup>76</sup> were randomized in two groups of early (within 24–48 hours) or delayed (between 120 and 144 hours) progression of enteral feeding. The early enteral feeding progression group achieved full enteral feeding earlier (18 vs 21 days;  $p = 0.003$ ) with no difference in the incidence of NEC (all-stage NEC, RR 1.20, 95% CI: 0.77–1.87;  $p = 0.42$ ).<sup>61</sup> Similarly, another trial in infants who were believed to be at high risk of NEC (<28 weeks’ gestation or less) showed no difference in NEC.<sup>75</sup>



Randomized clinical trials in infants considered at high risk of NEC also reported a potential reduction of culture-proven sepsis after early progression of enteral feeding.<sup>61,75</sup> A 2022 meta-analysis comparing early vs delayed progression of enteral feeding volumes concluded that delaying enteral feeding progression beyond the first 96 hours after birth increased the risk of severe infection (RR 1.44, 95% CI: 1.15–1.80;  $p = 0.001$ ).<sup>8</sup> The meta-analysis found no benefit in delaying the progression of enteral feedings on the risk of NEC (RR 0.81, 95% CI: 0.58–1.14;  $p = 0.22$ ).<sup>8</sup> Thus, given the risks of delaying feeding progression, the current evidence does not support delayed progression of feeds until several days of trophic feedings have been tolerated, but rather supports early and timely advancement of enteral feeds 24–72 hours after birth.

More rapid progression of enteral feeding volumes has similarly been shown to not increase the risk of NEC in VLBW infants. In an earlier 2011 meta-analysis,<sup>77</sup> including 4 RCTs and 496 infants who received slow advancement (daily increments of 15–20 mL/kg)<sup>78–81</sup> vs more rapid advancement (daily increments of 30–35 mL/kg/day) of feeds showed no increase in the risk of NEC (RR 0.91, 95% CI: 0.47–1.75) nor all-cause mortality (RR 1.43, 95% CI: 0.78–2.61). Faster rates of progression of feeding volumes demonstrated earlier time to regain birth weight (mean difference from 2 to 6 days) and earlier establishment of full enteral feeding (median difference from 2 to 5 days). A 2021 updated meta-analysis, including 14 trials and 4033 infants, found similar results: Advancing feeding volumes 15–24 mL/kg/day as compared with 30–40 mL/kg/day demonstrates no reduction in risk of NEC, feeding intolerance, invasive infection, or in-hospital mortality; even among ELBW infants, SGA infants, growth-restricted infants, and infants with absent or reversal of end-diastolic flow, faster feeding advancements of 30–40 mL/kg/day did not increase the risk of NEC or death.<sup>6</sup>

The 2019 Speed of Increasing milk Feeds Trial (SIFT),<sup>82</sup> which was included in the 2021 meta-analysis, is worth particular mention as the investigators included extremely low-birth-weight (ELBW) infants. The trial remains the largest published study thus far that has examined the impact of enteral feedings among VLBW infants. The trial included 2793 preterm newborns (48% between 1000 gm and 1500 gm at birth and 37% <1000 gm at birth) randomized to enteral feeding advances of 30 mL/kg/day or 18 mL/kg/day. More rapid advancements of enteral feeds did not increase the risk of NEC and had no effect on late-onset sepsis or survival without moderate-to-severe neurodevelopmental disability. Notably, most of the infants in this trial were fed exclusively or partially with breast milk, with fortifier added only after full enteral feeds were reached, making conclusions about growth challenging to interpret with many units fortifying feeds sooner. Nonetheless, the findings support more rapid advancement of feeds (30–40 mL/kg/day) than has traditionally been used (<20 mL/kg/day), particularly among infants with birthweights <1000 gm.

In summary, recent systematic reviews of the literature have concluded that neither early progressive feeding<sup>83,84</sup> nor more rapid advancements in volumes of enteral feedings<sup>5</sup> increase the risk of NEC or other adverse outcomes in VLBW infants, including SGA and growth-restricted infants. Thus, delayed initiation and advancement (<25 mL/kg/day) of enteral feeds appear unwarranted with no appreciable benefit to this practice, although, potential for increased morbidities, including invasive infection.<sup>83</sup>

## EARLY TOTAL ENTERAL FEEDINGS (ETEF) vs EARLY PARTIAL ENTERAL FEEDINGS

Early exclusive full enteral feeding may relay even more benefit than early, rapid progression of enteral feeding in stable VLBW infants. As we will discuss, recent small clinical trials suggest that ETEF in VLBW infants – defined as feeding volumes of 60–80 mL/kg/day within the 24–48 hours after birth – reduces the time to full enteral feeding, the need for intravenous (IV) access, the duration of parenteral nutrition, and the risk of late-onset sepsis. In a small feasibility trial, 23 otherwise-stable VLBW infants were randomly assigned to receive exclusive enteral nutrition (initial feeding volumes of 80 mL/kg/day) within 1 hour after birth and showed that early full enteral feeding significantly decreases the time to regain birth weight and the length of hospital stay.<sup>85</sup> In another trial, 51 VLBW infants were randomized to receive ETEF with human milk or standard care, those receiving ETEF with human milk regained birthweight sooner (11 vs 12 days,  $p = 0.04$ ) and had a shorter hospital stay (12 vs 13 days,  $p = 0.04$ ).<sup>86</sup> In a more recent trial of 180 VLBW infants, full enteral feeding with preterm formula or breast milk (if available) reduced the time to full enteral nutrition (mean difference: –3.6 days), the incidence of feeding intolerance (RR 0.5, 95% CI: 0.3–0.9,  $p = 0.002$ ), the incidence of clinical sepsis (26% vs 61%,  $p < 0.001$ ), the requirement of IV fluids (median difference: –2.2 days, 95% CI: –3.9 to –0.4,  $p = 0.02$ ), and the length of hospital stay (median difference: –4.1 days, 95% CI: –6.9 to –1.2,  $p = 0.01$ ).<sup>87</sup> Feeds were given every 2 hours in this study, and fortification was initiated once an infant was on 100 mL/kg/day of enteral feeds.<sup>87</sup>

A meta-analysis published in 2020 summarized existing randomized trials comparing ETEF to early, rapid feeding progression.<sup>7</sup> Six randomized trials were eligible for inclusion, with a total of 526 VLBW infants. None of the trials were masked and all were conducted in India with maternal milk used preferentially. While there were few and inconsistent findings with respect to growth parameters, presumably due to heterogeneity with respect to fortification and other aspects, an important finding was that ETEF as compared with early, rapid progression of enteral feeds was not associated with an increased risk of NEC (RR 0.98, 95% CI: 0.38–2.54).

The investigation of ETEF compared with conventional feeding progression is relatively new. However, two trials comparing ETEF to conventional feeding progression in the United States (E<sup>3</sup>NACT trial, NCT04337710) and United Kingdom (FEED1 trial, ISRCTN89654042) are ongoing. They will provide additional information on the effects of ETEF on outcomes and growth outside of India. Future studies focused on identifying which VLBWs might benefit most will be important, noting “stability” at such small sizes and gestational ages is relative.

## CONSIDERATIONS FOR FUTURE RESEARCH IN THE GLOBAL CONTEXT

Importantly, while all evidence for ETEF has been conducted in India, evidence of early and more rapid progression of enteral feeds has been largely derived from studies in high-income countries. Ensuring interventions are evaluated in high- and low-resource settings may be of vital importance as diagnostic and treatment options are limited. Furthermore, the directionality of ETEF being evaluated in primarily India, with ongoing evaluation in higher-

income settings, is an exciting precedent. While resources may be different between settings, physiologic importance in such basic newborn care such as early nutrition, especially with human milk, is likely shared. As total parenteral nutrition is often unavailable and sepsis is a major contributor to neonatal mortality in low-resource settings, benefits of early, rapid enteral feeding progression may be of even greater importance in such settings.<sup>88</sup> Similarly, ETEF is potentially beneficial even in high-resource settings such as the United States, noting ongoing high healthcare costs and shared goals to reduce morbidities and reduce the length of hospitalization. Future studies should also evaluate the impact of ETEF as compared with early partial enteral feeding on other outcomes such as short- and long-term growth, oral feeding progression, and neurodevelopmental outcomes.

The next potential frontier with respect to VLBW enteral feedings is the convention to limit enteral feedings at volumes conventionally within the 140–160 mL/kg/day range and the timing of fortification initiation, when/if fortifier is available. Growth is of increasing importance as a surrogate outcome globally,<sup>89</sup> associated with in-hospital outcomes and neurodevelopmental outcomes.<sup>90</sup> In many parts of the world, fortification of enteral feedings for VLBW infants is not feasible. As such, providers in low-resource settings may increase goal enteral feeding volumes beyond the conventional maximum of 160 mL/kg/day to improve early nutrition and longer-term outcomes. A 2021 meta-analysis investigating standard (<180 mL/kg/day of fortified feeds or <200 mL/kg/day unfortified feeds) versus high-volume feeding volumes (>180 mL/kg/day of fortified feeds or >200 mL/kg/day unfortified feeds) included 2 RCTs with 271 participants.<sup>4</sup> Infants fed higher feeding volumes of fortified and unfortified milk had improved in-hospital weight gain (fortified MD 2.58 g/kg/day, 95% CI 1.41–3.76; unfortified MD 6.20 g/kg/day, 95% CI 2.71–9.69) without appreciable difference in the risk of NEC.<sup>4</sup> The only trial of high-volume feedings conducted in the United States concluded that this feeding intervention favors weight gain<sup>91</sup> and fat-mass accretion within a clinical range of equivalence.<sup>92</sup> Notably, these trials included larger and more mature infants and were not exclusive to VLBW infants, and while they also showed a suggestion for improved in-hospital head circumference growth and longer-term weight gain, the level of certainty of these additional benefits was low. Acknowledging the concerns about excessive fluid intake and risk of adverse outcomes, including patent ductus arteriosus and bronchopulmonary dysplasia, in the literature, these associations have been described in the context of early, majority parenteral fluid rather than fluid from enterally derived, biologically active human milk beyond the first several days of life.<sup>93–95</sup>

Last, defining a “stable” VLBW infant that could benefit from ETEF requires further studies with much of the ETEF work to-date defining “stable” as not requiring respiratory support. Noting that noninvasive positive-pressure respiratory support, when available, is becoming standard for all VLBWs globally, defining stability by the need for respiratory support may be short-sighted. Including VLBWs who are receiving standard care, including respiratory support, as well as those classified as “unstable” needing invasive ventilation or vasopressor support, will be additional important areas of study.

## SUMMARY

Enteral feeding, particularly with human milk, may be one of the most critical therapies we offer VLBW infants, regardless of their

location of birth. Importantly, no recent trials evaluating early or more rapid advancement to full enteral feedings in VLBW infants found an increased risk of NEC or death. Prolonged enteral fasting after birth is no longer recommended with significant evidence of the risk of GI atrophy and adverse development with fasting. Bioactive human milk provides important immunoglobulins, lactoferrin, lysozyme, oligosaccharides, white blood cells, and antibodies that are beneficial to short- and long-term outcomes for VLBWs. Strong data from randomized trials indicate that the use of maternal or donor milk can effectively reduce the risk of feeding intolerance and NEC. Based on past evidence, we believe future randomized trials assessing ETEF in VLBW infants with maternal or donor milk soon after birth are unlikely to prove an increased risk of NEC.

Thousands of preterm newborns have been randomized to prove that early progressive feeding compared with delayed progressive feeding does not increase the risk of NEC ( $n = 1507$ , 13 trials), that rapid progression of feeding is not associated with a higher risk of NEC ( $n = 4026$ , 14 trials), and that early establishment of full enteral feeding is feasible in VLBW infants without an increase in NEC ( $n = 522$ , 6 trials). Ignoring this evidence from clinical trials and continuing to delay enteral feeds and advance at slow rates may result in harm to this population, particularly in low-resource settings where the incidence of severe infections is high and access to alternatives to enteral nutrition (i.e., parenteral nutrition, central venous access, and other healthcare resources) is limited. For VLBW infants considered at high risk, initiation of enteral feeding volumes at 25–30 mL/kg soon after birth (i.e., within the first 24 hours ideally) and subsequent daily feeding advancements by 25–30 mL/kg without extending the duration of trophic feeding and according to daily intolerance may be the most reasonable. For moderate-risk VLBW infants, starting at 30–40 mL/kg and advancing by 30–40 mL/kg daily could lead to important benefits. For low-risk VLBW infants, starting full enteral feeding volumes 60–80 mL/kg/day could reduce the need for IV access, improve nutrition, and decrease the wide global variation in feeding practices, ultimately improving nutritional outcomes and promoting kangaroo care without requirement of IV fluids. We look forward to findings from the Fluids Exclusively Enteral From Day 1 (FEED 1) trial and Early, Exclusive, Enteral Nutrition (E<sup>3</sup>NACT) trial, assessing ETEF and the various subsequent quality-improvement projects throughout the world focused on improving feeding practices and nutrition among VLBW infants.

## ORCID

Gregory Charles Valentine  <https://orcid.org/0000-0002-3055-2987>

Akhil Maheshwari  <https://orcid.org/0000-0003-3613-4054>

Ariel Salas  <https://orcid.org/0000-0002-4676-7747>

## REFERENCES

1. Hermansen MC, Hermansen MG. Intravascular catheter complications in the neonatal intensive care unit. *Clin Perinatol* 2005;32(1):141–156. DOI: 10.1016/j.clp.2004.11.005.
2. Colacchio K, Deng Y, Northrup V, et al. Complications associated with central and non-central venous catheters in a neonatal intensive care unit. *J Perinatol* 2012;32(12):941–946. DOI: 10.1038/jp.2012.7.
3. McKeown RE, Marsh TD, Amarnath U, et al. Role of delayed feeding and of feeding increments in necrotizing enterocolitis. *J Pediatr* 1992;121(5 Pt 1):764–770. DOI: 10.1016/s0022-3476(05)81913-4.
4. Abiramalatha T, Thomas N, Thanigainathan S. High versus standard volume enteral feeds to promote growth in preterm or low birth



- weight infants. *Cochrane Database Syst Rev* 2021;3(3):CD012413. DOI: 10.1002/14651858.CD012413.pub3.
5. Morgan J, Young L, McGuire W. Slow advancement of enteral feed volumes to prevent necrotising enterocolitis in very low birth weight infants. *Cochrane Database Syst Rev* 2015;(10):CD001241. DOI: 10.1002/14651858.CD001241.pub6.
  6. Oddie SJ, Young L, McGuire W. Slow advancement of enteral feed volumes to prevent necrotising enterocolitis in very low birth weight infants. *Cochrane Database Syst Rev* 2021;8(8):CD001241. DOI: 10.1002/14651858.CD001241.pub8.
  7. Walsh V, Brown JVE, Copperthwaite BR, et al. Early full enteral feeding for preterm or low birth weight infants. *Cochrane Database Syst Rev* 2020;12(12):CD013542. DOI: 10.1002/14651858.CD013542.pub2.
  8. Young L, Oddie SJ, McGuire W. Delayed introduction of progressive enteral feeds to prevent necrotising enterocolitis in very low birth weight infants. *Cochrane Database Syst Rev* 2022;1:CD001970. DOI: 10.1002/14651858.CD001970.pub6.
  9. Quigley M, Embleton ND, McGuire W. Formula versus donor breast milk for feeding preterm or low birth weight infants. *Cochrane Database Syst Rev* 2019;7(7):CD002971. DOI: 10.1002/14651858.CD002971.pub5.
  10. Condino AA, Barleycorn AA, Lu W, et al. Abnormal intestinal histology in neonates with congenital anomalies of the gastrointestinal tract. *Biol Neonate* 2004;85(3):145–150. DOI: 10.1159/000075064.
  11. Herbst JJ, Sunshine P. Postnatal development of the small intestine of the rat. Changes in mucosal morphology at weaning. *Pediatr Res* 1969;3(1):27–33. DOI: 10.1203/00006450-196901000-00004.
  12. Trahair JF. Remodeling of the rat small intestinal mucosa during the suckling period. *J Pediatr Gastroenterol Nutr* 1989;9(2):232–237. DOI: 10.1097/00005176-198908000-00017.
  13. Trahair JF, Harding R. Restitution of swallowing in the fetal sheep restores intestinal growth after midgestation esophageal obstruction. *J Pediatr Gastroenterol Nutr* 1995;20(2):156–161. DOI: 10.1097/00005176-199502000-00004.
  14. Levy E, Delvin E, Menard D, et al. Functional development of human fetal gastrointestinal tract. *Methods Mol Biol* 2009;550:205–224. DOI: 10.1007/978-1-60327-009-0\_13.
  15. Menard D. Functional development of the human gastrointestinal tract: Hormone- and growth factor-mediated regulatory mechanisms. *Can J Gastroenterol* 2004;18(1):39–44. DOI: 10.1155/2004/640897.
  16. Atkinson SA, Bryan MH, Anderson GH. Human milk feeding in premature infants: Protein, fat, and carbohydrate balances in the first two weeks of life. *J Pediatr* 1981;99(4):617–624. DOI: 10.1016/s0022-3476(81)80275-2.
  17. Schanler RJ, Rifka M. Calcium, phosphorus and magnesium needs for the low-birth-weight infant. *Acta Paediatr Suppl* 1994;405:111–116. DOI: 10.1111/j.1651-2227.1994.tb13408.x.
  18. Antonowicz I, Chang SK, Grand RJ. Development and distribution of lysosomal enzymes and disaccharidases in human fetal intestine. *Gastroenterology* 1974;67(1):51–58. PMID: 485813.7.
  19. Zoppi G, Andreotti G, Pajno-Ferrara F, et al. Exocrine pancreas function in premature and full term neonates. *Pediatr Res* 1972;6(12):880–886. DOI: 10.1203/00006450-197212000-00005.
  20. Lucas A, Bloom SR, Aynsley-Green A. Development of gut hormone responses to feeding in neonates. *Arch Dis Child* 1980;55(9):678–682. DOI: 10.1136/adc.55.9.678.
  21. Berseth CL, Nordyke CK, Valdes MG, et al. Responses of gastrointestinal peptides and motor activity to milk and water feedings in preterm and term infants. *Pediatr Res* 1992;31(6):587–590. DOI: 10.1203/00006450-199206000-00010.
  22. Hyman PE, Clarke DD, Everett SL, et al. Gastric acid secretory function in preterm infants. *J Pediatr* 1985;106(3):467–471. DOI: 10.1016/s0022-3476(85)80682-x.
  23. Szabo JS, Mayfield SR, Oh W, et al. Postprandial gastrointestinal blood flow and oxygen consumption: Effects of hypoxemia in neonatal piglets. *Pediatr Res* 1987;21(1):93–98. DOI: 10.1203/00006450-198701000-00020.
  24. Yanowitz TD, Yao AC, Pettigrew KD, et al. Postnatal hemodynamic changes in very-low-birthweight infants. *J Appl Physiol* 1999; 87(1):370–380. DOI: 10.1152/jappl.1999.87.1.370.
  25. Krimmel GA, Baker R, Yanowitz TD. Blood transfusion alters the superior mesenteric artery blood flow velocity response to feeding in premature infants. *Am J Perinatol* 2009;26(2):99–105. DOI: 10.1055/s-0028-1090595.
  26. Lau C, Smith EO, Schanler RJ. Coordination of suck-swallow and swallow respiration in preterm infants. *Acta Paediatr* 2003;92(6): 721–727. PMID: 12856985.
  27. Berseth CL. Neonatal small intestinal motility: Motor responses to feeding in term and preterm infants. *J Pediatr* 1990;117(5):777–782. DOI: 10.1016/s0022-3476(05)83343-8.
  28. Gershon MD, Chalazontitis A, Rothman TP. From neural crest to bowel: Development of the enteric nervous system. *J Neurobiol* 1993; 24(2):199–214. DOI: 10.1002/neu.480240207.
  29. Gupta M, Brans YW. Gastric retention in neonates. *Pediatrics* 1978;62(1):26–29. PMID: 683779.
  30. Cavell B. Gastric emptying in infants fed human milk or infant formula. *Acta Paediatr Scand* 1981;70(5):639–641. PMID: 7324911.
  31. Neu J. Gastrointestinal development and meeting the nutritional needs of premature infants. *Am J Clin Nutr* 2007;85(2):629S–634S. DOI: 10.1093/ajcn/85.2.629S.
  32. Alpers DH. Enteral feeding and gut atrophy. *Curr Opin Clin Nutr Metab Care* 2002;5(6):679–683. DOI: 10.1097/01.mco.0000038812.16540.72.
  33. Ziegler EE, Thureen PJ, Carlson SJ. Aggressive nutrition of the very low birthweight infant. *Clin Perinatol* 2002;29(2):225–244. DOI: 10.1016/s0095-5108(02)00007-6.
  34. Neu J, Douglas-Escobar M, Lopez M. Microbes and the developing gastrointestinal tract. *Nutr Clin Pract* 2007;22(2):174–182. DOI: 10.1177/0115426507022002174.
  35. Niinikoski H, Stoll B, Guan X, et al. Onset of small intestinal atrophy is associated with reduced intestinal blood flow in TPN-fed neonatal piglets. *J Nutr* 2004;134(6):1467–1474. DOI: 10.1093/jn/134.6.1467.
  36. Kansagra K, Stoll B, Rognerud C, et al. Total parenteral nutrition adversely affects gut barrier function in neonatal piglets. *Am J Physiol Gastrointest Liver Physiol* 2003;285(6):G1162–G1170. DOI: 10.1152/ajpgi.00243.2003.
  37. Burrin DG, Stoll B, Jiang R, et al. Minimal enteral nutrient requirements for intestinal growth in neonatal piglets: How much is enough? *Am J Clin Nutr* 2000;71(6):1603–1610. DOI: 10.1093/ajcn/71.6.1603.
  38. Levine GM, Deren JJ, Steiger E, et al. Role of oral intake in maintenance of gut mass and disaccharide activity. *Gastroenterology* 1974;67(5):975–982. PMID: 4214726.
  39. Kudsk KA. Current aspects of mucosal immunology and its influence by nutrition. *Am J Surg* 2002;183(4):390–398. DOI: 10.1016/s0002-9610(02)00821-8.
  40. Conour JE, Ganessunker D, Tappenden KA, et al. Acidomucin goblet cell expansion induced by parenteral nutrition in the small intestine of piglets. *Am J Physiol Gastrointest Liver Physiol* 2002;283(5):G1185–G1196. DOI: 10.1152/ajpgi.00097.2002.
  41. Ganessunker D, Gaskins HR, Zuckermann FA, et al. Total parenteral nutrition alters molecular and cellular indices of intestinal inflammation in neonatal piglets. *JPEN J Parenter Enteral Nutr* 1999;23(6):337–344. DOI: 10.1177/0148607199023006337.
  42. Kiristoglou I, Antony P, Fan Y, et al. Total parenteral nutrition-associated changes in mouse intestinal intraepithelial lymphocytes. *Dig Dis Sci* 2002;47(5):1147–1157. DOI: 10.1023/a:1015066813675.
  43. Yang H, Finaly R, Teitelbaum DH. Alteration in epithelial permeability and ion transport in a mouse model of total parenteral nutrition. *Crit Care Med* 2003;31(4):1118–1125. DOI: 10.1097/01.CCM.0000053523.73064.8A.
  44. Siggers J, Sangild PT, Jensen TK, et al. Transition from parenteral to enteral nutrition induces immediate diet-dependent gut histological and immunological responses in preterm neonates. *Am J Physiol Gastrointest Liver Physiol* 2011;301(3):G435–G445. DOI: 10.1152/ajpgi.00400.2010.

45. Berg RD. Bacterial translocation from the gastrointestinal tract. *Trends Microbiol* 1995;3(4):149–154. DOI: 10.1016/s0966-842x(00)88906-4.
46. Shin ED, Estall JL, Izzo A, et al. Mucosal adaptation to enteral nutrients is dependent on the physiologic actions of glucagon-like peptide-2 in mice. *Gastroenterology* 2005;128(5):1340–1353. DOI: 10.1053/j.gastro.2005.02.033.
47. Patel EU, Wilson DA, Brennan EA, et al. Earlier re-initiation of enteral feeding after necrotizing enterocolitis decreases recurrence or stricture: A systematic review and meta-analysis. *J Perinatol* 2020; 40(11):1679–1687. DOI: 10.1038/s41372-020-0722-1.
48. Bjornvad CR, Schmidt M, Petersen YM, et al. Preterm birth makes the immature intestine sensitive to feeding-induced intestinal atrophy. *Am J Physiol - Regul, Integr Comp Physiol* 2005;289(4):R1212–R1222. DOI: 10.1152/ajpregu.00776.2004.
49. Burrin DG, Shulman RJ, Reeds PJ, et al. Porcine colostrum and milk stimulate visceral organ and skeletal muscle protein synthesis in neonatal piglets. *J Nutr* 1992;122(6):1205–1213. DOI: 10.1093/jn/122.6.1205.
50. Sangild PT, Petersen YM, Schmidt M, et al. Preterm birth affects the intestinal response to parenteral and enteral nutrition in newborn pigs. *J Nutr* 2002;132(9):2673–2681. DOI: 10.1093/jn/132.9.2673.
51. Schmidt M, Sangild PT, Blum JW, et al. Combined ACTH and glucocorticoid treatment improves survival and organ maturation in premature newborn calves. *Theriogenology* 2004;61(9):1729–1744. DOI: 10.1016/j.theriogenology.2003.10.002.
52. Siggers RH, Siggers J, Thymann T, et al. Nutritional modulation of the gut microbiota and immune system in preterm neonates susceptible to necrotizing enterocolitis. *J Nutr Biochem* 2011;22(6):511–521. DOI: 10.1016/j.jnutbio.2010.08.002.
53. Bombell S, McGuire W. Delayed introduction of progressive enteral feeds to prevent necrotising enterocolitis in very low birth weight infants. *Cochrane Database Syst Rev* 2008;(2):CD001970. DOI: 10.1002/14651858.CD001970.pub2.
54. Thompson AM, Bizzarro MJ. Necrotizing enterocolitis in newborns: Pathogenesis, prevention and management. *Drugs* 2008;68(9): 1227–1238. DOI: 10.2165/00003495-200868090-00004.
55. Hay WW, Jr. Strategies for feeding the preterm infant. *Neonatology* 2008;94(4):245–254. DOI: 10.1159/000151643.
56. Tyson JE, Kennedy KA, Lucke JF, et al. Dilemmas initiating enteral feedings in high risk infants: How can they be resolved? *Semin Perinatol* 2007;31(2):61–73. DOI: 10.1053/j.semperi.2007.02.008.
57. Shen RL, Thymann T, Ostergaard MV, et al. Early gradual feeding with bovine colostrum improves gut function and NEC resistance relative to infant formula in preterm pigs. *Am J Physiol Gastrointest Liver Physiol* 2015;309(5):G310–G323. DOI: 10.1152/ajpgi.00163.2015.
58. Karagianni P, Briana DD, Mitsiakos G, et al. Early versus delayed minimal enteral feeding and risk for necrotizing enterocolitis in preterm growth-restricted infants with abnormal antenatal Doppler results. *Am J Perinatol* 2010;27(5):367–373. DOI: 10.1055/s-0029-1243310.
59. Kennedy KA, Tyson JE, Chamnanvanikij S. Early versus delayed initiation of progressive enteral feedings for parenterally fed low birth weight or preterm infants. *Cochrane Database Syst Rev* 2000;(2):CD001970. DOI: 10.1002/14651858.CD001970.
60. LaGamma EF, Ostertag SG, Birenbaum H. Failure of delayed oral feedings to prevent necrotizing enterocolitis. Results of study in very-low-birth-weight neonates. *Am J Dis Child* 1985;139(4):385–389. DOI: 10.1001/archpedi.1985.02140060067031.
61. Leaf A, Dorling J, Kempley S, et al. Early or delayed enteral feeding for preterm growth-restricted infants: A randomized trial. *Pediatrics* 2012;129(5):e1260–e1268. DOI: 10.1542/peds.2011-2379.
62. Morgan J, Young L, McGuire W. Delayed introduction of progressive enteral feeds to prevent necrotising enterocolitis in very low birth weight infants. *Cochrane Database Syst Rev* 2011;(5):CD001970. DOI: 10.1002/14651858.CD001970.pub4.
63. van Elburg RM, van den Berg A, Bunkers CM, et al. Minimal enteral feeding, fetal blood flow pulsatility, and postnatal intestinal permeability in preterm infants with intrauterine growth retardation. *Arch Dis Child Fetal Neonatal Ed* 2004;89(4):F293–F296. DOI: 10.1136/adc.2003.027367.
64. Lucas A, Bloom SR, Aynsley-Green A. Gut hormones and ‘minimal enteral feeding’. *Acta Paediatr Scand* 1986;75(5):719–723. DOI: 10.1111/j.1651-2227.1986.tb10280.x.
65. Salas AA, Willis KA, Carlo WA, et al. The gut microbiome of extremely preterm infants randomized to the early progression of enteral feeding. *Pediatr Res* 2021. DOI: 10.1038/s41390-021-01831-w.
66. Dahlgren AF, Pan A, Lam V, et al. Longitudinal changes in the gut microbiome of infants on total parenteral nutrition. *Pediatr Res* 2019;86(1):107–114. DOI: 10.1038/s41390-019-0391-y.
67. Wang Z, Neupane A, Vo R, et al. Comparing gut microbiome in mothers’ own breast milk- and formula-fed moderate-late preterm infants. *Front Microbiol* 2020;11:891. DOI: 10.3389/fmicb.2020.00891.
68. Bastian L, Weimann A. [Practical aspects of early enteral feeding]. *Anaesthesiol Reanim* 1999;24(4):95–100. PMID: 10528415.
69. Thureen PJ, Hay WW, Jr. Early aggressive nutrition in preterm infants. *Semin Neonatol* 2001;6(5):403–415. DOI: 10.1053/siny.2001.0061.
70. Harkness L. The history of enteral nutrition therapy: From raw eggs and nasal tubes to purified amino acids and early postoperative jejunal delivery. *J Am Diet Assoc* 2002;102(3):399–404. DOI: 10.1016/s0002-8223(02)90092-1.
71. Fanaro S. Which is the ideal target for preterm growth? *Minerva Pediatr* 2010;62(3 Suppl 1):77–82. PMID: 21089724.
72. Fanaro S. Strategies to improve feeding tolerance in preterm infants. *J Matern Fetal Neonatal Med* 2012;25(Suppl 4):54–56. DOI:10.3109/14767058.2012.715021.
73. Fanaro S. Feeding intolerance in the preterm infant. *Early Hum Dev* 2013;89(Suppl 2):S13–S20. DOI: 10.1016/j.earlhumdev.2013.07.013.
74. Ghoneim N, Bauchart-Thevret C, Oosterloo B, et al. Delayed initiation but not gradual advancement of enteral formula feeding reduces the incidence of necrotizing enterocolitis (NEC) in preterm pigs. *PLoS One* 2014;9(9):e106888. DOI: 10.1371/journal.pone.0106888.
75. Salas AA, Li P, Parks K, et al. Early progressive feeding in extremely preterm infants: A randomized trial. *Am J Clin Nutr* 2018;107(3): 365–370. DOI: 10.1093/ajcn/nqy012.
76. Dorling J, Kempley S, Leaf A. Feeding growth restricted preterm infants with abnormal antenatal Doppler results. *Arch Dis Child Fetal Neonatal Ed* 2005;90(5):F359–F363. DOI: 10.1136/adc.2004.060350.
77. Morgan J, Young L, McGuire W. Slow advancement of enteral feed volumes to prevent necrotising enterocolitis in very low birth weight infants. *Cochrane Database Syst Rev* 2011;(3):CD001241. DOI: 10.1002/14651858.CD001241.pub3.
78. Rayyis SF, Ambalavanan N, Wright L, et al. Randomized trial of “slow” versus “fast” feed advancements on the incidence of necrotizing enterocolitis in very low birth weight infants. *J Pediatr* 1999;134(3):293–297.
79. Salhotra A, Ramji S. Slow versus fast enteral feed advancement in very low birth weight infants: A randomized control trial. *Indian Pediatr* 2004;41(5):435–441. PMID: 15181294.
80. Cople J, Armentrout D, Huseby V, et al. Randomized, controlled trial of slow versus rapid feeding volume advancement in preterm infants. *Pediatrics* 2004;114(6):1597–1600. DOI:10.1542/peds.2004-1232.
81. Krishnamurthy S, Gupta P, Debnath S, et al. Slow versus rapid enteral feeding advancement in preterm newborn infants 1000-1499 g: A randomized controlled trial. *Acta Paediatr* 2010;99(1):42–46. DOI: 10.1111/j.1651-2227.2009.01519.x.
82. Dorling J, Abbott J, Berrington J, et al. Controlled trial of two incremental milk-feeding rates in preterm infants. *N Engl J Med* 2019;381(15):1434–1443. DOI: 10.1056/NEJMoa1816654.
83. Leaf A, Dorling J, Kempley S, et al. Early or delayed enteral feeding for preterm growth-restricted infants: a randomized trial. *Pediatrics* 2012;129(5):e1260–e1268. DOI: 10.1542/peds.2011-2379.
84. Morgan J, Young L, McGuire W. Delayed introduction of progressive enteral feeds to prevent necrotising enterocolitis in very low birth weight infants. *Cochrane Database Syst Rev* 2014;2014(12):CD001970. DOI: 10.1002/14651858.CD001970.pub5.





85. Sanghvi KP, Joshi P, Nabi F, et al. Feasibility of exclusive enteral feeds from birth in VLBW infants >1200 g--An RCT. *Acta Paediatr* 2013;102(7):e299–e304. DOI: 10.1111/apa.12254.
86. Bora R, Murthy NB. In resource limited areas complete enteral feed in stable very low birth weight infants (1000-1500 g) started within 24 h of life can improve nutritional outcome. *J Matern Fetal Neonatal Med* 2017;30(21):2572–2577. DOI: 10.1080/14767058.2016.1256992.
87. Nangia S, Vadivel V, Thukral A, et al. Early total enteral feeding versus conventional enteral feeding in stable very-low-birth-weight infants: A randomised controlled trial. *Neonatology* 2019;115(3): 256–262. DOI: 10.1159/000496015.
88. Nangia S, Bishnoi A, Goel A, et al. Early total enteral feeding in stable very low birth weight infants: A before and after study. *J Trop Pediatr* 2018;64(1):24–30. DOI: 10.1093/tropej/fmx023.
89. Goldberg DL, Becker PJ, Brigham K, et al. Identifying malnutrition in preterm and neonatal populations: Recommended indicators. *J Acad Nutr Diet* 2018;118(9):1571–1582. DOI: 10.1016/j.jand.2017.10.006.
90. Salas AA, Bhatia A, Carlo WA. Postnatal growth of preterm infants 24 to 26 weeks of gestation and cognitive outcomes at 2 years of age. *Pediatr Res* 2021;89(7):1804–1809. DOI: 10.1038/s41390-020-01158-y.
91. Travers CP, Wang T, Salas AA, et al. Higher- or usual-volume feedings in infants born very preterm: A randomized clinical trial. *J Pediatr* 2020; 224:66–71.e1. DOI: 10.1016/j.jpeds.2020.05.033.
92. Salas AA, Travers CP, Jerome ML, et al. Percent body fat content measured by plethysmography in infants randomized to high- or usual-volume feeding after very preterm birth. *J Pediatr* 2021;230:251–254.e3. DOI: 10.1016/j.jpeds.2020.11.028.
93. Stephens BE, Gargus RA, Walden RV, et al. Fluid regimens in the first week of life may increase risk of patent ductus arteriosus in extremely low birth weight infants. *J Perinatol* 2008;28(2):123–128. DOI: 10.1038/sj.jp.7211895.
94. Valentine GC, Perez KM, Wood TR, et al. Postnatal maximal weight loss, fluid administration, and outcomes in extremely preterm newborns. *J Perinatol* 2022;42(8):1008–1016. DOI: 10.1038/s41372-022-01369-7.
95. Oh W, Poindexter BB, Perritt R, et al. Association between fluid intake and weight loss during the first ten days of life and risk of bronchopulmonary dysplasia in extremely low birth weight infants. *J Pediatr* 2005;147(6):786–790. DOI: 10.1016/j.jpeds.2005.06.039.

# Neonatal Intensive Care Unit Care of Newborn Infants born to Mothers with Suspected or Confirmed COVID-19 Infection

Yahya Ethawi<sup>1</sup>, Mona Khalaf<sup>2</sup>, Haider Nadhim<sup>3</sup>, Fares Chedid<sup>4</sup>, Yaser Al Sayed<sup>5</sup>, Rola AlAzi<sup>6</sup>, Ahmad Mohd Haider Al Amad<sup>7</sup>, Suad Hannawi<sup>8</sup>, Mahmoud Hamouri<sup>9</sup>, Majeed Jawad<sup>10</sup>, Abdulrahman Al Nemri<sup>11</sup>, Alok Sharma<sup>12</sup>, Yusra Swaidat<sup>13</sup>, Rola Al Thawbti<sup>14</sup>

Received on: 29 May 2022; Accepted on: 15 September 2022; Published on: 07 October 2022

## ABSTRACT

The virus severe acute respiratory syndrome-coronavirus 2 (SARS-CoV-2), which was later termed Coronavirus disease-19 (COVID-19), was first identified as a cause of atypical respiratory diseases in the Hubei Province of Wuhan, China, December 2019, and was then officially declared a pandemic by the World Health Organization (WHO) on March 11, 2020. Severe acute respiratory syndrome coronavirus 2 contains a single-stranded, positive-sense ribonucleic acid (RNA) genome surrounded by an extracellular membrane containing a series of spike glycoproteins resembling a crown. In this article, we have reviewed the perinatal clinical implications of SARS-CoV-2 infections and their management in birthing and neonatal intensive care units (NICUs). Increasing evidence suggest that strict hospital protocols are needed, but we may not need to separate the mothers and their infants or discourage breastfeeding. We have included information from our infection-control protocols in our hospitals and from an extensive literature search in the databases PubMed, EMBASE, and Scopus. To avoid bias in the identification of studies, keywords were shortlisted *a priori* from anecdotal experience and PubMed's Medical Subject Heading (MeSH) thesaurus.

**Keywords:** Acute respiratory syndrome-coronavirus 2, Coronavirus disease-19, Neonatal intensive care unit, Personal protection equipment, Ribonucleic acid reverse transcription-polymerase chain reaction, Reverse transcription-polymerase chain reaction, Severe acute respiratory syndrome-coronavirus 2.

*Newborn* (2022): 10.5005/jp-journals-11002-0042

## INTRODUCTION

At the end of 2019, the city of Wuhan, Hubei province, China had been challenged by patients who presented with a cluster of a pneumonia-like picture with a mysterious underlying etiology. The new challenging medical problem spread rapidly through China, followed by throughout the globe. The WHO called the COVID-19 by February 20, 2020.<sup>1</sup> Coronavirus disease-19 caused by SARS-CoV-2.<sup>1</sup>

The SARS-CoV-2 is a  $\beta$ -coronavirus of the same subpopulation of severe acute respiratory syndrome (SARS) and many bat-related coronaviruses. It is enveloped, positive-sense, single-stranded RNA viruses of zoonotic origin (Fig. 1). All these viruses used the same angiotensin-converting enzyme 2 to enter the victim cell.<sup>2</sup> The number of confirmed infections pluming up to date with the updated numbers can be found here.

Transmission of the virus started in Wuhan was linked to the seafood market selling live animals. Later on, person-to-person transmission has evolved but was not clearly understood. However, it might be mainly through the respiratory system same as influenza does by respiratory droplets generated by talking, sneezing, and coughing. The infection either occurs directly when the droplets landed at the mucus surfaces or indirectly by coughing producing droplets that landed over surfaces. Touching the infected surfaces followed by mouth, nose, or eye touching can also cause viral transmission.<sup>3</sup> Air-borne transmission has not been shown conclusively as of yet. Coronavirus disease-19 virus can stay alive for various periods on different surfaces.<sup>4</sup> The virus has not been found in the respiratory system only but found in the blood, eyes, and stool. Despite, as of yet, we are not sure what the virus exactly does in these areas but as the disease knowledge

<sup>1</sup>NICU, Saudi German Hospital Ajman, Steering Committee of the Arab Board Neonatal-Perinatal Medicine Fellowship Program, Ajman, United Arab Emirates

<sup>2,6,14</sup>Ministry of Health and Prevention, NICU, Al Qassimi Hospital for Women and Children, Sharjah, United Arab Emirates

<sup>3</sup>Department of Pediatrics, The University of Wasit, Iraq

<sup>4</sup>NICU, Kanad Hospital, Al Ain, United Arab Emirates

<sup>5</sup>Department of Pediatrics, The University of Manitoba, Canada

<sup>7-9</sup>Ministry of Health and Prevention, Al Kuwait Hospital, Dubai, United Arab Emirates

<sup>10</sup>Royal College of Pediatrics and Child Health, United Kingdom

<sup>11</sup>Department of Neonatology, NICU, King Saud University, Saudi Arabia

<sup>12</sup>Department of Neonatal Medicine, NICU, University Hospital Southampton NHS Trust, United Kingdom

<sup>13</sup>Ministry of Health, United Arab Emirates

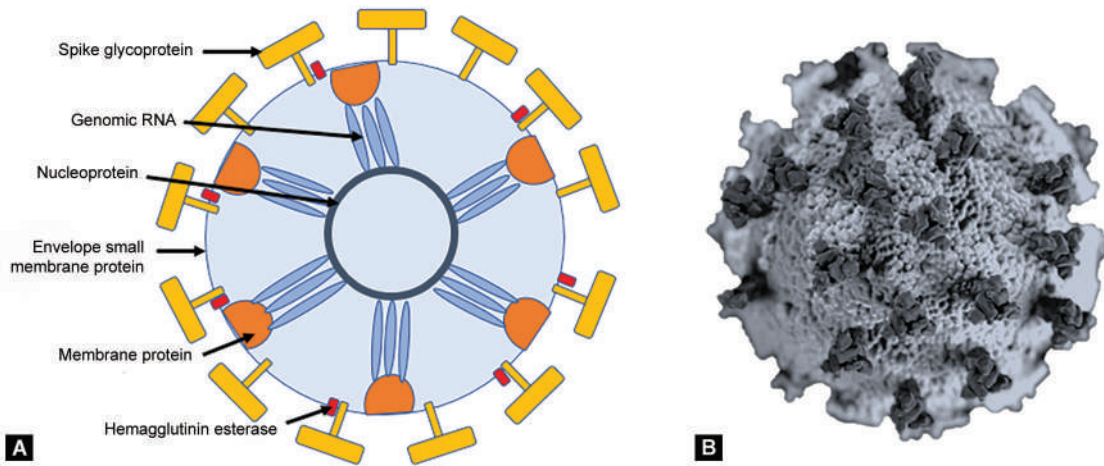
**Corresponding Author:** Yahya Ethawi, NICU, Saudi German Hospital Ajman, Steering Committee of the Arab Board Neonatal-Perinatal Medicine Fellowship Program, Ajman, United Arab Emirates, Phone: +971505955089, e-mail: yahyaethawi@yahoo.com

**How to cite this article:** Ethawi Y, Khalaf M, Nadhim H, *et al.* Neonatal Intensive Care Unit Care of Newborn Infants born to Mothers with Suspected or Confirmed COVID-19 Infection. *Newborn* 2022;1(3):314–319.

**Source of support:** Nil

**Conflict of interest:** None

is evolving, a new clinical presentation is being recognized. The infectivity period is not defined as the infected person can transfer the infection before and at the symptoms' appearance. The viral



**Figs 1A and B:** COVID-19 virus. (A) Schematic showing the major structural components and (B) 3D model of the virus

load of SARS-CoV-2 of those recovered from the upper respiratory system seems higher than other RNA viruses.<sup>5-7</sup> However, we do not know the effect of viral load on the duration of infectivity, which is still uncertain.

The risk of infectivity of SARS-CoV-2 is variable depending on many factors such as (1) type of exposure, (2) duration of exposure, (3) use of preventive measures, and (4) amount of virus in respiratory secretions. Most person-to-person infection is associated with (1) household contacts, (2) health-care providers with the protective equipment, (3) closed settings such as cruise ships, and (4) social or work gatherings with close contacts (<1.5 meter) for >15 minutes.<sup>8-10</sup>

While, indirect infection from items that were in contact with an infected person on the surface then to another person has not been documented and may be unlikely. The frequency and the importance of environmental transmission through surface contaminated with the viruses through touching the surfaces with hands then to the mouth, nose and, eyes are possible but not noticeably clear.<sup>11</sup> The length of virus survival on these surfaces is unclear but can last up to 6–9 days without disinfection. Despite the thinking that the first transmission of COVID-19 was from an animal, an animal-to-human transmission was unclear.<sup>12</sup>

## CLINICAL FEATURES

Most cases show symptoms after 5 days of exposure, although the incubation period can extend up to 14 days after exposure.<sup>13</sup> The symptoms range from asymptomatic to critically ill severe symptoms.<sup>14</sup> The Center for Disease Control and Prevention of China estimated the severity of the symptoms to be as follows:<sup>15</sup> (1) Mild (no or mild pneumonia) in 81%, (2) severe disease (respiratory distress, desaturation, the involvement of 50% of the lung by 24–48 hours of imaging) in 14%, and (3) critical disease (respiratory failure, shock, or multiorgan dysfunction) in 5%.

Risk for severe disease are:<sup>16,17</sup> (1) cardiovascular disease, (2) diabetes mellitus, (3) hypertension, (4) chronic lung disease, (5) cancer (blood malignancies, lung cancer, and metastatic disease), (6) chronic kidney disease, and (7) obesity. Severe disease can occur at any age but middle-to-elder age were the most affected.<sup>18</sup> Asymptomatic patients can quickly progress to critically severe status.<sup>19</sup> The average case fatality is approximately 2.3%.

## LABORATORY FINDINGS

Complete blood picture may show lymphopenia, liver enzyme may be elevated, high lactate dehydrogenase levels, high inflammatory markers such as ferritin, C-reactive protein, and erythrocyte sedimentation rate with abnormal coagulation profile such as high D-dimer.<sup>20</sup>

## IMAGING

Early in the course of the disease, chest X-ray might be normal, but the findings of abnormal changes increase over the course of the illness with a peak at 10–12 days of starting the symptoms. The later on common findings are: (1) consolidation and (2) bilateral, peripheral, and lower lung zone distributions ground glass appearance.<sup>21</sup> No finding can confidently exclude COVID-19 infection, but the chest computed tomography (CT) scan is overly sensitive imaging for COVID-19 chest involvement.<sup>22</sup> Bilateral and mainly peripheral ground-glass opacification with or without consolidative abnormalities in the form of viral pneumonia are the most common findings, but rarely there are pleural thickening, pleural effusion, and/or lymphadenopathy.<sup>23,24</sup>

## DIAGNOSIS

Clinical suspicion of COVID-19 infection includes: (1) new onset of fever with or without respiratory symptoms such as cough or dyspnea, (2) unclear cause of severe lower respiratory symptoms, and (3) other suggested symptoms such as diarrhea, myalgias, unusual or loss of smell, or taste, conjunctivitis, skin rash or discoloration of the fingers or toes. Travel history or close contact with confirmed or suspected COVID-19-infected person should increase the suspicion. Symptomatic hospital staff especially those without proper personal protective equipment (PPE) should be investigated.

## MICROBIOLOGICAL DIAGNOSIS

SARS-CoV-2 RNA reverse transcription-polymerase chain reaction (RT-PCR) can diagnose COVID-19 infection.<sup>25</sup> The nasopharyngeal or oropharyngeal swabs are used to collect the samples.<sup>26</sup> Serology can be used to identify previous and current infection.<sup>27</sup>

## SPECIFIC FINDINGS IN INFECTED CHILDREN AND ADOLESCENTS

Children of all ages can get the infection in lower incidence than adult.<sup>28</sup> They account for 1–5% of total COVID-19 infections.<sup>29</sup> In the USA, the age distribution is (1) children <1 year old account for 15% of all infections, (2) 1–4 years for 11%, (3) 5–9 years for 15%, (4) 10–14 years for 27%, and (5) 15–17 years for 32%.<sup>30</sup> The overall proportion of cases in infants is 0.27%.<sup>30</sup> Severe and fatal cases of COVID-19 are rare in children as the majority of children are either asymptomatic or have mild-to-moderate disease with 1–2 weeks of disease recovery.

## SPECIFIC FINDINGS IN THE PERINATAL AND NEONATAL PERIOD

### Precautions to Prevent Fetal Infection during Pregnancy

The following precautions need to be taken to prevent fetal infection during pregnancy:

- Administration of steroids for fetal lung maturation should be as normal practice; there is no evidence it causes any harm.
- MgSO<sub>4</sub> should be given for neuroprotection of infants <30 weeks' gestation as per current guidelines; there is no evidence it causes any harm.

### Precautions for the Suspected/Confirmed Maternal Infection in the Delivery Room

Droplet precautions should be implemented in the delivery room because COVID-19 infection is highly communicable despite the risk of vertical transmission is low, but so far it is not clear when and how the transmission occurs. Therefore, the following procedures need to be considered in the delivery room:

- A designated senior member of the neonatal team should be assigned to attend the suspected/confirmed COVID-19 deliveries.
- Personal protection equipment should be donned in an adjacent room and the team member should wait outside. The PPE should minimally include shows cover, suitable scrub, head cover, N95 mask, and face shield.
- If it is anticipated that the baby will require respiratory support, appropriately skilled neonatal team members should be present at delivery wearing PPE.
- Neonatal resuscitation/stabilization should proceed as per current neonatal resuscitation programs' standards.
- Avoid resuscitation in the mother room, if possible.
- If needed, the neonates should be transferred in a closed incubator.

### Specific Findings in Infected Newborns and Infants<sup>31–47</sup>

Minimal information is available regarding peripartum COVID-19. Although separate studies by Rothe et al. and Kupferschmidt showed no documented cases of intrauterine transmission.<sup>31,32</sup> others reported several cases of transmission during pregnancy.<sup>33–35</sup> The American College of Obstetricians and Gynecologists/Society of Maternal-Fetal Medicine has published online guidance for the evaluation and care of pregnant women with suspected COVID-19.

### Transmission through Breast Milk or during Feeding

It is unclear whether breast milk can transmit SARS-CoV-2. There is one study of testing breast milk that found no virus in the maternal milk of six patients.<sup>36</sup> However, the usual droplet transmission could occur through close contact during breast or bottle feeding. Therefore, the standard precaution of transmission prevention should be in place during infancy care.

### Precautions for the Asymptomatic Newborns in the Delivery Room

The following Precautions need to be taken for the asymptomatic newborns in the delivery room:

- Well-babies not requiring medical interventions can be managed depending on the local institutional guidelines and resources. They can remain with their mother in their designated room or can be temporarily separated from his/her mother and will be cared in closed incubator by a designated nurse. The mother should be counselled about the risk and benefits of temporarily separation from her baby until her transmission-based precautions are discontinued.
- The baby may be bathed as soon as reasonably possible after birth. The benefit of removal the virus potential contaminate secretions/materials from the baby's skin should be weighed against the risk of hypothermia and hypoglycemia.
- Well-babies may be tested for two reasons: (1) to ascertain any vertical transmission and (2) research purposes. To test for vertical transmission, the infant need to be tested within 2–3 hours of birth; adequate precautions need to be observed to not contaminate the sample by the maternal secretions.
- If a mother is acutely unwell, an alternative nonquarantined caregiver/relative should be identified to provide care for the baby at home or in a designated room, not in the neonatal unit and the babies should be isolated from their mothers.
- Early discharge may be preferred with clearly listed guidance for safety advice in close liaison with community health-care providers.
- All care should be consistent with the PPE guidelines.

### Postnatal Care of both Newborn Infants and COVID-19-confirmed Mothers

As the rate of infection of COVID-19 is rare in newborns, other causes of respiratory distress immediately after birth are more likely than COVID-19. Therefore, health-care providers should actively consider other differential diagnoses for respiratory illness in the infants.

The rate of infection in infants less than one year is exceptionally low. The primary presentations of infants confirmed to have COVID-19 infections were cough and fever. Hence, it remains difficult to describe a specific pattern of presentation of COVID-19 infection in newborns.<sup>37</sup>

### NICU Precautions for the Symptomatic Newborn Infants born to Mothers with Suspected or Confirmed COVID-19 Infections

The need for admission to the NICU requires careful evaluation. The following precautions need to be considered while giving invasive or no invasive respiratory support:

- All the procedures and investigations should be carried out in a single isolated room with a minimal number of staff. Ideally,

this room should have negative pressure. If an isolation room is not available, these infants should be cohorted in a designated area (corner) of the NICU.

- The cessation of isolation precautions need careful consideration. We have noted some variation in the management policies in different hospitals. We obtain nasopharyngeal swab(s) or endotracheal tube secretions on the postnatal day 10. If the test result is negative, then we repeat the swab after 24 hours. For positive results, we repeat the tests after 48–72 hours; the availability of test results varies with individual laboratories. We continue to take all precautions until we have two successive negative swabs.
- Incubators, ventilators, intubation tools, intravenous catheters, and central arterial or venous lines should be removed carefully, preferably inside a negative pressure isolation room.
- Intubation, suctioning, and other procedures with increased risk of exposure to respiratory sections should be performed with full PPE, including gloves, eye goggles, face shield, and N95 masks.
- The additional care such as intravenous antibiotics and phototherapy needs to be evaluated for the site, as to whether additional care can safely be provided at the mother's bedside (postnatal care) or not.
- NICU admissions should be avoided if at all possible and safe. Infants who require NICU care should be assessed in a designated area in the labor room or ward by a skilled neonatal team member wearing appropriate PPE.
- Incubators may serve as a useful isolation device, even when these are not otherwise indicated. This might be safer than open bed management.
- The need for all clinical investigations should be carefully evaluated if those are needed to meet the standards of care. In many situations, point-of-care testing may be a safer alternative.
- Intubation should only be undertaken by staff with appropriate competencies. Videolaryngoscope intubation may be useful when possible to reduce the proximity to the baby's airway and the risk of transmission. Noninvasive respiratory support should be carefully considered for the risk of associated aerosolization and higher risk.
- All babies requiring respiratory support should be nursed in an incubator.
- All equipment coming out of the isolation room should be cleaned as per predetermined cleaning policies.
- We maintain a logbook for staff entering or dealing with the patient.

### **NICU Precautions for Asymptomatic Newborn Infants born to Mothers with Suspected or Confirmed COVID-19 Infections**

Well-babies of COVID-19 suspected or confirmed mothers should be isolated with their mothers; these infants are considered potentially infectious for at least 14 days. We discharge these infants to be sent home as early as possible.

For infants who need observation without needs for respiratory support, only droplet/contact precautions are appropriate. If available, we treat these infants in an isolation room with negative pressure.

When the respiratory symptoms have resolved, the infants may be relocated to other rooms to free up the negative pressure rooms for other patients. We have had to use these policies during

the period when the admission rates of newborns of COVID-19-suspected or -confirmed mothers were higher than the capacity of the local unit. For extra precautions, these asymptomatic infants were cohorted in an isolation area.

If the mother is a confirmed COVID-19 positive case, then her baby should be admitted to NICU. As well, if the baby showed any symptoms, then to be tested as early as possible.

### **Hospital Transport of Newborns at Risk of COVID-19 Infection**

Hospitals should develop clear guidelines for transport between the delivery room, postpartum care, and NICU. Transportation of these infants to another ward/bed should be limited, if possible. These infants should be transferred in a closed incubator with full PPE.

### **Outborn Transport of Newborn Infants born to Mothers with Suspected or Confirmed COVID-19 Infections**

We currently have limited data to establish guidelines to transfer outborn neonatal transport of newborns of COVID-19-confirmed or -suspected mothers. During air or ground transport, the personnel are in close contact with each other and with the baby. The infant might need interventions during transport. The possibility of transmission from COVID-19-suspected or -confirmed mothers may be influenced by gestational and postnatal ages, duration of transport, absence or presence of symptoms, and the need for invasive or noninvasive respiratory support. However, even if a nasopharyngeal swab is done at birth, the earliest result would be available after 24–48 hours. Therefore, it is advisable to assume all infants born to COVID-19-confirmed or -suspected mothers to be positive and implement all droplet/contact precautions.

### **Testing the Newborn**

We do not currently have standard, immediately available tests to determine COVID-19 infections in neonates. Early documentation of COVID-19 infections may still take 36 hours. Given this, testing an infant born to a mother with suspected or confirmed COVID-19, it seems prudent to recommend the following:

- Testing asymptomatic neonates of COVID-19-suspected or -confirmed mothers is needed to detect vertical transmission or for research purposes. The test should be done before the possible occurrence of postnatal contamination, which is within 1–3 hours after birth.
- Testing symptomatic neonates born to suspected or confirmed COVID-19 mothers is needed per the local hospital's guidelines. However, two negative tests obtained 24 hours apart might be needed to declare a negative result. If positive, the baby will require supportive care institutional policy with full PPE and droplet/contact precautions, with the involvement of an infectious disease specialist.

### **Visitation**

Social distancing practices have changed the hospital visiting policies and have been restricted to very necessary visits in many centers. Parents who test positive should be prevented from visiting their baby until they declared negative. A mother or a father with negative screening should be allowed to visit her/his baby. However, we have been cautious and have restricted other family visits.

## Breastfeeding

Breastfeeding should be encouraged by supporting mothers who have been separated from their babies to expressed breast milk. Mothers should have a designated breast pump for exclusive use. Local infection control policies should be consulted in the cleansing.

It is not yet clear whether COVID-19 can be transferred via breast milk. Despite the low risk of COVID-19 transmission via breast milk, pasteurization of the breast milk might be beneficial. Alternatively, donor breast milk or formula milk should be considered. Evidence have showed that other coronaviruses are destroyed by pasteurization, but there are no evidence whether COVID-19 (if present in the breast milk) would be similarly destroyed. The Canadian Pediatric Society and the WHO recommend skin-to-skin contact and kangaroo care.

## Newborn Screening

Clinical examination and screening for a newborn of COVID-19 positive mother should be carried out before discharge as per the standard of practice. Audiology screening of asymptomatic COVID-19-confirmed or -suspected mothers should be deferred to after discharge by 14 days.

## Managing Unit Capacity

Staffing plan should be in place to manage situations due to sudden increase in NICU census or staff shortage as a result of direct or indirect COVID-19 pandemic. Patient ward and sign-in and -out rounds of the health-care providers should be organized to reduce direct contact. Virtual meetings may be used for work-related meetings, educational activities, and other meeting for formulating policies.

There is no need for staff to self-isolate after looking after a suspected or confirmed case of COVID-19 if correct PPE precautions have been taken. Any staff concerns regarding contact with a possible case should be discussed with him/her to determine the necessary steps that should be taken.

## Imaging X-ray, Ultrasound, Magnetic Resonance Imaging, and Lab Tests

Imaging requests need to be discussed with the radiology department and with the senior neonatologist. Possibilities of deferral of the radiology/laboratory tests should be considered if the medical condition of the baby allowed. Otherwise, standard PPE should be the donned by the technician, and care of cleaning and sterilization between the procedures should be done.

## Respiratory Support of Newborns at Risk of COVID-19

Aerosol generating medical procedures that should be performed using full PPE include (1) intubation, extubation, and surfactant administration; (2) management with continuous positive pressure ventilation (CPAP), bi-level positive airway pressure, high-flow nasal cannula, noninvasive positive pressure ventilation, invasive conventional mechanical ventilation, high-frequency oscillatory ventilation, and high-frequency jet ventilation; (c) nebulized therapy; and (d) open airway suctioning. Aerosolization, noninvasive respiratory support, surfactant administration, and airway suctioning are associated with significant aerosolization and should also be performed using full PPE. Assisted ventilation with a heat and moisture exchanger (HME) filter installed at the expiratory port of the ventilator is preferred over CPAP, biphasic CPAP, and high-flow therapy to reduce the risk of aerosolizing COVID-19 in the room.

In patients receiving positive pressure ventilation, the following procedures should be considered:

- To use disposable circuits only when transporting patients from the delivery room and in the NICU.
- To use a disposable expiratory valve.
- To connect a HME filter at the expiratory port of the ventilator. The HME filter is connected only when connecting the circuit to the patient.
- Change the HME filter every 24 hours.

To use a closed suction system, surfactant therapy, inhaled nitric oxide, high-frequency ventilation, continuous renal replacement therapy, and extracorporeal membrane oxygenation may be considered as for non-COVID-19 patients when required. All equipment coming out of the isolation room should be cleaned as per local institute policy for cleaning potentially infectious equipment.

The respiratory support equipment should be disinfected per protocol following its use on a COVID-19 patient. It is then kept aside and not used for a minimum of 14 days to a maximum of 28 days. But in case there is a shortage of machines, it can be used for the next suspected positive case. The disposable of the consumables used for respiratory support follows the same protocol as what has been followed so far for the waste management according to the CDC guidelines for COVID-19.<sup>47</sup>

## REFERENCES

1. World Health Organization. Director-General's remarks at the media briefing on 2019-nCoV on 11 February 2020. <https://www.who.int/dg/speeches/detail/who-director-general-s-remarks-at-the-media-briefing-on-2019-ncov-on-11-february-2020> (Accessed on February 12, 2020).
2. Zhou P, Yang XL, Wang XG, et al. A pneumonia outbreak associated with a new coronavirus of probable bat origin. *Nature* 2020;579:270–273. DOI: <https://doi.org/10.1038/s41586-020-2012-7>.
3. World Health Organization. Novel coronavirus situation report-2. January 22, 2020. <https://www.who.int/docs/default-source/coronaviruse/situation-reports/20200122-sitrep-2-2019-ncov.pdf> (Accessed on January 23, 2020).
4. Van Doremalen N, Bushmaker T, Morris DH, et al. Aerosol and surface stability of SARS-CoV-2 as compared with SARS-CoV-1. *N Engl J Med* 2020; 382:1564–1567. DOI: 10.1056/NEJMc2004973.
5. Cheung KS, Hung IF, Chan PP, et al. Gastrointestinal manifestations of SARS-CoV-2 infection and virus load in fecal samples from the Hong Kong Cohort and Systematic Review and Meta-analysis. *Gastroenterology* 2020;159(1):8195. DOI: 10.1053/j.gastro.2020.03.065.
6. Zheng S, Fan J, Yu F, et al. Viral load dynamics and disease severity in patients infected with SARS-CoV-2 in Zhejiang province, China, January-March 2020: Retrospective cohort study. *BMJ* 2020;369:m1443. DOI: <https://doi.org/10.1136/bmj.m1443>.
7. Zou L, Ruan F, Huang M, et al. SARS-CoV-2 viral load in upper respiratory specimens of infected patients. *N Engl J Med* 2020; 382:1177–1179. DOI: 10.1056/NEJMc2001737.
8. McMichael TM, Clark S, Pogosjans S, et al. COVID-19 in a Long-Term Care Facility – King County, Washington, February 27–March 9, 2020. *MMWR Morb Mortal Wkly Rep* 2020; 69:339–342. DOI: 10.15585/mmwr.mm6912e1.
9. Kakimoto K, Kamiya H, Yamagishi T, et al. Initial investigation of transmission of COVID-19 among crew members during quarantine of a cruise ship – Yokohama, Japan, February 2020. *MMWR Morb Mortal Wkly Rep* 2020; 69:312. DOI: <http://dx.doi.org/10.15585/mmwr.mm6911e2>.
10. Burke RM, Midgley CM, Dratch A, et al. Active monitoring of persons exposed to patients with confirmed COVID-19 – United



- States, January–February 2020. *MMWR Morb Mortal Wkly Rep* 2020; 69:245–246. DOI: 10.15585/mmwr.mm6909e1.
11. Yung CF, Kam KQ, Wong MSY, et al. Environment and personal protective equipment tests for SARS-CoV-2 in the isolation room of an infant with infection. *Ann Intern Med* 2020;173(3):240242. DOI: 10.7326/M20-0942.
  12. World Organization for Animal Health. Questions and Answers on the 2019 Coronavirus Disease (COVID-19), section on Surveillance and events in animals. <https://www.oie.int/en/scientific-expertise/specific-information-and-recommendations/questions-and-answers-on-2019-novel-coronavirus/> (Accessed on April 13, 2020).
  13. Guan WJ, Ni ZY, Hu Y, et al. Clinical characteristics of Coronavirus Disease 2019 in China. *N Engl J Med* 2020; 382:1708–1720. DOI: 10.1056/NEJMoa2002032.
  14. Yang X, Yu Y, Xu J, et al. Clinical course and outcomes of critically ill patients with SARS-CoV-2 pneumonia in Wuhan, China: a single-centered, retrospective, observational study. *Lancet Respir Med* 2020;8(5):475–481. DOI: 10.1016/S2213-2600(20)30079-5.
  15. Wu Z, McGoogan JM. Characteristics of and important lessons from the Coronavirus Disease 2019 (COVID-19) outbreak in China: Summary of a report of 72 314 cases from the Chinese Center for Disease Control and Prevention. *JAMA* 2020;323(13):1239–1242. DOI: 10.1001/jama.2020.2648.
  16. Lighter J, Phillips M, Hochman S, et al. Obesity in patients younger than 60 years is a risk factor for Covid-19 hospital admission. *Clin Infect Dis* 2020;71(15):896–897. DOI: 10.1093/cid/ciaa415.
  17. Dai M, Liu D, Liu M, et al. Patients with cancer appear more vulnerable to SARS-CoV-2: A multi-center study during the COVID-19 outbreak. *Cancer Discov* 2020;10(6):783–791. DOI: 10.1158/2159-8290.
  18. Chen N, Zhou M, Dong X, et al. Epidemiological and clinical characteristics of 99 cases of 2019 novel coronavirus pneumonia in Wuhan, China: A descriptive study. *Lancet* 2020; 395:507–513. DOI: 10.1016/S0140-6736(20)30211-7.
  19. Huang C, Wang Y, Li X, et al. Clinical features of patients infected with 2019 novel coronavirus in Wuhan, China. *Lancet* 2020; 395:497–506. DOI: 10.1016/S0140-6736(20)30183-5.
  20. Goyal P, Choi JJ, Pinheiro LC, et al. Clinical Characteristics of Covid-19 in New York City. *N Engl J Med* 2020;382(24):2372–2374. DOI: 10.1056/NEJMc2010419.
  21. Wong HYF, Lam HYS, Fong AH, et al. Frequency and distribution of chest radiographic findings in COVID-19 positive patients. *Radiology* 2019;296(2):E72–E78. DOI: 10.1148/radiol.2020201160.
  22. ACR recommendations for the use of chest radiography and computed tomography (CT) for suspected COVID-19 infection. <https://www.acr.org/Advocacy-and-Economics/ACR-Position-Statements/Recommendations-for-Chest-Radiography-and-CT-for-Suspected-COVID19-Infection> (Accessed on April 01, 2020).
  23. Shi H, Han X, Jiang N, et al. Radiological findings from 81 patients with COVID-19 pneumonia in Wuhan, China: A descriptive study. *Lancet Infect Dis* 2020; 20:425–434. DOI: 10.1016/S1473-3099(20)30086-4.
  24. Zhao W, Zhong Z, Xie X, et al. Relation between chest CT findings and clinical conditions of Coronavirus disease (COVID-19) pneumonia: A multicenter study. *AJR Am J Roentgenol* 2020; 214(5):1072–1077. DOI: 10.2214/AJR.20.22976.
  25. Patel A, Jernigan DB, 2019-nCoV CDC Response Team. Initial Public Health Response and Interim Clinical Guidance for the 2019 Novel Coronavirus Outbreak – United States, December 31, 2019–February 4, 2020. *MMWR Morb Mortal Wkly Rep* 2020; 69:140–146. DOI: 10.15585/mmwr.mm6905e1.
  26. <https://www.fda.gov/news-events/press-announcements/coronavirus-covid-19-update-fda-authorizes-first-test-patient-home-sample-collection> (Accessed on April 22, 2020).
  27. Guo L, Ren L, Yang S, et al. Profiling early humoral response to diagnose novel Coronavirus disease (COVID-19). *Clin Infect Dis* 2020;71(15):778–785. DOI: <https://doi.org/10.1093/cid/ciaa310>.
  28. Zimmermann P, Curtis N. Coronavirus infections in children including COVID-19: An overview of the epidemiology, clinical features, diagnosis, treatment and prevention options in children. *Pediatr Infect Dis J* 2020;39:355–368. DOI: 10.1097/INF.0000000000002660.
  29. Swenson K. New D.C. hospital numbers suggest kids do face some risk of coronavirus hospitalization. *Washington Post*, April 25, 2020. Available at: [https://www.washingtonpost.com/local/new-dc-hospital-numbers-suggest-kids-do-face-some-risk-of-coronavirus-hospitalization/2020/04/25/5e78c268-86fe-11ea-878a-86477a724bdb\\_story.html](https://www.washingtonpost.com/local/new-dc-hospital-numbers-suggest-kids-do-face-some-risk-of-coronavirus-hospitalization/2020/04/25/5e78c268-86fe-11ea-878a-86477a724bdb_story.html) (Accessed on April 27, 2020).
  30. CDC COVID-19 Response Team. Coronavirus disease 2019 in children – United States, February 12–April 2, 2020. *MMWR Morb Mortal Wkly Rep* 2020; 69:422–426. DOI: 10.15585/mmwr.mm6914e4.
  31. Rothe C, Schunk M, Sothmann P, et al. Transmission of 2019-nCoV infection from an asymptomatic contact in Germany. *N Engl J Med* 2020; 382:970–971. DOI: 10.1056/NEJMc2001468.
  32. Kupferschmidt K. Study claiming new coronavirus can be transmitted by people without symptoms was flawed. *Science*. February 3, 2020. <https://www.sciencemag.org/news/2020/02/paper-non-symptomatic-patient-transmitting-coronavirus-wrong> (Accessed on February 04, 2020).
  33. Yu P, Zhu J, Zhang Z, et al. A familial cluster of infection associated with the 2019 novel coronavirus indicating potential person-to-person transmission during the incubation period. *J Infect Dis* 2020;221(11):1757–1761. DOI: 10.1093/infdis/jiaa077.
  34. Bai Y, Yao L, Wei T, et al. Presumed asymptomatic carrier transmission of COVID-19. *JAMA* 2020;323(14):1406–1407. DOI:10.1001/jama.2020.2565.
  35. Hu Z, Song C, Xu C, et al. Clinical characteristics of 24 asymptomatic infections with COVID-19 screened among close contacts in Nanjing, China. *Sci China Life Sci* 2020;63:706–711. DOI: 10.1007/s11427-020-1661-4.
  36. Chen H, Guo J, Wang C, et al. Clinical characteristics and intrauterine vertical transmission potential of COVID-19 infection in nine pregnant women: a retrospective review of medical records. *Lancet* 2020;395:809–815. DOI: [https://doi.org/10.1016/S0140-6736\(20\)30360-3](https://doi.org/10.1016/S0140-6736(20)30360-3).
  37. Dong Y, Mo X, Hu Y, et al. Epidemiological characteristics of 2143 pediatric patients with 2019 coronavirus disease in China. *Pediatrics* 2020;58(4):712–713. DOI: 10.1542/peds.2020-0702.
  38. <https://www.health.nsw.gov.au/Infectious/diseases/Pages/coronavirus-professionals>.
  39. [https://www.health.gov.au/news/health-alerts/novel-coronavirus-2019-ncov-health-alert?utm\\_source=health.gov.au&utm\\_medium=redirect&utm\\_campaign=digital\\_transformation&utm\\_content=health-topics/novel-coronavirus-2019-ncov](https://www.health.gov.au/news/health-alerts/novel-coronavirus-2019-ncov-health-alert?utm_source=health.gov.au&utm_medium=redirect&utm_campaign=digital_transformation&utm_content=health-topics/novel-coronavirus-2019-ncov).
  40. <https://www.who.int/emergencies/diseases/novel-coronavirus-2019>.
  41. [https://www.cdc.gov/coronavirus/2019-ncov/index.html?CDC\\_AA\\_refVal=https%3A%2F%2Fwww.cdc.gov%2Fcoronavirus%2Findex.html](https://www.cdc.gov/coronavirus/2019-ncov/index.html?CDC_AA_refVal=https%3A%2F%2Fwww.cdc.gov%2Fcoronavirus%2Findex.html).
  42. <https://www.esicm.org/resources/coronavirus-public-health-emergency/>.
  43. <https://www.anzics.com.au/coronavirus/>.
  44. <https://www.mja.com.au/system/files/2020-03/Updated%20SAS%20COVID19%20consensus%20statement%2017%20March%202020.pdf>.
  45. <https://emcrit.org/ibcc/covid19/>.
  46. <https://youtu.be/J6yZz3YPuQI>.
  47. <https://www.cdc.gov/coronavirus/2019-ncov/infection-control/control-recommendations.html>.

# Hypoxic–Ischemic Encephalopathy: To Cool, or Not to Cool, That Is the Question

Shabih Manzar<sup>1</sup>, Ramachandra Bhat<sup>2</sup>, Sheila Asghar<sup>3</sup>, Rosario Riel–Romero<sup>4</sup>, Nitin Walyat<sup>5</sup>, Octavio Arevalo–Espejo<sup>6</sup>, Maroun Mhanna<sup>7</sup>

Received on: 30 June 2022; Accepted on: 15 September 2022; Published on: 07 October 2022

## ABSTRACT

An infant was born at 38 weeks' gestation. The assigned Apgar scores were 2, 3, and 5 at 1, 5, and 10 minutes, respectively. The physical examination showed hypotonia, absent gag reflex, and poor response to pain. At 9 hours after birth, the infant was noted to have a subtle seizure and bradypnea. The infant was intubated and started on anticonvulsant therapy. A brain magnetic resonance imaging (MRI) and an electroencephalogram (EEG) were obtained. This report presents the clinical and diagnostic dilemma that is typically associated with decisions needed for treatment with therapeutic hypothermia (TH).

**Keywords:** Apgar, Bradypnea, Electroencephalogram, Gag reflex, Gestation, Infant, Neonatal, Newborn.

*Newborn* (2022): 10.5005/jp-journals-11002-0037

## KEY POINTS

- Therapeutic hypothermia is provided to neonates with an established diagnosis of hypoxic–ischemic encephalopathy (HIE). However, many cases do not fit into the classic definition of HIE. The infant described in this article also presents such a dilemma.
- Current recommendations suggest that TH should be considered in infants who (a) Do not have a blood gas report available from the first hour after birth or the report shows a pH between 7.01–7.15 or a base deficit between 10–15.9 mmol/L; and (b) Meet the following two additional criteria: (i) A history of an acute perinatal event such as cord prolapse and/or fetal heart rate (FHR) decelerations and (ii) Either the need for assisted ventilation initiated at birth and continued for 10 minutes, or an Apgar score below or equal to 5 at 10 minutes after birth.
- Therapeutic hypothermia should be started within 6 hours after birth, but some neonates with HIE may qualify only after this temporal cut-off. This paper discusses these options in reference to a case.

## CASE

An infant was born at 38 weeks' gestation *via* spontaneous vaginal delivery. The neonatal intensive care unit (NICU) team was called to the labor room after delivery and reached about 5 minutes following birth. The obstetric and labor and delivery teams provided continuous positive airway pressure (CPAP) during this period. The infant maintained a good heart rate but had poor respiratory efforts, low tone, and poor reflexes. The CPAP was continued until the infant showed clear and spontaneous respiratory efforts. Apgar scores of 2, 3, and 5 were assigned at 1, 5, and 10 minutes, respectively. The infant was transferred to NICU for further care and management.

The FHR/cardiac monitoring *strips* obtained 4 hours prior to delivery are shown in [Figure 1](#). Cord blood gases and the first blood gas obtained at 10 minutes after birth are shown in [Table 1](#). The physical examination at this time showed hypotonia, absent gag

<sup>1,2,5,7</sup>Department of Pediatrics, Section of Neonatology, Louisiana State University Health Sciences Center, Shreveport, Louisiana, United States of America

<sup>3,4</sup>Department of Pediatrics, Section of Pediatric Neurology, Louisiana State University Health Sciences Center, Shreveport, Louisiana, United States of America

<sup>6</sup>Department of Radiology, Section of Neuroradiology, Louisiana State University Health Sciences Center, Shreveport, Louisiana, United States of America

**Corresponding Author:** Shabih Manzar, Department of Pediatrics, Section of Neonatology, Louisiana State University Health Sciences Center, Shreveport, Louisiana, United States of America, Phone: +1 (318) 626-1623, e-mail: shabih.manzar@lsuhs.edu

**How to cite this article:** Manzar S, Bhat R, Asghar S, *et al.* Hypoxic–Ischemic Encephalopathy: To Cool, or Not to Cool, That Is the Question. *Newborn* 2022;1(3):320–326.

**Source of support:** Nil

**Conflict of interest:** None

reflex, and poor responses to pain. At 9 hours, the infant was noted to have subtle seizures and bradypnea. The infant was intubated and started on anticonvulsant therapy. The brain MRI obtained at about 12 hours after birth is shown in [Figure 2](#). Continuous electroencephalogram (cEEG) showed severe background slowing with a pattern of burst suppression ([Fig. 3](#)). Since seizures were first noted only 6 hours following birth, there were important clinical and diagnostic dilemmas in the decision about treatment with TH.

## Views of the Neonatologist Who admitted the Infant to the NICU

There was no history of any acute perinatal events such as late or variable decelerations, cord prolapse, cord rupture, uterine rupture, maternal trauma, hemorrhage, or cardiorespiratory arrest. The cord blood gas and fetal strip before birth were unremarkable for signs of perinatal hypoxia ([Table 1](#) and [Fig. 1](#)). The total Apgar scores at



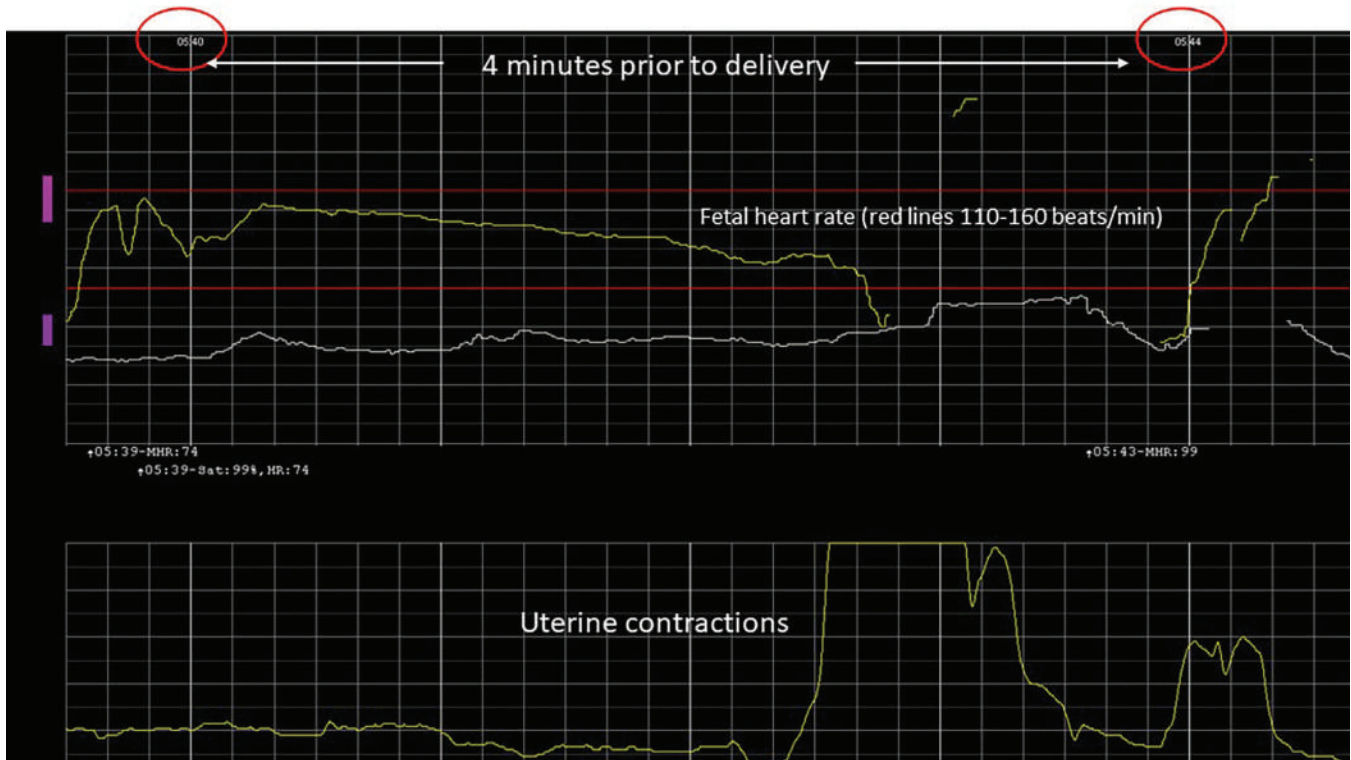


Fig. 1: Cardiotocography (CTG) obtained 4 minutes prior to delivery. Early deceleration was noted with uterine contraction.

Table 1: Cord blood gases and first blood gas obtained at 10 minutes after birth

|                  | Cord gas (arterial) | Cord gas (venous) | First postnatal gas (10 minutes of life) |
|------------------|---------------------|-------------------|--|
| Ph               | 7.283               | 7.282             | 7.21                                     |
| pCO <sub>2</sub> | 40.4                | 41.9              | 33.9                                     |
| pO <sub>2</sub>  | 34.6                | 34.0              | 77.8                                     |
| HCO <sub>3</sub> | 18.1                | 18.5              | 14.7                                     |
| BD               | -7.6                | -7.0              | -14.1                                    |
| FiO <sub>2</sub> | 0.21                | 0.21              | 0.21                                     |

pCO<sub>2</sub>, partial pressure of carbon dioxide (mm Hg); pO<sub>2</sub>, partial pressure of oxygen (mm Hg); HCO<sub>3</sub>, bicarbonate (mEq/L); BD, base deficit (mEq/L); FiO<sub>2</sub>, fraction of inspired oxygen

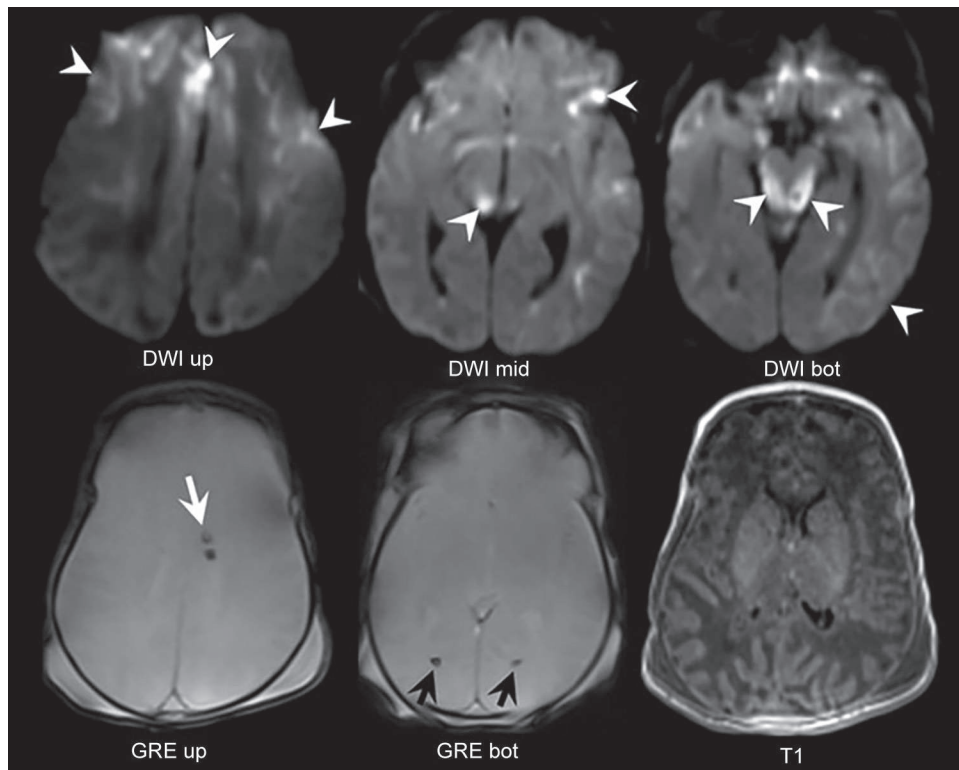
10 minutes after birth were 5 (2 for heart rate, 2 for respiratory efforts, and 1 for color, with oximetry of 100% breathing room air). If the color was given a score of 2, the infant would not have met the entry criteria for TH based on the protocol and clinical algorithm (Flowchart 1).<sup>1,2</sup> The absence of the gag reflex and poor responses to pain are not included in Sarnat and Sarnat scoring.<sup>3</sup>

In its statement for the management of neonatal encephalopathy with hypothermia, The Committee on Fetus and Newborn of the American Academy of Pediatrics has used the criteria from the whole body cooling study.<sup>1,4</sup> They stated that a TH should be considered if (a) The blood gas report was either not available from the first hour after birth or it showed either a pH between 7.01 and 7.15 or a base deficit between 10 and 15.9 mmol/L; and (b) Two additional criteria are notable: (i) A history of an acute perinatal event (e.g., cord prolapse, FHR decelerations) and (ii) Either the need for assisted ventilation initiated at birth and continued for 10 minutes, or an Apgar score below or equal to 5 at 10 minutes after

birth. In view of this statement, an infant will qualify for cooling if she/he had a blood gas with a base deficit of 14 and was positive on two additional criteria within an hour following birth. Our patient had an Apgar score of 5 at 10 minutes after birth but did not have a history of any acute perinatal event.

### Views of the Neonatologist Who took Care of the Infant Prior to the Onset of Seizures

Cord gases, if sampled properly and if both arterial and venous cord blood samples are obtained<sup>5</sup> can provide an accurate and objective assessment of the physiological stability of an infant during the parturition.<sup>6</sup> The presence of either an arterial or venous cord blood pH below or equal to 7.0 or a base deficit of above or equal to 16 indicates a significant hypoxic-ischemic (HI) event prior to birth, mandating a standardized neurological assessment of the infant for moderate to severe encephalopathy.<sup>1,7</sup> As the infant's first blood gas obtained within the first hour of postnatal age indicated the presence of a base deficit between 10 and 15.9, two additional criteria need to be met to be eligible for the standardized neurological examination.<sup>1</sup> Even though the infant had 10 minutes Apgar score below or equal to 5, the lack of an identifiable acute perinatal event or its indirect evidence of it through non-reassuring fetal status could have excluded the perinatal asphyxial event as the probable etiology for perinatal depression. However, acute perinatal events may have been missed due to FHR tracing errors<sup>8</sup> or intrapartum umbilical cord accidents.<sup>9</sup> The absence of moderate to severe encephalopathy on neurological assessment also probably excluded the possibility of significant acute perinatal asphyxia. As a result, the infant did not meet the eligibility criteria for TH, which is a proven treatment for infants with moderate to severe encephalopathy.<sup>1</sup> Nevertheless, increasing confidence in the execution of TH coupled with the



**Fig. 2:** The top row shows axial DWI images of the brain at three different levels, the corresponding confirmatory apparent diffusion coefficient (ADC) maps are not shown. The arrowheads indicate areas of restricted diffusion involving the cortex of the bilateral cerebral hemispheres as well as the dorsal brainstem. There was also involvement of the right thalamus and the left cerebellar hemisphere (not shown). The bottom row shows Gradient Echo sequences at two different levels (left and middle panels), and an axial T1 image on the right inferior side. The GRE images show a left caudothalamic groove hemorrhage (white arrow), and a small amount of intraventricular hemorrhage pooling at the tips of the occipital horns of the lateral ventricles (black arrows). The axial T1 image shows normal myelination for the patient's age, with no abnormal signal of the cortical or deep white matter

availability of institutional level protocols for the management of infants while receiving cooling therapy has led to the adaptation of cooling therapy for even infants with mild encephalopathy.<sup>10</sup> As the infant met the extended biochemical criteria, except for the absence of reliable evidence of acute perinatal event, and exhibited features of mild encephalopathy, the administration of TH could have been considered only after a thorough discussion with parents about the lack of high-quality evidence from randomized controlled trials and consequently, the lack of understanding of risk-benefit ratios.<sup>10</sup> The TH could have been administered only after parental consent.<sup>10</sup>

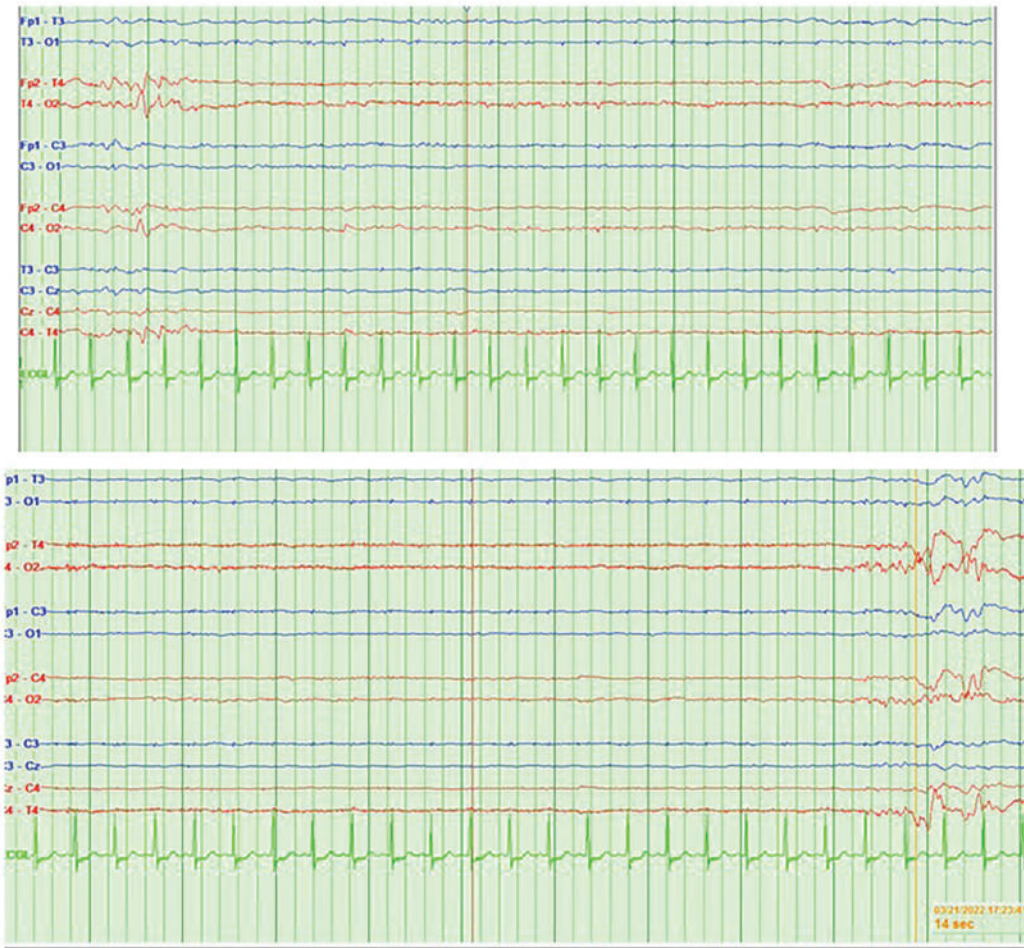
### Views of the Neonatologist Who took Care of the Infant after the Onset of Seizures

In the current case, seizures indicated the presence of considerable brain injury possibly due to hypoxic-ischemia. The acid-base imbalance at birth could be viewed as a biochemical biomarker suggesting a prior HI event.<sup>1,5-7</sup> The occurrence of seizures could also be viewed as favoring a need for TH. The best available evidence is from the late hypothermia trial, wherein the magnitude of the beneficial impact of TH was lower than the initiation of TH within 6 hours of postnatal age.<sup>11</sup> Nevertheless, the evidence from the trial indicates no short-term harmful effects of late initiation (within 24 h after birth) of TH.<sup>11</sup> However, late TH is not a proven treatment for infants with evolving HIE with delayed onset of symptoms, and so parental informed consent must be obtained.

Moreover, *in utero* occurrence of chronic-prolonged or sub-acute partial and intermittent HI insult should also be strongly considered, for which TH may not have a beneficial impact as primary and reperfusion injury both would have occurred prior to birth.<sup>12,13</sup> Similarly, other causes of perinatal brain injury, including perinatal ischemic stroke, sinus venous thrombosis, subarachnoid, and other intracranial hemorrhages, should also be considered as differential diagnoses.<sup>14</sup> Magnetic resonance imaging studies of the brain, along with other ancillary tests, including EEG background activity, and transcranial Doppler resistive index, could also be considered to delineate the presence of HI brain injury before approaching parents for a discussion on TH.

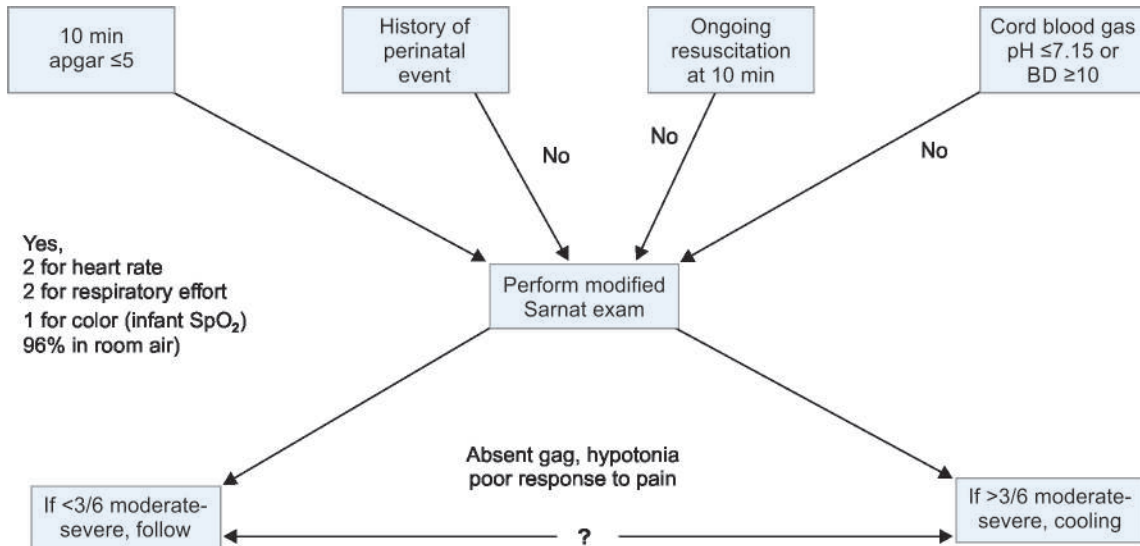
### Views of the Neonatologist Who took Care of the Infant after an MRI Scan had been Obtained

The presence of a distinctive pattern of MRI changes suggestive of global HI injury is indicative of a possible *in utero* occurrence of sub-acute or chronic prolonged-partial HI insult based on the review of the chronology of the evolution of MRI changes following the HI in animal studies.<sup>15</sup> In the current case, the combined findings of cord gas and the postnatal evolution of CNS manifestation coupled with MRI changes might also suggest an acute intrapartum hypoxic event on the chronic partial HI injury.<sup>16</sup> Once again, the benefit of TH is controversial, and the risk benefits need to be extensively discussed with parents before initiating TH.



**Fig. 3:** Electroencephalogram on the first day of life showing a burst suppression pattern with interburst intervals lasting as long as 40 seconds (normal IBI for AOG is 6 seconds)

**Flowchart 1:** Entry criteria for TH based on the protocol and clinical algorithm<sup>1,2</sup>



Modified from Bonifacio SL, Hutson S. The Term Newborn: Evaluation for Hypoxic-Ischemic Encephalopathy. *Clin Perinatol.* 2021;48(3):681-695

## Views of Pediatric Neurologists Who were consulted for Care of the Infant

Neonatal HIE occurs in 2–3 per 1,000 newborn children and is one of the most frequently-seen causes of neonatal death and long-term disability.<sup>17,18</sup> Moreover, TH is the only neuroprotective treatment shown to reduce the risk of cerebral palsy and significant disability in RCTs in children with moderate and severe HIE.<sup>19</sup>

In the hours that ensue after an HIE injury, time is of essence, and most clinical trials<sup>1,20,21,22</sup> advocated hypothermia (selective head or whole-body cooling within 6 hours of birth to target temperatures of 33.5°C to 34.5°C for 72 hours). Hypothermia has so far been tried only in infants born at term ( $\geq 37$  weeks) and late preterm ( $\geq 35$  weeks) gestation with moderate-to-severe HIE. Furthermore, Jia et al.<sup>23</sup> in their trial compared hypothermia in neonates within 6–12 hours. Their conclusion was that hypothermia treatment was of benefit in newborns with moderate HIE even up to 12 hours. Conversely, newborns with severe HIE showed a therapeutic effect for hypothermia treatment beginning within 6 hours. Newborns with mild HIE, even without hypothermic treatment, showed a good prognosis.

Hence, it would be vital to qualify HIE in terms of severity immediately after birth, as in our patient, so the decision to cool or not cool may be more informed. Sarnat and Sarnat<sup>3</sup> classified HIE as mild (stage 1 associated with hyperalertness, sympathetic overdrive, and a normal EEG), moderate (stage 2 associated with moderate encephalopathy marked by obtundation, hypotonia, multifocal seizures, and an EEG showing periodic or continuous delta activity), or severe (stage 3 associated with infants were stuporous and flaccid with an isoelectric or periodic EEG) based on features of the neurologic examination and early EEG findings.

- Our patient's initial cord blood pH was normal, and his lactate and liver function tests (LFTs) were only minimally elevated. Also, our patient never demonstrated acute tubular necrosis and his echocardiogram (obtained later) did not show evidence of hypoxic cardiomyopathy or tricuspid regurgitation. All these features suggest that, perhaps, he only had a mild HIE with no other evidence of organ injury. However, we would rather suggest that the following factors point to severe HIE rather than mild to moderate HIE despite the above in this patient: The MRI in the first few hours of life already demonstrated cortical, thalamic, and brainstem cytotoxic edema.
- The cEEG which showed a burst suppression pattern, an electrical signature of severe cortical damage.
- An initial neurological exam showing profound hypotonia and lack of responsiveness.

Perhaps, one may consider an early pediatric neurological evaluation of such babies who are in the borderline criteria. If the neurological assessment is that of severe HIE then TH, even late, should be strongly considered.

Certainly, TH does not come without its risks such as sinus bradycardia, increased risk of sepsis and pneumonia, thrombocytopenia, or other coagulopathies. Additionally, other interventions such as central venous access are required. There may be shivering associated with hypothermia requiring increased sedation. Some other effects include delay in independent feeding and decreased early parental bonding critically needed for a vulnerable and fragile infant.<sup>24</sup> Therefore, the decision for hypothermia warrants a meticulous and thorough assessment.

The other issue that this case begs us to consider is how to weigh the value of cord blood pH versus a very abnormal MRI, a very suppressed EEG, and very profound hypotonia and worrisome neurological examination in the decision to cool or not to cool. Should the present criteria for cooling be revised to include these parameters as well? Certainly, this poses an interesting debate; however, when one takes into consideration the long-term sequelae such as cerebral palsy and its significant disability, then utmost circumspection is warranted in the assessment and management of these infants.

## Views of the Pediatric Neuroradiologist

Magnetic resonance imaging showed extensive areas of cortical restricted diffusion of the bilateral cerebral hemispheres, right thalamus, dorsal mesencephalon, and the territory of the left superior cerebellar artery, indicative of cytotoxic edema due to a global HIE. There were punctate areas of susceptibility artifact at the left caudothalamic groove and at the tip of the occipital horns of the lateral ventricles, indicating intraventricular hemorrhage.

## Views of the Director of the NICU

The hallmark study on TH has shown a reduction in the risk of death or disability in infants with moderate to severe encephalopathy.<sup>1</sup> Eligibility for hypothermia treatment includes physiological criteria and subsequent neurological examination.<sup>1</sup>

The review of this case presented a dilemma using TH as a treatment modality. The baby was not cooled based on the acute perinatal event being absent. I would like to highlight some key points in the baby's birth history. Limp at the time of delivery, NICU team being immediately called for help with resuscitation, Apgar 2, 3 and 5 at 1, 5, and 10 minutes of life, and arterial blood gas at 10 minutes of life showing a base deficit of 14.1 are suggestive of acute perinatal event. As a proponent of TH, I would question the validity of cord blood gases and the lack of acute perinatal events in this case.

The other interesting aspect of this case is inconsistency in the neurological examination. The documented physical findings include mild hypotonia, poor response to pain, and absent gag reflex. In my opinion, these findings would suggest moderate encephalopathy, but a complete neurological examination, as required for TH protocol, was not performed in this case. The baby presented with seizures at 9 hours of life requiring anticonvulsants and increased respiratory support. I strongly feel, given the birth history, initial blood gas, uncertainty regarding an acute perinatal event, and incomplete neurological exam, the baby should have been placed on TH protocol at this time. The effectiveness of hypothermia initiated in babies who are 6–24 hours old is suggestive but not conclusive. More importantly, no evidence of harm was found in the study.<sup>11</sup>

## Views of the Chair of the Department of Pediatrics

To improve the prediction of neonatal HIE, umbilical cord biomarkers may be helpful in the early identification of infants who will develop HIE, facilitating the decision to use interventions such as TH that are time-sensitive. For instance, umbilical cord lactic acid and alanine may predict the development of HIE, especially when combined with clinical symptoms.<sup>25</sup> Umbilical cord inflammatory makers may be predictable as well. Umbilical blood Interleukin-16 has been shown to be associated with poor neurodevelopmental outcomes in infants with HIE.<sup>26</sup> In the above-mentioned case, the



readily available umbilical cord HIE biomarkers might have helped the decision to initiate TH within the first 6 hours of life. Future studies are needed to identify early, readily available biomarkers to help identify infants at risk for developing HIE.

### Relevant Postnatal Course

The infant remained stable in room air and achieved independent oral feeding by two weeks of postnatal age. Laboratory tests including serum lactic acid, ammonia, carnitine, acylcarnitine, biotinidase, plasma and urine amino acid, urine organic acid, and genetic epilepsy panel were unremarkable. However, a repeat MRI on postnatal day 16 revealed the presence of evolving areas of cystic encephalomalacia involving both cerebral hemispheres, left more extensively than right, and the right thalamus, dorsal midbrain, left superior cerebellar hemisphere. After achieving adequate seizure control, both clinical and electrographic, the infant was discharged home on oral Phenobarbitone and Levetiracetam with close follow-up with a pediatric neurologist and NICU developmental clinic.

### Summary Statement

The chronology of the evolution of brain injury and the pattern of brain injury on MRI can indicate the severity and timing of HI insult in neonates.<sup>27–30</sup> In the current case, the presence of a very apparent diffusion abnormality on the diffusion-weighted image (DWI) MRI indicates the most probable *in utero* insult as the diffusion abnormalities are most often seen after 24 of injury, with the highest sensitivity at 48–72 hours post-injury.<sup>27,29</sup> Moreover, an early appearance of multicystic encephalomalacia features also indicates a probable occurrence of *in utero* hypoxic injury.<sup>30</sup> The brain injury pattern with predominant involvement of the cortical watershed region of the brain also indicated chronic partial HI insult.

Owing to the overlapping features and the existence of interobserver variabilities of clinical assessment of the severity of encephalopathy using the staging system developed by Sarnat and Sarnat, a clear distinction between mild and moderate encephalopathy is challenging to achieve.<sup>10</sup> Hence, if the standard biochemical criteria for TH are not met and if definitive features of moderate to severe encephalopathy are lacking, contrasting opinions and practice variations among providers are bound to happen. Moreover, in the absence of an obvious acute perinatal event, the timing of HI injury may remain uncertain. Often, despite being exposed to prolonged *in utero* partial hypoxia that can cause significant cortical injury, infants may initially present with mild encephalopathy features, as seen in the current case. Evidently, early biochemical, clinical, and physiological biomarkers with strong correlations with the severity and timing of the HI injury and higher predictive accuracy for long-term adverse neurodevelopmental outcomes may better identify at-risk infants and may be of utility in identifying infants for TH if the standard cooling criteria are not met. Furthermore, a multivariate risk prediction tool utilizing quantifiable early biomarkers may also be of immense help for early stratification useful.<sup>31</sup>

### AUTHOR CONTRIBUTIONS

Author SM conceptualized the study, drafted the initial manuscript, and reviewed and revised the manuscript; RB drafted the initial manuscript and reviewed and revised the manuscript; SA drafted the initial manuscript and reviewed and revised the manuscript; RR reviewed and revised the manuscript; NW reviewed the

manuscript; OAE reviewed the manuscript; MM reviewed the final draft. All authors approved the final manuscript as submitted and agree to be accountable for all aspects of the work.

### REFERENCES

- Shankaran S, Laptook AR, Ehrenkranz RA, et al. Whole-body hypothermia for neonates with hypoxic-ischemic encephalopathy. *N Engl J Med* 2005;353(15):1574–1584. DOI: 10.1056/NEJMcp050929.
- Bonifacio SL, Hutson S. The Term newborn: Evaluation for hypoxic-ischemic encephalopathy. *Clin Perinatol* 2021;48(3):681–695. DOI: 10.1016/j.clp.2021.05.014.
- Sarnat HB, Sarnat MS. Neonatal encephalopathy following fetal distress. A clinical and electroencephalographic study. *Arch Neurol* 1976;33(10):696–705. DOI: 10.1001/archneur.1976.00500100030012.
- Committee on Fetus and Newborn, Papile LA, Baley JE, et al. Hypothermia and neonatal encephalopathy. *Pediatrics* 2014; 133(6):1146–1150. DOI: 10.1542/peds.2014-0899.
- Armstrong L, Stenson BJ. Use of umbilical cord blood gas analysis in the assessment of the newborn. *Arch Dis Child Fetal Neonatal Ed* 2007;92(6):F430–F434. DOI: 10.1136/adc.2006.099846. DOI: 10.1136/adc.2006.099846.
- James LS, Weisbrot IM, Prince CE, et al. The acid-base status of human infants in relation to birth asphyxia and the onset of respiration. *J Pediatr* 1958;52(4):379–394. DOI: 10.1016/s0022-3476(58)80058-x.
- Shankaran S, Laptook A, Wright LL, et al. Whole-body hypothermia for neonatal encephalopathy: Animal observations as a basis for a randomized, controlled pilot study in term infants. *Pediatrics* 2002; 110:377–385. DOI: 10.1542/peds.110.2.377.
- Neilson DR Jr, Freeman RK, Mangan S. Signal ambiguity resulting in unexpected outcome with external fetal heart rate monitoring. *Am J Obstet Gynecol* 2008;198(6):717–724. DOI: 10.1016/j.ajog.2008.02.030.
- Peesay M. Nuchal cord and its implications. *Matern Health Neonatal Perinatol* 2017;3:28. DOI: 10.1186/s40748-017-0068-7. DOI: 10.1186/s40748-017-0068-7.
- Kumar V, Singla M, Thayyil S. Cooling in mild encephalopathy: Costs and perils of therapeutic creep. *Semin Fetal Neonatal Med* 2021;26(3):101244. DOI: 10.1016/j.siny.2021.101244. PMID: 33849797.
- Laptook AR, Shankaran S, Tyson JE, et al. Effect of therapeutic hypothermia initiated after 6 hours of age on death or disability among newborns with hypoxic-ischemic encephalopathy: A randomized clinical trial. *JAMA* 2017;318(16):1550–1560. DOI: 10.1001/jama.2017.14972.
- Gunn AJ, Parer JT, Mallard EC, et al. Cerebral histologic and electrocorticographic changes after asphyxia in fetal sheep. *Pediatr Res* 1992;31(5):486–491. DOI: 10.1203/00006450-199205000-00016.
- Ikeda T, Murata Y, Quilligan EJ, et al. Physiologic and histologic changes in near-term fetal lambs exposed to asphyxia by partial umbilical cord occlusion. *Am J Obstet Gynecol* 1998;178(1 Pt. 1):24–32. DOI: 10.1016/s0002-9378(98)70621-0.
- Russ JB, Simmons R, Glass HC. Neonatal encephalopathy: Beyond hypoxic-ischemic encephalopathy. *Neoreviews* 2021;22(3): e148–e162. DOI: 10.1542/neo.22-3-e148. PMID: 33649088.
- Meng S, Qiao M, Scobie K, et al. Evolution of magnetic resonance imaging changes associated with cerebral hypoxia-ischemia and a relatively selective white matter injury in neonatal rats. *Pediatr Res* 2006;59(4 Pt. 1):554–559. DOI: 10.1203/01.pdr.0000203099.40643.84.
- Gunn AJ, Bennet L. Fetal hypoxia insults and patterns of brain injury: insights from animal models. *Clin Perinatol* 2009;36(3): 579–593. DOI: 10.1016/j.clp.2009.06.007.
- Volpe JJ. Neonatal encephalopathy: An inadequate term for hypoxic-ischemic encephalopathy. *Ann Neurol* 2012;72(2):156–166. DOI: 10.1002/ana.23647.
- Executive summary: Neonatal encephalopathy and neurologic outcome, second edition. Report of the American College of Obstetricians and Gynecologists' Task Force on *Pediatr Res* 1992;31(5):486–491. DOI: 10.1203/00006450-199205000-00016.

19. Azzopardi D V, Strohm B, Edwards AD, et al. Moderate hypothermia to treat perinatal asphyxial encephalopathy [published correction appears in *N Engl J Med* 2010;362(11):1056. *N Engl J Med* 2009;361(14):1349–1358.
20. Gluckman PD, Wyatt JS, Azzopardi D, et al. Selective head cooling with mild systemic hypothermia after neonatal encephalopathy: Multicentre randomised trial. *Lancet* 2005;365(9460):663–670. DOI: 10.1016/S0140-6736(05)17946-X.
21. Azzopardi D V, Strohm B, Edwards AD, et al. Moderate hypothermia to treat perinatal asphyxial encephalopathy. *N Engl J Med* 2009; 361(14):1349–1358. DOI: 10.1056/NEJMoa0900854.
22. Simbruner G, Mittal RA, Rohlmann F, et al. Systemic hypothermia after neonatal encephalopathy: Outcomes of neo.nEURO.network RCT. *Pediatrics* 2010;126(4):e771–e778. DOI: 10.1542/peds.2009-2441.
23. Jia W, Lei X, Dong W, et al. Benefits of starting hypothermia treatment within 6 h vs. 6-12 h in newborns with moderate neonatal hypoxic-ischemic encephalopathy. *BMC Pediatr* 2018;18(1):50. DOI:10.1186/s12887-018-1013-2.
24. Jacobs SE, Morley CJ, Inder TE, et al. Whole-body hypothermia for term and near-term newborns with hypoxic-ischemic encephalopathy: A randomized controlled trial. *Arch Pediatr Adolesc Med* 2011;165(8):692–700. DOI: 10.1001/archpediatrics.2011.43.
25. O'Boyle DS, Dunn WB, O'Neill D, et al. Improvement in the prediction of neonatal hypoxic-ischemic encephalopathy with the integration of umbilical cord metabolites and current clinical makers. *J Pediatr* 2021;229:175–181.e1. DOI: 10.1016/j.jpeds.2020.09.065.
26. Ahearne CE, Chang RY, Walsh BH, et al. Cord blood IL-16 is associated with 3-year neurodevelopmental outcomes in perinatal asphyxia and hypoxic-ischaemic encephalopathy. *Dev Neurosci* 2017;39(1–4): 59–65. DOI: 10.1159/000471508.
27. Ghei SK, Zan E, Nathan JE, et al. MR imaging of hypoxic-ischemic injury in term neonates: Pearls and pitfalls. *Radiographics* 2014;34(4):1047–1061.
28. Bach AM, Fang AY, Bonifacio S, et al. Early magnetic resonance imaging predicts 30-month outcomes after therapeutic hypothermia for neonatal encephalopathy. *J Pediatr* 2021;238:94–101.e1. DOI: 10.1016/j.jpeds.2021.07.003.
29. Bednarek N, Mathur A, Inder T, et al. Impact of therapeutic hypothermia on MRI diffusion changes in neonatal encephalopathy. *Neurology*. 2012;78(18):1420–1427. DOI: 10.1212/WNL.0b013e318253d589.
30. Chacko A, Andronikou S, Mian A, et al. Cortical ischaemic patterns in term partial-prolonged hypoxic-ischaemic injury, the interarterial watershed demonstrated through atrophy, ulegyria and signal change on delayed MRI scans in children with cerebral palsy. *Insights Imaging* 2020;11(1):53. DOI: 10.1186/s13244-020-00857-8.
31. Ambalavanan N, Shankaran S, Laptook AR, et al. Early determination of prognosis in neonatal moderate or severe hypoxic-ischemic encephalopathy. *Pediatrics* 2021;147(6):e2020048678. DOI: 10.1542/peds.2020-048678.

